

# Follow-up after successful transluminal angioplasty

## Report of the initial Cleveland Clinic experience<sup>1</sup>

John C. Corbelli, M.D.  
Daniel F. Phillips, M.D.  
Richard J. Corbelli, M.D.  
William C. Sheldon, M.D.

One hundred forty-nine patients underwent percutaneous transluminal coronary angioplasty (PTCA) over a 24-month period. PTCA was successful in 106 patients (71%) and 109 vessels (72%). Patients with primary success were followed for  $9 \pm 0.6$  months (mean  $\pm$  SEM). Follow-up, ranging from five to 28 months, was based primarily on the evaluation of functional status according to the New York Heart Association Classification. Forty-eight patients underwent repeat coronary angiography during the course of follow-up. Seventy-five patients (71%) experienced continued improvement in functional class at the end of the follow-up period. Sixty-nine patients (65%) were in functional class I at the conclusion of follow-up; 5 of these patients had documented angiographic recurrence, and 12 patients showed no recurrence at repeat angiography. Thirty-one patients (29%) had recurrence of anginal symptoms; 19, 5, and 7 patients were in functional class II, III, and IV, respectively. Of these 31, 14 patients were shown to have no angiographic recurrence, and 13 patients demonstrated recurrent stenosis at repeat angiography. Recurrent symptoms in patients with angiographically documented restenosis of the previously dilated site occurred on an average of  $2.7 \pm 2.1$  months (mean  $\pm$  SD) post-PTCA. The authors' experience indicates that (a) long-term success is achievable in a substantial majority of PTCA candidates, (b) suspected recurrence must be documented angiographically, and (c) symptomatic recurrences are unusual beyond five months post-PTCA.

**Index terms:** Angiocardiography • Angioplasty, transluminal

**Cleve Clin Q** 51:591-600, Winter 1984

<sup>1</sup> Department of Cardiology, Section of Interventional Cardiology, The Cleveland Clinic Foundation. Submitted for publication Apr 1984; revision accepted Aug 1984. sb

0009-8787/84/04/0591/10/\$3.50/0

Copyright © 1984, The Cleveland Clinic Foundation

Percutaneous transluminal coronary angioplasty (PTCA) is a technique used to improve myocardial blood flow by

**Table 1.** Description of patients with primary success

No. of patients	106
No. of vessels dilated	109
Age (yrs)	
Mean	53
Range	33–76
Sex	
Male	90
Female	16
Duration of angina (months; mean $\pm$ SEM)	11 $\pm$ 2
No. $\leq$ 1 mo	31
No. $>$ 1 mo	68
Functional class	
Class I	7
Class II	57
Class III	15
Class IV	27
Coronary disease	
Single disease	71
Multivessel	35
Prior myocardial infarction	39
Prior bypass surgery	27
Left ventricular function	
Abnormality in region supplied by vessel for PTCA	40
Normal in region supplied by vessel for PTCA, but abnormal in other region	5
Normal	61
Cardiac risk factors	
Diabetes mellitus	10
Hypertension	45
Hypercholesterolemia	50
Family history of ASHD	57
Smoking history	65

PTCA = percutaneous transluminal coronary angioplasty, and ASHD = arteriosclerotic heart disease.

reducing the degree of localized atherosclerotic coronary stenosis. Early studies attempting to develop a suitable nonoperative method for relieving coronary atheromatous obstruction in human cadavers and dogs were performed by Ab-solon et al<sup>1</sup> and May<sup>2</sup> in the mid-1950s. In 1964, Dotter and Judkins<sup>3</sup> reported a technique involving the dilatation of arteriosclerotic obstructions in femoral arteries. Fourteen years later, Grüntzig<sup>4,5</sup> described the use of a balloon-tipped catheter designed to dilate stenotic femoral, pop-

liteal, and iliac arteries: a balloon-tipped catheter is placed across an arterial stenosis and inflated, thereby reducing the degree of obstruction. High patency rates in these vessels after two years led to the use of transluminal angioplasty in the coronary circulation.<sup>6–9</sup> Since 1978, this technique has gained increasing acceptance in the United States as an alternative to coronary artery bypass surgery for selected patients. A growing number of reports describe initial success with coronary angioplasty.<sup>10–17</sup> Our study describes the early clinical course after successful percutaneous transluminal coronary angioplasty.

### Material and methods

During the 24-month period from December 1980 through December 1982, 149 patients underwent PTCA. All patients were considered to be appropriate candidates for coronary artery bypass surgery, representing 3% of the total coronary artery bypass candidates at the Cleveland Clinic. Thirty-four right coronary arteries, 87 left anterior descending coronary arteries, 14 circumflex coronary arteries, and 17 saphenous vein grafts were involved. Two patients, who had not undergone coronary artery bypass surgery previously, had two native vessels dilated. One patient had two saphenous vein grafts dilated. One patient underwent a repeat angioplasty of the artery previously dilated, at which time a second coronary artery was dilated. Candidates in whom primary success was not achieved were subsequently excluded from further study.

Primary success, defined as a reduction in stenosis of 40% or greater and no coronary artery bypass surgery performed as a consequence of the PTCA procedure, was achieved in 106 patients (90 men and 16 women, ranging in age from 33 to 76 years [mean age, 53 years]). One hundred nine coronary arteries were dilated successfully. The duration of angina prior to PTCA ranged from one week to 11 years (11  $\pm$  2.0 [mean (mo)  $\pm$  SEM]). Angina was classified according to the New York State Heart Association criteria, with patients being divided as outlined (Table 1).

Correspondence or direct communication with each patient and with his or her local physician when indicated was done in every case. Follow-up included coronary artery bypass surgery or determination of death.

Informed consent was obtained in all cases. In the catheterization laboratory, transluminal cor-

onary angioplasty was attempted by either the femoral or brachial artery approach, similar to the techniques outlined by Grüntzig<sup>10</sup> and Stertzer et al.<sup>13</sup> Serial dilations were performed from three to 35 times ( $9 \pm 5.2$  [mean  $\pm$  SD]) with controlled pressures ranging from 1.4 to 12 atm. The number of inflations and pressures used in each case varied according to the degree of remaining transstenotic gradient and percentage of remaining stenosis. Only the nonsteerable USCI catheter system was used. Patients were monitored overnight and, in most cases, discharged the following day.

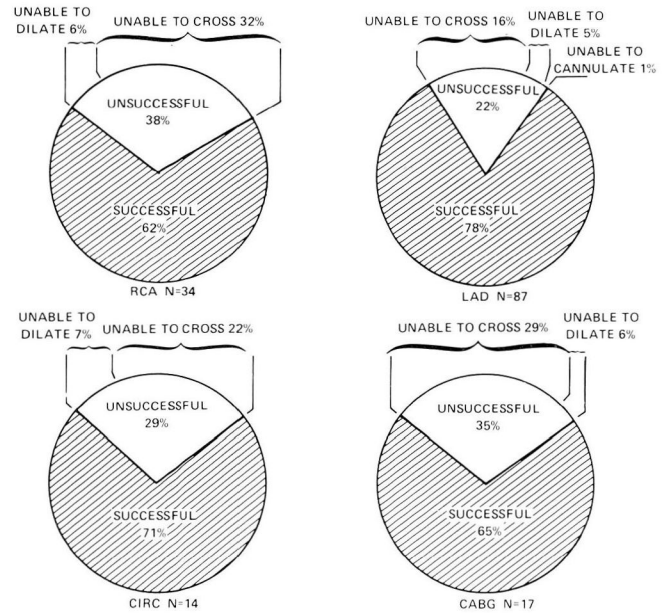
For 12 to 24 hours prior to PTCA, patients were medicated with dipyridamole and aspirin. Nitrates, beta blockers, and calcium antagonists were continued as indicated by clinical conditions. Immediately prior to the procedure, oral nifedipine and valium were given and dermal nitrates applied. After intraarterial insertion of the catheter, heparin (10,000 U) and nitroglycerin (200  $\mu$ g) were administered before advancing the catheter to the aortic arch. All successfully dilated patients were discharged on dipyridamole and aspirin. These medications were continued for at least three months after the procedure. All patients were recommended to undergo repeat coronary angiography six months post-PTCA.

Pressure gradients were obtained in the catheterization laboratory at the time of the procedure. Vessel stenosis was calculated in at least three projections with the individually obtained values averaged. The luminal diameter of the vessel at the narrowest portion of the stenosis was expressed as a percentage of the lumen diameter above and below the stenosis.

## Results

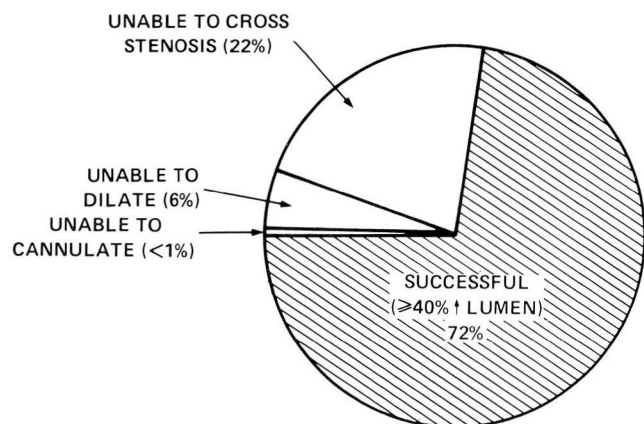
Primary success was achieved in 109 of 152 vessels (72%) and in 106 of 149 patients (71%). Breakdown according to vessel distribution indicated that 21 of 34 (62%) right coronary arteries, 67 of 87 (78%) left anterior descending coronary arteries, 10 of 14 (71%) circumflex arteries, and 11 of 17 (65%) saphenous vein grafts approached for PTCA were dilated successfully. Reasons for lack of primary success according to the individual vessel are summarized (Fig. 1). Overall, inability to cross a stenosis occurred in 22% and inability to dilate a stenosis occurred in 6% (Fig. 2).

At the end of the mean follow-up period of 9



**Fig. 1.** PTCA results according to the site of stenosis. "Successful" is defined as  $\geq 40\%$  increase in luminal diameter. CABG = coronary artery bypass graft, CIRC = circumflex coronary artery, LAD = left anterior descending coronary artery, and RCA = right coronary artery.

$\pm 0.6$  months (mean  $\pm$  SEM), 75 (71%) of the 106 patients continued to improve in functional class. Sixty-nine patients (65%) were in class I, 19 (18%) were in class II, 5 (5%) were in class III, and 6 (7%) were in class IV (Fig. 3).



**Fig. 2.** Angiographically successful cases (40% or greater increase in luminal diameter) are shown in the shaded area. Inability to cannulate the artery occurred in <1% of patients. Inability to alter a successfully crossed stenosis occurred in 6%. In 22% of the cases, the stenosis was unable to be crossed with the balloon.



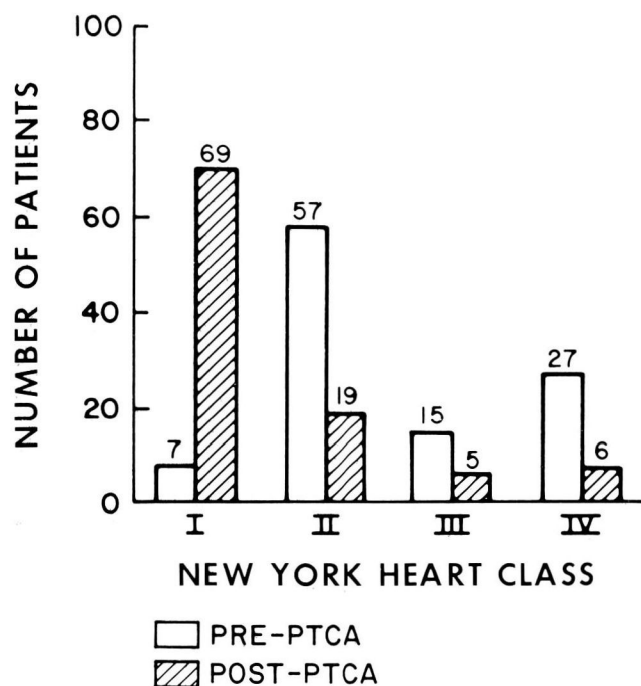


Fig. 3. New York State Heart Association Functional Classification before PTCA and at the end of follow-up (post-PTCA) in 106 successful cases.

Forty-eight patients (45%) underwent postangioplasty cardiac catheterization with recurrence, being defined as a stenosis of  $\geq 70\%$  at the site of the previous angioplasty. Twenty-seven patients with recurrent anginal symptoms, 17 asymptomatic patients, and 4 patients with post-PTCA myocardial infarction were restudied angiographically. Thirteen symptomatic patients showed definite recurrence of stenosis at the previously dilated site at time of restudy, whereas 14 patients had no recurrence. In the group with recurrent stenosis, symptoms recurred  $2.7 \pm 2.1$  months (mean  $\pm$  SD) post-PTCA. Seven symptomatic patients without recurrence demonstrated significant stenosis at a site other than the previously dilated site, with symptoms recurring  $5.8 \pm 5.8$  months (mean  $\pm$  SD) post-PTCA. Six of these patients subsequently had the second lesion dilated, and 1 underwent coronary artery bypass surgery (Fig. 4).

Five asymptomatic patients were found to have recurrent stenosis at repeat angiography, with 4 patients subsequently undergoing redilatation and 1 patient undergoing coronary artery bypass surgery. Twelve asymptomatic patients had no recurrence of stenosis (Fig. 4).

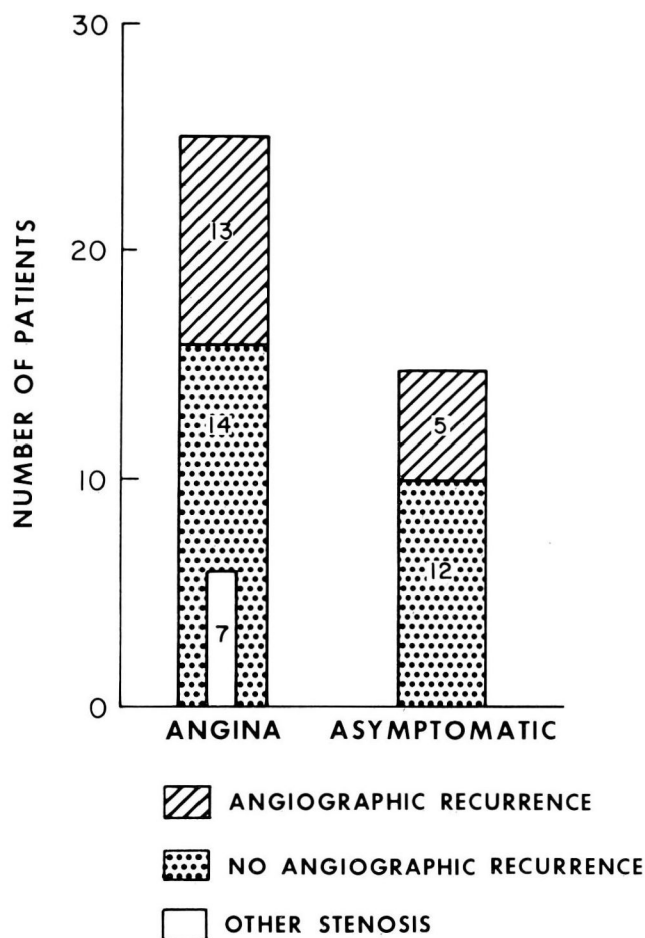


Fig. 4. Comparison of 44 patients who had angiography repeated during follow-up post-PTCA. Twenty-seven patients were experiencing recurrent anginal symptoms, while 17 patients were asymptomatic at the time of restudy. "Other stenosis" is a stenosis at a nondilated site.

Immediate post-PTCA stenosis and gradients were compared in relation to the development of early ( $\leq 2$  mo post-PTCA) and late ( $> 2$  mo post-PTCA) recurrent stenosis. These two time frames of recurrence showed no difference between these angiographic parameters. In addition, of the 14 patients showing evidence of immediate post-PTCA linear dissection, 1 patient experienced an early recurrence and 2 experienced late recurrences (Table 2). In the recurrence group (29%), 8% underwent repeat PTCA, 8% underwent coronary artery bypass surgery, and 5% experienced a myocardial infarction. Seven percent of the patients remained in the same functional class, with 1% moving to a lower class. Thus, symptomatic and angiographic data

**Table 2.** Comparison of early ( $\leq 2$  mo) and late ( $> 2$  mo) recurrence to residual stenosis, gradient (mean values), and presence of linear dissection immediately post-PTCA

	Early recurrence	Late recurrence
No. of patients	7	11
Stenosis (%)	34	31
Gradient (mm Hg)	12	11
Presence of dissection (No. of patients)	1	2

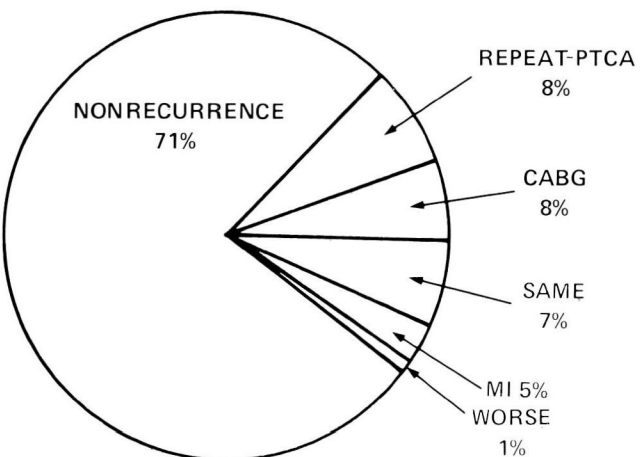
PTCA = percutaneous transluminal coronary angioplasty.

indicated 32 recurrences in 109 total vessels dilated (29%) in 106 patients followed up for  $9 \pm 0.6$  months (mean  $\pm$  SEM). The follow-up period ranged from five to 28 months (Fig. 5).

Seventy-one patients (67% of the total patients) had single vessel disease with 59 (83%) exhibiting improvement of functional class or continuance in their pre-PTCA functional class I status at the end of the follow-up period. Four patients (5%) had a myocardial infarction during the follow-up period, with angiographic evidence of occlusion at the dilated site. One death occurred in a patient undergoing antiarrhythmic therapy for documented ventricular tachycardia who had been in class I for five weeks post-PTCA and died while asleep. No postmortem examination was performed. A second patient died from noncardiac causes (Table 3).

Exclusive of patients who underwent angioplasty of saphenous vein grafts, there were 35 patients (24% of the total patients) who had multivessel coronary artery disease involving two or three coronary arteries. Seventeen patients (68%) exhibited improvement in functional class or continuance in their post-PTCA functional class I status at the end of the follow-up period. One patient died a noncoronary death, and one other patient experienced a myocardial infarction. One patient moved to class III without benefit of angiographic follow-up (Table 4).

There were 10 patients who underwent dilation of 11 saphenous vein grafts. Four patients were in functional class II prior to PTCA. Three of these patients were in class III, and 1 patient was in class IV at the end of their follow-up. There were 2 patients in class III prior to PTCA.



**Fig. 5.** Overall results of follow-up ( $9 \pm 0.6$  mo [mean  $\pm$  SEM]) in 106 patients with initially successful PTCA. Results combine angiographic and New York State Heart Association Functional Classification data. The data include one death. CABG = coronary artery bypass graft surgery, and MI = myocardial infarction.

One of these patients was in class I, and 1 patient was in class III at the end of the follow-up. There were 4 patients in class IV prior to PTCA. One of these patients was in class I at the time of his death due to other medical problems; 1 patient was in class II, and 2 patients were in class IV at the end of their follow-up. Four vessels were demonstrated angiographically to have no recurrent stenosis. There were four angiographically proved recurrences in this group, each of which were treated by coronary artery bypass surgery (Table 5).

The severity of stenoses in the vessels which were dilated ranged from 40% to 99% ( $82\% \pm 1.1$  [mean  $\pm$  SEM]) prior to dilatation. A high-grade stenosis (greater than or equal to 80%) was present in 76 (72%) of the patients. Postdilatation, percent stenosis of the dilated vessels ranged from 0% to 52% ( $24\% \pm 1.4$  [mean  $\pm$  SEM]). The mean reduction in stenosis was  $71\% \pm 1.7$  (SEM), with a range of 40% to 100%. Pre-PTCA gradients across the lesion ranged from 10 to 84 mm Hg ( $46 \pm 1.6$  [mean  $\pm$  SEM]). Post-PTCA gradients ranged from 0 to 44 mm Hg ( $9 \pm 0.8$  [mean  $\pm$  SEM]). The mean reduction in gradient was  $80\% \pm 1.7$  (SEM), with a range of 0% to 100% (Fig. 6).

A subgroup of 10 patients underwent pre-PTCA, immediate post-PTCA, and late ( $9 \pm 0.6$  mo [mean  $\pm$  SEM]) post-PTCA follow-up exercise testing. Pre-PTCA, immediate post-PTCA,

**Table 3.** Transluminal angioplasty of patients with single-vessel disease

	Pre-PTCA		Follow-up After Initial Success			
	Patients	Patients†	Angiographic Nonrecurrence	Angiographic Recurrence	Re-PTCA	CABS
Class I	5	4				
Class II						
Class III						
Class IV						
Class I		24	4	3	2	1
Class II	36	8	4	4	2	3
Class III						
Class IV		1		1	1	
Class I		6	1			
Class II		2	1	1		
Class III	10					1
Class IV						
Class I		17	2	1	1	
Class II		1	1			
Class III		1		1	1	
Class IV	20	1	1*			
TOTALS	71		14	11	7	5

† Includes four myocardial infarctions and two deaths.

\* Dilated other stenosis.

PTCA = percutaneous transluminal coronary angioplasty, and CABS = coronary artery bypass surgery.

**Table 4.** Transluminal angioplasty of patients with native coronary multivessel disease

	Pre-PTCA		Follow-Up After Initial Success			
	Patients	Patients†	Angiographic Nonrecurrence	Angiographic Recurrence	Re-PTCA	CABS
Class I	2	1				
Class II						
Class III		1		1		1
Class IV						
Class I		12	3*	1	1	
Class II	17	2	2*			
Class III		1				
Class IV						
Class I		1				
Class II						
Class III	2	1	1			
Class IV						
Class I		2	1			
Class II		1	1			
Class III						
Class IV	4	1		1*	1	
TOTALS	25		8	3	2	1

† Includes one myocardial infarction and one death.

\* Dilated other stenosis in one patient.

PTCA = percutaneous transluminal coronary angioplasty, and CABS = coronary artery bypass surgery.



**Table 5.** Transluminal angioplasty of saphenous vein grafts

	Pre-PTCA	Follow-Up After Initial Success			
	Patients	Patients†	Angiographic Nonrecurrence	Angiographic Recurrence	Re-PTCA CABS
Class I	0				
Class II					
Class III					
Class IV					
Class I					
Class II	4	3	2*	1	1
Class III					
Class IV		1	1		
Class I		1			
Class II					
Class III	2	1		1	1
Class IV					
Class I					
Class II		1	1		
Class III					
Class IV	4	2		2	2
TOTALS	10		4	4	0 4

† Includes one death.

\* Dilated other stenosis.

PTCA = percutaneous transluminal coronary angioplasty, and CABS = coronary artery bypass surgery.

and late follow-up exercise testing parameters were as follows, respectively: duration,  $6.6 \pm 0.8$ ,  $9.0 \pm 1.0$ ,  $9.4 \pm 2.0$  minutes (mean  $\pm$  SEM); metabolic equivalents,  $8.7 \pm 0.9$ ,  $11.6 \pm 1.0$ ,  $12.5 \pm 1.2$  (mean  $\pm$  SEM); ST segment depression,  $1.4 \pm 0.3$ ,  $0.6 \pm 0.3$ ,  $0.8 \pm 0.3$  mm (mean  $\pm$  SEM); double product (systolic blood pressure  $\times$  heart rate  $\times 10^3$ ),  $22.3 \pm 1.6$ ,  $25.1 \pm 1.5$ , and  $29.5 \pm 1.8$  (mean  $\pm$  SEM) (Fig. 7).

Complications occurred in 34 patients. Intimal dissection was noted in 14 patients. Eight patients experienced pain during the PTCA procedure; brief pain was experienced by 6 patients, and prolonged pain was experienced by 2 patients. Of the 2 patients who had prolonged chest pain during the procedure, the dilated vessel in 1 was totally occluded 30 minutes after initial dilatation. This patient subsequently had the vessel reopened with streptokinase, but after the procedure had electrocardiographic and enzyme changes compatible with myocardial damage. One other patient experienced myocardial infarction subsequent to the procedure. This patient had experienced brief episodes of pain during the PTCA procedure and demonstrated a

linear tear post-PTCA. Spasm was noted in 2 patients. A 90% stenosis developed in a previously normal diagonal branch of 1 patient after dilatation of the left coronary artery, which was believed to be due to spasm. The other patient was the same one noted previously who was given streptokinase and underwent redilatation post-PTCA. Five patients had bleeding from the arterial puncture site. One patient had a brachial artery thrombosis, and 1 patient experienced hypotension during the procedure. In addition, 1 patient with significant bilateral carotid artery stenosis had a cerebral vascular accident post-PTCA (Table 6).

## Discussion

Follow-up studies performed four to six years after dilatation of peripheral artery stenosis,<sup>5</sup> as well as a growing number of reports,<sup>9-17</sup> indicate that transluminal coronary angioplasty is effective in dilating stenotic coronary arteries and relieving the associated anginal symptoms in most patients. This report suggests that the extended outlook of a successfully dilated coronary artery stenosis is good, with 71% of our patients asymp-

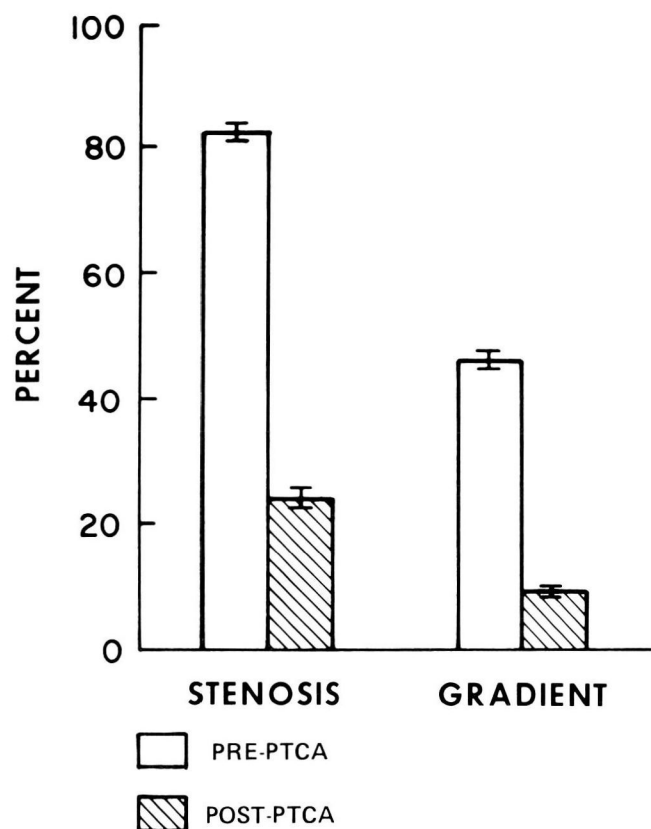


Fig. 6. Comparison of pre- and post-PTCA stenosis and gradients (mean  $\pm$  SEM).

tomatic or angiographically proved to have no recurrence during the course of our  $9 \pm 0.6$ -month (mean  $\pm$  SEM) follow-up period. Although four recurrences with angiographically proved total occlusion resulted in myocardial infarctions at two days and two, six, and seven months post-PTCA, the mean duration of time for angina to recur post-PTCA in 13 symptomatic patients with angiographically documented restenosis of a previously dilated vessel was  $2.7 \pm 2.1$  months (mean  $\pm$  SD). In 7 patients angiographically documented to have no recurrence at the dilated site but with a significant stenosis at a different site, symptoms recurred  $5.8 \pm 5.8$  months (mean  $\pm$  SD) after angioplasty. This indicates that the probability of recurrent symptoms from restenosis is unlikely once the patient is beyond the five-month period after angioplasty. This also suggests that recurrent symptoms after six months are more likely due to progressive disease in the native coronary arteries, rather than restenosis.

During the course of the follow-up, 27 patients with recurrent chest pain post-PTCA underwent

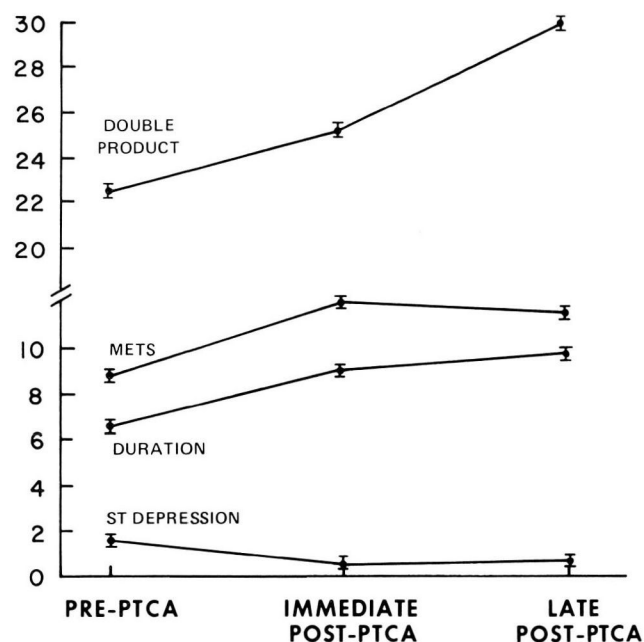


Fig. 7. Results (mean values  $\pm$  SEM) from a subgroup of 10 patients asymptomatic at follow-up, who underwent pre-PTCA, immediate post-PTCA, and late post-PTCA exercise testing. *DOUBLE PRODUCT* = systolic blood pressure  $\times$  heart rate, *DURATION* = min, and *METS* = metabolic equivalents. ST depression units are in millimeters.

repeat cardiac angiography. From this symptomatic group, 48% exhibited recurrent stenosis at the previously dilated site, and 26% had a significant stenosis at a nondilated site. The reason behind the recurrence of symptoms in the remaining 26% of the patients who did not exhibit significant coronary lesions is not precisely defined. It would appear that psychological factors play some role since 3 patients had relief of symptoms and 1 patient experienced decreased frequency of chest pain simply by gaining the knowledge that the coronary blood flow was not compromised. In the remaining 3 patients, the basis for continued symptomatology is speculative. Two patients had "atypical" chest pain (pain at rest or with activity) pre-PTCA with identical post-PTCA symptomatology suggestive of coronary artery spasm. The remaining patient experienced "typical" exertional chest pain pre-PTCA and post-PTCA. Ergonovine provocation tests were not performed. Seventeen asymptomatic patients underwent repeat coronary angiography. Five (29%) of these patients were found to have recurrent stenosis; all 5 patients had been experiencing chest pain pre-PTCA, with 3 of



these patients being in functional class II, 1 in class III, and 1 in class IV. This data indicate that symptomatic follow-up is unreliable in the post-PTCA patient and that repeat coronary angiography should be performed during the follow-up of all patients within the five- to six-month period after coronary angioplasty is performed.

In our study, coronary angioplasty exhibited a primary success rate of 71% of patients and 72% of vessels involved. All angioplasty attempts were performed prior to the availability of steerable systems. Reduction in mean percent stenosis was 82% to 24% (mean, 71%) (*Fig. 1*). Decrease in mean gradient across the stenosis was 46 to 9 mm Hg (mean, 80%) (*Fig. 2*). These results were similar to those reported by Grüntzig et al,<sup>10</sup> although the mean age (53 versus 49 years) and age range (33–76 versus 31–67 years) were somewhat greater with comparative percentages of patients with single vessel disease (67% versus 60%) and multivessel disease (31% versus 26%). The percentage of patients having saphenous vein grafts dilated with primary success was greater in our series (25% versus 6%); however, the percentage having evidence of recurrence was comparable (60% versus 67%).

Evidence of intimal dissection was evident angiographically in 14 of our patients. This results from splitting or fragmentation of the atheromatous plaque.<sup>18–22</sup> Some authors have concluded that intimal dissection with a degree of intimal flap is not a complication of the procedure but is, rather, necessary to achieve successful angioplasty.<sup>23</sup> Eventual retraction and remodeling along the fissure lines of intimal dissection may constitute a process leading to stabilization or even a greater resolution of the dilated arteriosclerotic plaque.<sup>20</sup> Isner and Fortin<sup>21</sup> have advanced evidence that “dissection clefts” and “plaque fractures” are not unique to the PTCA-treated vessel and are observable at necropsy in arteries where PTCA has not been performed. Of our 14 patients, 3 (21%) suffered a myocardial infarction during the course of follow-up. One infarction occurred at two months post-PTCA and another at seven months post-PTCA with angiographically proved total occlusion of the dilated site. A third patient died less than two months post-PTCA; necropsy revealed a thrombus in the coronary artery which had been dilated previously. He had previously been asymptomatic. One patient complained of chest pain during follow-up, but at repeat angiography, had a significant stenosis at another site, which was the

**Table 6.** Complications of PTCA

Dissection	14
Pain during PTCA	
Brief	6
Prolonged	2
Bleeding at femoral artery puncture site	5
Myocardial infarction	2
Coronary artery spasm	2
Arterial thrombus	1
Cerebrovascular accident	1
Hypotension	1
<b>TOTAL</b>	<b>34</b>

PTCA = percutaneous transluminal coronary angioplasty.

source of the angina. The remaining 11 patients remained in functional class I; 3 of these patients were demonstrated angiographically to have no recurrence.

Coronary artery spasm was evident in 2 patients (2%) with spasm recurring in 1 patient despite the intravenous administration of nitroglycerin and streptokinase and redilatation to relieve the initial spasm. This evidence of spasm is less than that reported by Cowley et al.<sup>24</sup> It may be related to the fact that calcium channel antagonists were not used as part of the adjunctive therapy regimen in that study. Thus, we would advocate the routine use of calcium channel antagonists as a prophylactic measure against coronary artery spasm in patients undergoing PTCA.

## Conclusion

PTCA continues to be a promising and increasingly popular approach for nonoperative therapy in certain patients with significant coronary artery disease. Our data indicate that long-term success is achievable in a substantial majority of PTCA candidates. Symptomatic recurrences are unlikely beyond five months post-PTCA and must be documented angiographically.

## Acknowledgments

We would like to thank George Williams, Ph.D., for his statistical analysis and Mrs. Earline Chisholm and Mrs. Kathy Shupe for their assistance in preparing this manuscript.

## References

1. Absolon KB, Aust JB, Varco RL, Lillehei CW. Surgical treatment of occlusive coronary artery disease by endarterectomy or anastomotic replacement. *Surg Gynecol Obstet* 1956; **103**:180-185.
2. May AM. Coronary endarterectomy: curettment of coronary arteries in dogs. *Am J Surg* 1957; **93**:969-973.
3. Dotter CT, Judkins MP. Transluminal treatment of arteriosclerotic obstruction: description of a new technic and a preliminary report of its application. *Circulation* 1964; **30**:654-670.
4. Grüntzig A. Die perkutane Rekanalisation chronischer arterieller Verschlüsse (Dotter-Prinzip) mit einem doppellumigen Dilatationskatheter. *Fortschr Röntgenstr* 1976; **124**:80-86.
5. Grüntzig A. Die perkutane transluminale Rekanalisation chronischer Arterienverschlüsse mit einer neuen Dilatationstechnik. Baden-Baden, W. Germany, G Witzstrock Verlag, 1977.
6. Grüntzig AR. Perkutane Dilatation von Coronarstenosen—Beschreibung eines neuen Kathetersystems. *Klin Wochenschr* 1976; **54**:543-545.
7. Grüntzig A, Riedhammer HH, Turina M, et al. Eine neue methode zur perkutanen Dilatation von Koronarstenosen—tierexperimentelle Prüfung. *Verh Dtsch Ges Kreislaufforsch* 1976; **42**:282-285.
8. Grüntzig AR, Myler RK, Hanna ES, Turina MI. Coronary transluminal angioplasty (abst). *Circulation* 1977; **56** (suppl 3):III-84.
9. Grüntzig A. Transluminal dilatation of coronary-artery stenosis (letter). *Lancet* 1978; **1**:263.
10. Grüntzig AR, Sennig Å, Siegenthaler WE. Nonoperative dilatation of coronary-artery stenosis: percutaneous transluminal coronary angioplasty. *N Engl J Med* 1979; **301**:61-68.
11. Grüntzig A, Myler R, Stertz S. Percutaneous transluminal coronary angioplasty (PTCA)—present state of the art (abst). *Circulation* 1979; **60** (suppl 2):II-264.
12. Kaltenbach M, Kober G. Transluminal angioplasty of coronary artery stenoses (abst). *Circulation* 1979; **60** (suppl 2):II-264.
13. Stertz SH, Myler RH, Bruno MS, Wallsh E. Transluminal coronary artery dilatation. *Practical Cardiol* 1979; **5**:25-32.
14. Levy RI, Mock MB, Willman VL, Frommer PL. Percutaneous transluminal coronary angioplasty. *N Engl J Med* 1979; **301**:101-103.
15. Cowley MJ, Vertrovec GW, Wolfgang TC. Efficacy of percutaneous transluminal coronary angioplasty: technique, patient selection, salutary results, limitations and complications. *Am Heart J* 1981; **101**:272-280.
16. Vliestra RE, Holmes DR Jr, Smith HC, Hartzler GO, Orszulak TA. Percutaneous transluminal coronary angioplasty: initial Mayo Clinic experience. *Mayo Clin Proc* 1981; **56**:287-293.
17. Kent KM, Bentivoglio LG, Block PC, et al. Percutaneous transluminal coronary angioplasty: report from the registry of the National Heart, Lung, and Blood Institute. *Am J Cardiol* 1982; **49**:2011-2020.
18. Freudenberg H, Wefing H, Lichtlen PR. Risks of transluminal coronary angioplasty: a postmortal study (abst). *Circulation* 1978; **58** (suppl 2):II-80.
19. Dorros G, Spring DA. Healing of coronary artery intimal dissection after percutaneous transluminal angioplasty (abst). *Am J Cardiol* 1980; **45**:423.
20. Block PC. Percutaneous transluminal coronary angioplasty. *AJR* 1980; **135**:955-959.
21. Isner JM, Fortin RV. Frequency in nonangioplasty patients of morphologic findings reported in coronary arteries treated with transluminal angioplasty. *Am J Cardiol* 1983; **51**:689-693.
22. Grüntzig A, Kumpe DA. Technique of percutaneous transluminal angioplasty with the Grüntzig balloon catheter. *AJR* 1979; **132**:547-552.
23. Block PC, Myler RK, Stertz S, Fallon JT. Morphology after transluminal angioplasty in human beings. *N Engl J Med* 1981; **305**:382-385.
24. Cowley MJ, Vetovec GW, Wolfgang TC. Efficacy of percutaneous transluminal angioplasty: technique, patient selection, salutary results, limitations and complications. *Am Heart J* 1981; **101**:272-280.

John C. Corbelli, M.D.  
 Department of Cardiology  
 The Cleveland Clinic Foundation  
 9500 Euclid Ave.  
 Cleveland OH 44106