

# Percutaneous balloon valvuloplasty for congenital pulmonary valve stenosis<sup>1</sup>

John C. Corbelli, M.D.  
Richard Sterba, M.D.  
Douglas S. Moodie, M.D.

**The authors describe the use and advantages of percutaneous balloon angioplasty to treat pulmonary valve stenosis.**

**Index terms:** Angioplasty, methods • Case reports • Pulmonary valve stenosis, congenital

**Cleve Clin Q** 51:541–544, Fall 1984

The success and increasing acceptance of the nonoperative transluminal balloon angioplasty technique as an alternative to peripheral vascular and coronary artery bypass surgery<sup>1–6</sup> have led to several reports describing application of the balloon dilatation principle to the management of pulmonic valve stenosis in pediatric and adult patients.<sup>7–11</sup> In this report, we describe the initial results of successful dilatation of a stenotic pulmonic valve in a pediatric patient.

## Case report

A 24-month-old white boy diagnosed as having congenital pulmonary valve stenosis came to The Cleveland Clinic Foundation for a second opinion. Local evaluation by a cardiologist had suggested that severe stenosis was present. Cardiac catheterization and open pulmonary valvulotomy were recommended by the referring physician.

On physical examination, the patient was a noncyanotic child with a normal respiratory rate. The blood pressure was 110/62 mm Hg, and the pulse rate was 112 beats/min and regular. He weighed 11.9 kg and stood 85 cm tall. The precordium was quiet, and the first heart sound was normal. A pulmonary ejection click was evident, and there was a grade III/VI long systolic ejection murmur heard best at the left upper sternal border. There was no diastolic murmur. An echocardiogram showed thickening of the pulmonic valve with the pulmonary valve cusp opening estimated at 10 mm. The electrocardiogram indicated severe right ventricular hypertrophy.

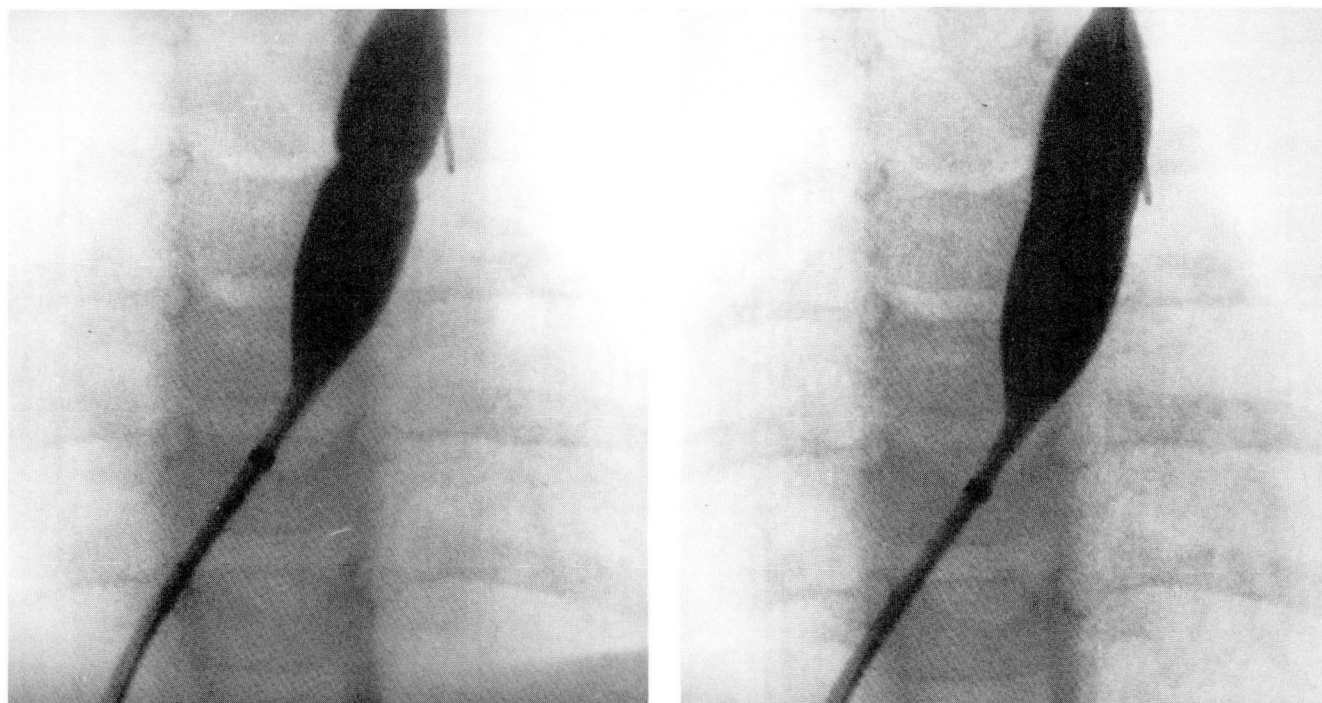
Initial cardiac catheterization revealed a pulmonary valve stenosis with a gradient across the valve of 75 mm Hg. At repeat catheterization for valvuloplasty, the gradient measured 90 mm Hg just prior to valve dilatation. The angiogram demonstrated the classic features of discrete pulmonary valve stenosis, with thickened leaflets which “domed” during systole and “inverted” during diastole. A central jet of contrast material appeared in the pulmonary artery with each systole. The cusps were noncalcified. Oxygen saturation data were obtained in the pulmonary artery prior to pullback and in both right heart chambers, which demonstrated no intracardiac shunt.

## Methods

A Lehman catheter was passed into the right ventricle and then directed out the left pulmonary artery. The exchange wire was positioned in the distal left pulmonary artery. Over the previously positioned guide wire, a 9-F Medi-Tech balloon (12mm diameter × 4-cm length) dilatation catheter was advanced through the stenotic pulmonary valve. The balloon size was selected on the basis of the diameter of the pulmonary valve as measured on a videotape monitor screen after videotaped angiography. The

<sup>1</sup>Department of Cardiology, The Cleveland Clinic Foundation. Submitted for publication Apr 1984; accepted June 1984. jw

A, B



**Fig. 1.** Left anterior oblique projection of the heart, with the dilatation balloon positioned across the pulmonary valve. The initial phase of inflation of the balloon with contrast material at a pressure of 40 psi is shown in **A**. The hourglass configuration of the contrast-media-filled balloon is created by indentation of the balloon by the stenotic valve. The balloon is at full inflation (50 psi) in **B**.

balloon was subsequently inflated with a mixture of half Renografin and half normal saline to a psi of 50 for 10 sec (*Fig. 1*). The patient was observed for two to three minutes, and then the procedure was repeated at 60 psi and again at 70 psi. The catheter was then removed over the guide wire, and a 7-F sheath and dilator were introduced into the femoral vein. Right heart pressures were remeasured, and right ventricular biplane cineangiography was performed. At the conclusion of the procedure, the arterial and venous lines were removed, and the patient was returned to his room in excellent condition and discharged the following day.

**Table.** Hemodynamic data

	RV Pressure	MPA Pressure	Gradient
Before valvuloplasty	102/12	12	90
After valvuloplasty	42/2-4	12	30

RV—Right ventricle.

MPA—Mean pulmonary artery.

All pressures in mm Hg.

## Results

After the procedure, the systolic ejection murmur decreased in intensity and was less harsh in quality. No murmur of pulmonic insufficiency was evident. Immediately before valvuloplasty, the gradient measured across the pulmonic valve was 90 mm Hg. The right ventricular pressure was 102/12 mm Hg, and mean pulmonary artery pressure was 12 mm Hg. After valvuloplasty, the transpulmonic gradient was reduced to 30 mm Hg, with the right ventricular pressure being 42/2-4 mm Hg and mean pulmonary artery pressure unchanged (*Table*).

An initial hourglass deformity was evident during inflation of the balloon, which gave way to fuller inflation of the balloon at 40 psi (*Fig. 1*) on the way to inflation to 50 psi. Subsequent inflations at 60 and 70 psi failed to demonstrate any deformity of the balloon. Comparison of cineangiograms obtained before and after pulmonary angioplasty demonstrated improved valve opening (*Fig. 2*).

## Discussion

Percutaneous transluminal balloon angioplasty

has been expanding in its therapeutic application in coronary and peripheral vascular diseases. Reports of the application of this technique in the treatment of pulmonary valve stenosis have been increasing.<sup>7-11</sup>

Although the surgical treatment of pulmonary valve stenosis is well established as an effective low-risk procedure, the balloon angioplasty procedure has significant advantages in terms of decreased patient morbidity and lower cost. Reports have demonstrated initial and early follow-up success in pediatric, adolescent, and adult patients.<sup>7-11</sup> A mild residual transpulmonic gradient is usually present after valvuloplasty, as was the case in our patient.

The mechanism by which balloon valvuloplasty relieves valve obstruction is not well defined. Lababidi and Wu<sup>7</sup> performed balloon valvuloplasty on one patient with tetralogy of Fallot, which was followed by total surgical repair the next day. At the time of surgery, a bicuspid pulmonary valve with a tear alongside the anterior valve raphe was evident, demonstrating that valve tissue can tear in this procedure. Walls et al<sup>11</sup> evaluated 5 patients after balloon pulmonary valvuloplasty who underwent subsequent open heart surgery for correction of complex cardiac anomalies. Visualization of the valve at surgery showed varied anatomic effects of the procedure, including commissural opening, leaflet tearing, and leaflet avulsion. The early experience with the Brock surgical procedure<sup>12</sup> demonstrated a good long-term result after manual opening of the stenotic pulmonic valve at surgery. Kan et al<sup>8</sup> suggest that in view of the surgical valvuloplasty experience, long-term results of balloon valvuloplasty should be good. Considerable experience with mitral valvulotomy by digital and transventricular instrumental techniques exists.<sup>13-17</sup> With awareness of the fact that mitral valve structural and flow characteristics differ from those of the pulmonic valve, the mechanics of valve alteration are similar to those of balloon pulmonary valvuloplasty. Perhaps this similarity may cause the long-term results of balloon pulmonary valvuloplasty to parallel the good results seen in mitral valvulotomy.

John C. Corbelli, M.D.  
Department of Cardiology  
The Cleveland Clinic Foundation  
9500 Euclid Ave.  
Cleveland OH 44106

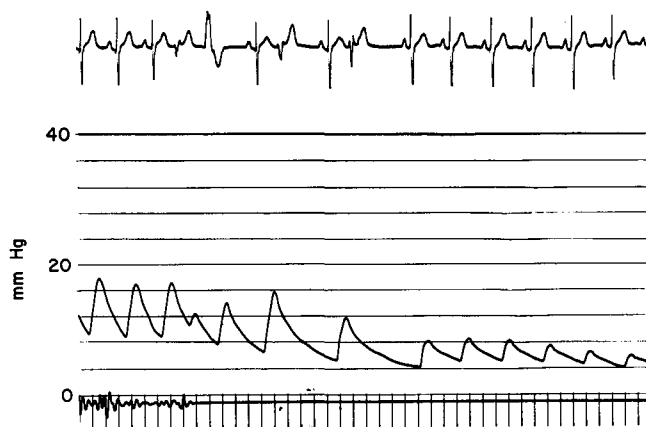

Fig. 2. Comparison of cineangiograms in the left anterior oblique projection before and after pulmonary valvuloplasty, demonstrating improved valve opening after the procedure.

## References

- Dotter CT, Judkins MP. Transluminal treatment of arteriosclerotic obstruction: description of a new technic and a preliminary report of its application. *Circulation* 1964;**30**:654-670.
- Zeitler E, Grüntzig AZ, Schoop W. Percutaneous vascular recanalization technique application, clinical results. Berlin, Springer-Verlag, 1978.
- Tegtmeyer CJ, Dyer R, Teates CD, et al. Percutaneous transluminal dilatation of the renal arteries: techniques and results. *Radiology* 1980;**135**:589-599.
- Grüntzig AR, Senning A, Siegenthaler WE. Nonoperative dilatation of coronary-artery stenosis: percutaneous transluminal coronary angioplasty. *N Engl J Med*. 1979;**301**:61-68.
- Spence RK, Freiman DB, Gatenby R, et al. Long-term results of transluminal angioplasty of the iliac and femoral arteries. *Arch Surg* 1981;**116**:1377-1386.
- Athanasoulis CA. Percutaneous transluminal angioplasty: general principles. *AJR* 1980;**135**:893-900.
- Lababidi Z, Wu J-R. Percutaneous balloon pulmonary valvuloplasty. *Am J Cardiol* 1983;**52**:560-562.
- Kan JS, White RI Jr, Mitchell SE, Anderson JH, Gardner TJ. Percutaneous transluminal balloon valvuloplasty for pulmonary valve stenosis. *Circulation* 1984;**69**:554-560.
- Pepine CJ, Gessner IH, Feldman RL. Percutaneous balloon valvuloplasty for pulmonic valve stenosis in the adult. *Am J Cardiol* 1982;**50**:1442-1445.
- Kan JS, White RI Jr, Mitchell SE, Gardner TJ. Percutaneous balloon valvuloplasty: a new method for treating congenital pulmonary-valve stenosis. *N Engl J Med* 1982;**307**:540-542.
- Walls J, Lababidi Z, Curtix J. Operative evaluation of percutaneous balloon pulmonary valvuloplasty. *J Am Cardiol* 1984;**53**:584-585.
- Blalock A, Kieffer RF Jr. Valvulotomy for relief of congenital valvular pulmonic stenosis with intact ventricular septum: report of 19 operations by Brock method. *Ann Surg* 1950;**132**:496-516.
- Baker C, Hancock WE. Deterioration after mitral valvulotomy. *Br Heart J* 1960;**22**:281-294.

14. Keith TA, Fowler NO, Helmsworth JA, Gralnick H. The course of surgically modified mitral stenosis: study of ninety-four patients with emphasis on the problem of restenosis. *Am J Med* 1963;**34**:308-319.
15. Lowther CP, Turner RW. Deterioration after mitral valvotomy. *Br Med J* 1962;**1**:1027-1036;1102-1107.
16. Ellis LB, Harken DE. Closed valvuloplasty for mitral stenosis. A twelve-year follow-up study of 1571 patients. *N Engl J Med* 1964;**270**:643-650.
17. Olinger GN, Rio FW, Maloney JV Jr. Closed valvulotomy for calcific mitral stenosis. *J Thorac Cardiovasc Surg* 1971;**62**:357-365.