

# Gynecomastia and Leydig cell tumors in the adult<sup>1</sup>

Steven W. Siegel, M.D.  
Anthony J. Thomas, Jr., M.D.

Two men with gynecomastia were evaluated at The Cleveland Clinic Foundation. Both were subsequently found to have a Leydig cell tumor of the left testis. One patient had previously undergone a testicular biopsy examination because of presumed infertility; the other had undergone the same type of examination due to a suspicious enlargement of the testicle. The results of these examinations had failed to reveal any evidence of a tumor. Endocrinologic manifestations of Leydig cell tumors are common and frequently present prior to the discovery of a testicular mass. These tumors are rare and usually benign. An orchiectomy is then curative and results in resolution of hormonal abnormalities in most cases. When malignant, Leydig cell tumors usually become evident by the presence of metastasis.

**Index terms:** Gynecomastia • Leydig cell tumor  
**Cleve Clin Q** 51:395-399, Summer, 1984

<sup>1</sup> Department of Urology, The Cleveland Clinic Foundation. Submitted for publication Jan 1984; accepted Feb 1984. jw

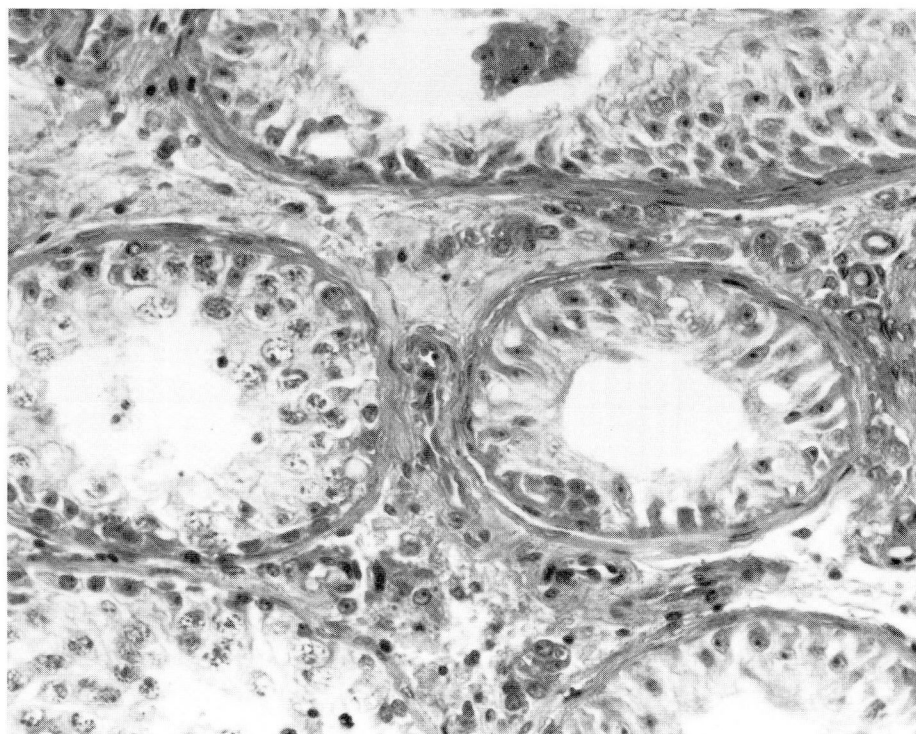
0009-8787/84/02/0395/05/\$2.25/0

Copyright © 1984, The Cleveland Clinic Foundation.

Gynecomastia can be a normal, physiologic event occurring in the peripubertal male. It may also be manifest in men with chromosomal abnormalities such as Klinefelter's syndrome. This hyperplasia is present in approximately 10% of men with germ-cell tumors of the testes.<sup>1-4</sup> Of these patients, gynecomastia is most prevalent in men with Leydig cell tumors.

## Case reports

**Case 1.** A 27-year-old man was seen at The Cleveland Clinic Foundation in 1963 because of bilateral gynecomastia of six months' duration. Libido or potency had not decreased. There was no history of drug use. Seven years earlier, he had undergone a bilateral testicular biopsy



**Fig. 1.** Case 1. Testicular biopsy specimen reveals germ cell aplasia, with a few tubules exhibiting some spermatogenesis (hematoxylin-eosin stain,  $\times 100$ ).

examination for primary infertility. His testes at that time were said to be small and soft, and gynecomastia was not mentioned. The testicular biopsy specimens had revealed a marked decrease in spermatogenesis (*Fig. 1*). At his evaluation in 1963, gynecomastia was prominent. Both testicles were small and of equal size, but the left was notably firmer than the right. No mass was discernible. The karyotype, intravenous urogram, and chest radiograph were normal. Because of the diffuse firmness of the testicle, a left orchiectomy was performed. The greatest length of the testis was 3.5 cm (*Fig. 2*). A well-demarcated tumor, within the tunica albuginea, was compressing the testicular parenchyma. A histologic section revealed sheets of well-differentiated eosinophilic cells compatible with a Leydig cell tumor (*Fig. 3*).

**Case 2.** A 29-year-old man was seen at The Cleveland Clinic Foundation in June 1983. He had a four-year history of intermittent left breast enlargement. In October 1982, he had noted enlargement of his left testicle. At that time, all laboratory studies had been normal, except for the follicle-stimulating hormone (FSH) level, which was low (*Table*). The intravenous urogram and chest radiograph were unremarkable. Despite no obvious evidence of a mass, the diffuse enlargement of the left testicle prompted a left inguinal exploration. Careful examination of the testis revealed no abnormality. Results of a biopsy examination revealed reduced spermatogenesis with germ-cell hypoplasia.

After surgery, his gynecomastia diminished, and the tes-

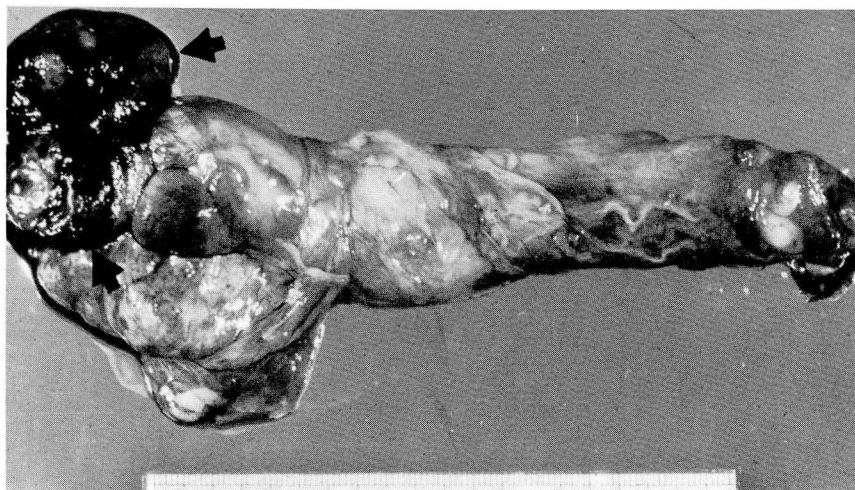
ticle decreased in size. Three months later, the opposite breast enlarged, and during the next two months, the left testicle again enlarged. At that time, he was seen in the Urology Department of The Cleveland Clinic Foundation. A physical examination revealed a healthy-appearing man with obvious right-sided gynecomastia. His left testicle measured  $6 \times 4 \times 3$  cm, at least 2 cm larger than his right testicle. The remainder of the physical examination was normal, and all other signs of masculinization were present. Laboratory test results are listed in the *Table*. The only hormonal abnormalities were an elevated serum estradiol level and a low value for the 17-ketosteroids. A chest radiograph, intravenous urogram, and computed-tomographic scan of the retroperitoneum and abdomen were normal.

An ultrasound examination of the testes demonstrated an "abnormal echotexture in the central portion of the left testicle." A left inguinal orchiectomy was then performed. The specimen revealed a firm, round nodule in the lower pole of the testis, measuring approximately 2.4 cm in diameter. The nodule was well demarcated by a thin, fibrous capsule, and at least 0.5 cm of testicular parenchyma was between the nodule and the tunica albuginea (*Fig. 4*). A histologic examination revealed a Leydig cell tumor similar to that of the other patient (case 1).

## Discussion

Leydig cell tumors are rare, comprising less than 3% of all testicular tumors.<sup>5</sup> More than 200 germ-cell neoplasms were seen at The Cleveland



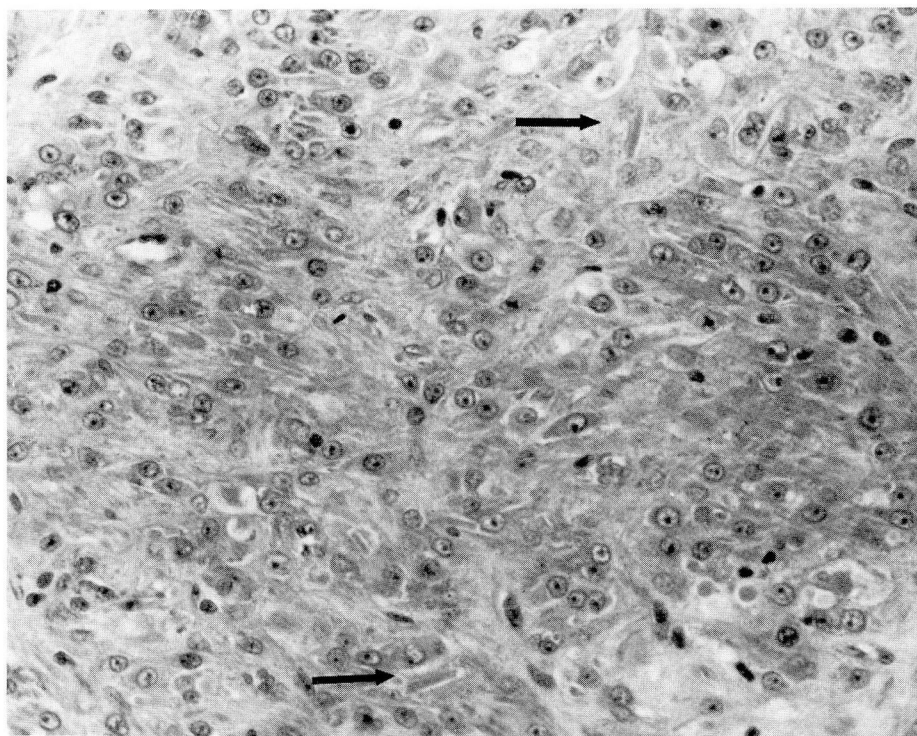


**Fig. 2.** Case 1. Left testicle and cord. Most of the testicle is replaced by the Leydig cell tumor (arrow).

Clinic Foundation during the last 20 years; the 2 patients reported here were the only adults with Leydig cell tumors. This neoplasm can occur at any age, but usually has a bimodal distribution in patients between the first and fourth decades of

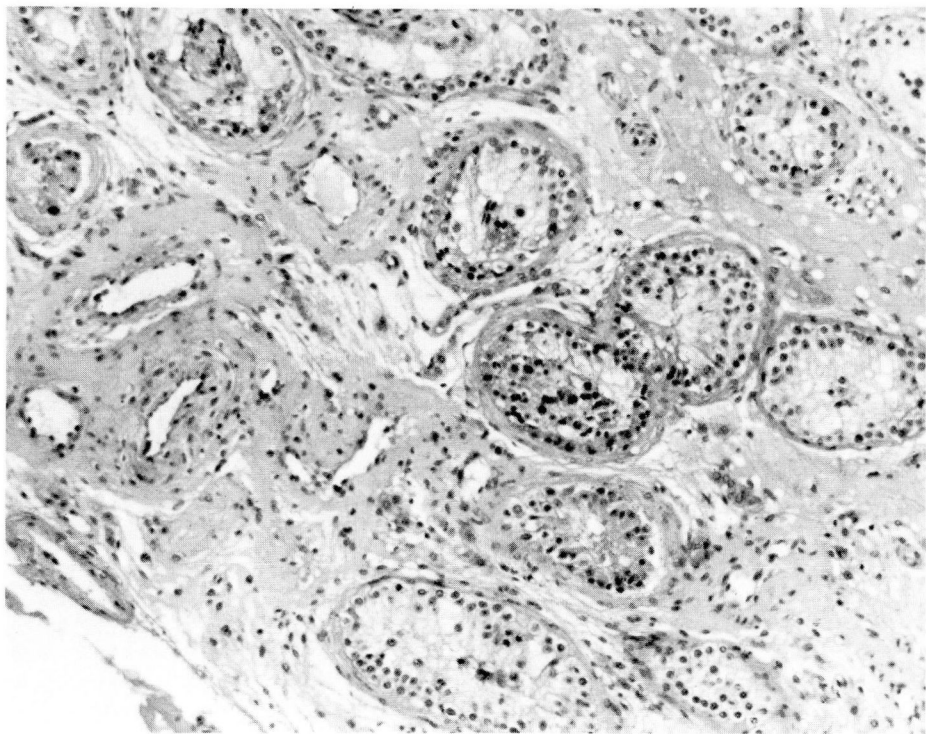
life. Approximately 10% of these tumors are malignant and have been reported in adults only.<sup>2,6</sup>

In the prepubertal male, these neoplasms often cause virilizing features such as macrogenito-



**Fig. 3.** Case 1. Sheets of well-differentiated eosinophilic cells are apparent. Note the Reinke's crystals (arrows), which are pathognomonic for Leydig cells (hematoxylin-eosin stain,  $\times 200$ ).





**Fig. 4.** Case 2. Photomicrograph of the testicular parenchyma surrounding the tumor. Diminished spermatogenesis is evident (hematoxylin-eosin stain,  $\times 100$ ).

somia, hirsutism, a deepening of the voice, and acne. Increased androgenic stimulation may result in premature closure of the epiphysis and marked muscle growth. Gabrilove et al<sup>2</sup> reported that prepubertal patients with Leydig cell tumors

may have increased breast size, which is generally masked by virilizing features.

Endocrinologic manifestations may or may not be evident in adults. At times, the hormonal dysfunction may be present months (Case 1) or

**Table.** Results of laboratory tests

Month/Year	Laboratory tests	Normal range	Patient
10/82	Testosterone	350–1200 ng/dl	560 ng/dl
	Prolactin	5–21 ng/dl	13.2 ng/dl
	Estradiol-17B		Reported as normal*
	B-subunit HCG		Reported as normal*
	$\alpha$ -fetoprotein		Reported as normal*
	Luteinizing hormone	5–39 IU/L	8.4 IU/L
6/83	FSH	2.5–16.0 IU/L	1.9 IU/L
	B-subunit HCG	<3.0 mIU/ml	<3.0 mIU/ml
	$\alpha$ -fetoprotein	1–10 ng/dl	1.56 ng/dl
	Estradiol-17B	10–60 pg/ml	95 pg/ml
	Dehydroepiandrosterone	0.8–6.2 $\mu$ g/ml	3.1 $\mu$ g/ml
	17-ketosteroids	9–22 mg/24 hr	6.1 mg/24 hr
7/83	17-hydroxycorticosteroids	4.5–12 mg/24 hr	5.6 mg/24 hr
	Estradiol-17B	10–60 pg/ml	29 pg/ml†

\* As reported by first surgeon

† Postoperative value

HCG = human chorionic gonadotropin, FSH = follicle-stimulating hormone.

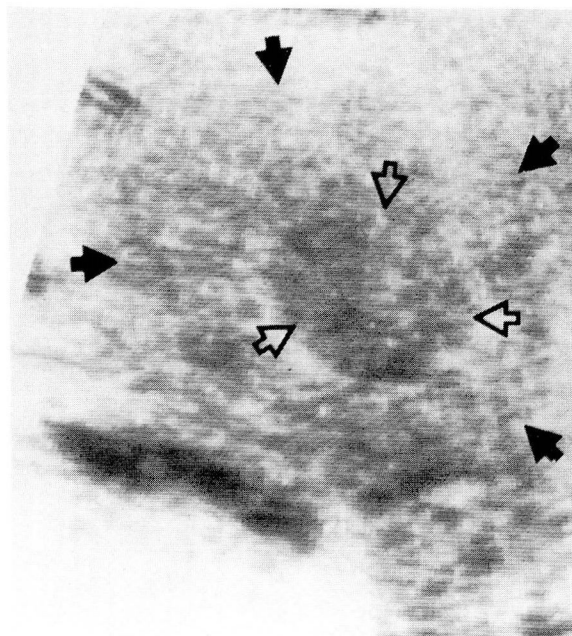
years (Case 2) before a tumor is clinically evident. Some of these tumors are quite small, measuring only 1–2 cm in diameter, thus making palpation difficult when they are located within the testicular parenchyma. Prudence dictates a careful examination of the testes when a man presents with signs of feminization or a boy presents with abnormal virilization. An ultrasound examination of the testes may demonstrate the tumor clearly (*Fig. 5*). If this examination fails to reveal the tumor and other causes such as an adrenogenital syndrome have been ruled out, transcutaneous spermatic vein catheterization and an analysis of blood from each testis may assist in localizing the site of abnormal hormonal production.

Histologically, differentiation of a benign from a malignant tumor is difficult, the only real proof of malignancy being evidence of metastatic disease. Gynecomastia has not been a presenting sign in patients whose tumors have proved to be malignant, but did occur after the primary tumor had been removed and metastatic disease had developed.<sup>1,2</sup>

Suspicion of malignancy may be heightened by the histologic examination of the primary tumor if many mitoses or extensive vascular and/or lymphatic invasion by the tumor cells is evident.<sup>7</sup> Metastatic disease may be found months or years after an orchiectomy has been performed. Thus, even though most men are not at risk, an indefinite follow-up period is indicated for all patients.

## References

1. Caldamone AA, Altebarmakian V, Frank IN, Linke CA. Leydig cell tumor of testis. *Urology* 1979;**14**:39–43.
2. Gabrilove JL, Nicolis GL, Mitty HA, Sohval AR. Feminizing interstitial cell tumor of the testis: personal observations and a review of the literature. *Cancer* 1975;**35**:1184–1202.
3. Gray SP, Chandler H, Bouskill KC, Blacklock NJ. Feminising interstitial cell tumour of the testis. *J R Nav Med Serv* 1973;**59**:71–76.
4. Distiller LA, Lissos I, Skudowitz RB. Gynecomastia due to Leydig cell tumour of the testis. *S Afr J Surg* 1981;**19**:173–176.
5. Mostofi FK, Price EB Jr. Tumors of the male genital system. [In] *Atlas of Tumor Pathology*. Series 2, fasc. 8. Washington, D.C., Armed Forces Institute of Pathology. 1973, pp 86–99.
6. Damjanov I, Katz SM, Jewett MAS. Leydig cell tumors of the testis. *Ann Clin Lab Sci* 1979;**9**:157–163.
7. Klippel KF, Jonas U, Hohenfellner R, Walther D. Interstitial cell tumor of testis: a delicate problem. *Urology* 1979;**14**:79–82.



**Fig. 5.** Case 2. Ultrasound examination of the left testis reveals a distinct echogenic mass within the normal testicular parenchyma. The open arrows define the border of the mass; the closed arrows mark the testicular border.