

Malignant intratubular and interstitial germ-cell neoplasia in bilaterally cryptorchid testes¹

Howard S. Levin, M.D.

A case of bilateral intratubular and interstitial malignant germ-cell neoplasia of the testes is reported in a 26-year-old man with bilateral cryptorchidism and Crohn's disease of the colon. Malignant intratubular and interstitial germ-cell neoplasia is a recently recognized entity associated with a contralateral testicular germ-cell tumor, infertility, and cryptorchidism. Although long-term data are not available, an orchiopexy performed early in the patient's life may protect against infertility or the development of a malignant tumor. The author advocates the orchiopexy of cryptorchid testes of patients, ideally in the second year of life, as well as biopsy of the testes of older, high-risk men to identify neoplasia at an early stage prior to the development of a more malignant germ-cell tumor.

Index terms: Cryptorchism • Germ cells • Testicular neoplasms

Cleve Clin Q 51:387-394, Summer 1984

¹ Department of Pathology, The Cleveland Clinic Foundation. Submitted for publication Jan 1984; accepted Feb 1984. jw

0009-8787/84/02/0387/08/\$3.00/0

Copyright © 1984, The Cleveland Clinic Foundation.

During his distinguished career at The Cleveland Clinic Foundation, Bruce H. Stewart, M.D., advocated and frequently employed testicular biopsy to evaluate testis function and the etiology of infertility. Pragmatic in everything he did, Dr. Stewart appreciated the value of excellent morphology as an aid to diagnosis and often requested frozen sections of testicular biopsy specimens from infertile men to diagnose and treat his patients expeditiously. He certainly would have endorsed testicular biopsy, as done in this case, to evaluate the testes of a man with bilateral

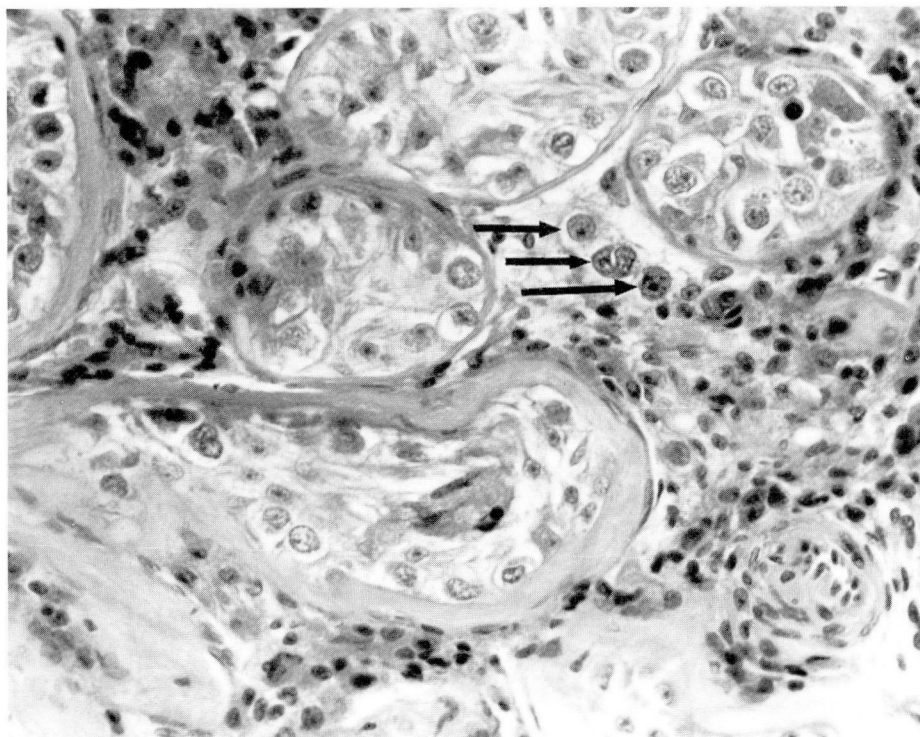


Fig. 1. Left testis biopsy specimen. Malignant germinal cells (arrows) are shown in the testicular interstitium. Seminiferous tubules are reduced in size. The lowest tubule shows marked tunica proprial thickening (hematoxylin-eosin stain, $\times 200$).

cryptorchidism. Recognition of intratubular and interstitial malignant germ-cell neoplasia led to quick optimal therapy. This communication describes an important function of testicular biopsy which should be performed routinely for patients at increased risk for a testicular malignancy.

Case report

Clinical findings: A 26-year-old man underwent a right orchiopexy for an undescended testis in the subcutaneous tissue at the right external inguinal ring. Simultaneously, he underwent right inguinal hernia repair. Six days later, a left orchiopexy and testicular biopsy for an ectopic left testis just above the left external inguinal ring between Scarpa's fascia and the external oblique muscle were performed. Malignant intratubular and interstitial germ cells in the biopsy specimen of the left testis prompted a left inguinal orchiectomy six days later. Malignant intratubular and interstitial germ cells were also identified in the orchiectomy specimen. After surgery, he underwent radiotherapy to the retroperitoneum. Three and one half months later, malignant intratubular and interstitial germ cells were identified in a biopsy specimen of the right testis. After another six weeks, a right radical orchiectomy was performed; recovery was uneventful. Microscopic sections of the testis revealed malignant intratubular and interstitial germ cells.

Ten years earlier, at age 16, the patient had had rectal bleeding, and at age 20, he was found to have Crohn's disease of the large intestine. Because of perianal involvement, he underwent a loop ileostomy. During treatment for Crohn's disease, his bilateral cryptorchidism was recognized.

(Incidentally, an older brother had had bilateral cryptorchidism treated with an orchiopexy when he was 12 years old.) A physical examination two years prior to the orchiectomy had revealed normal male development with a normal-size penis. He was able to have erections and ejaculate. Hair distribution was normal. At that time, results of buccal smears were negative for Barr bodies. A chromosome analysis revealed a 46 XY karyotype. Twenty-four hour urine specimens had normal amounts of 17-ketosteroids, 17-hydroxycorticoids, free cortisol, and pregnanetriol. The serum follicle-stimulating hormone (FSH) and luteinizing hormone (LH) levels were elevated at 46.8 and 36 mU/ml, respectively; the plasma testosterone value was 353 ng/100 ml.

The patient was alive and well five years and one month after the second orchiectomy.

Pathologic findings: The left testis biopsy specimen was a $0.8 \times 0.3 \times 0.1$ -cm, light-brown tissue segment fixed in zinc-substituted Zenker's solution. As shown by microscopic section, the seminiferous tubules were reduced in size. The tunica propria was thickened uniformly in all tubules. Many tubules were lined exclusively by Sertoli cells; however, significant numbers of tubules contained enlarged germinal cells resembling spermatogonia, but with slightly irregular nuclei. Nucleoli were present in some cells. Scattered intratubular cells contained eosinophilic granular material (hyaline droplet change). No cell with hyaline droplet change contained a nucleus having malignant characteristics; these were thought to be Sertoli cells. Postpubertal-type Leydig cells were present in approximately normal numbers within the interstitium. Also evident were scattered individual cells and clusters resembling the intratubular germ cells (Fig. 1). Some cells showed marked cytoplasmic clearing. Scattered

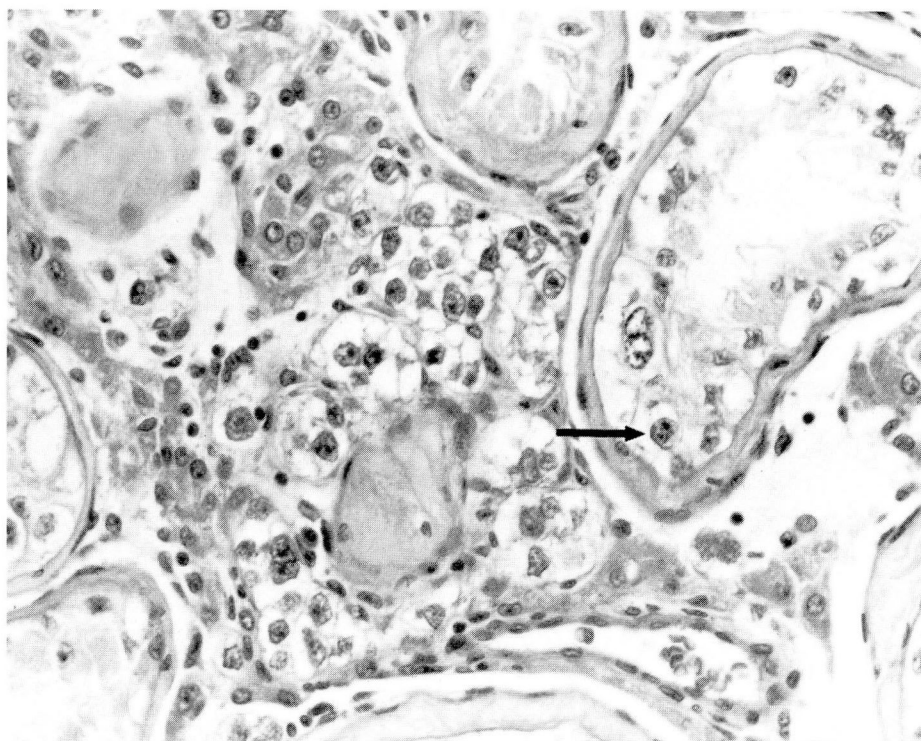


Fig. 2. Left orchietomy specimen. Malignant intratubular (arrow) and interstitial germinal cells. Neoplastic cells show nuclear irregularity, prominent nucleoli, and clear cytoplasm (hematoxylin-eosin stain, $\times 160$).

lymphocytes were present as well. Numerous Sertoli cells, as well as many intratubular and interstitial germinal cells, contained diastase-digestible material which, when tested, resulted in a positive periodic acid Schiff (PAS) reaction. Cells with hyaline droplet change contained PAS-positive, diastase-resistant material.

The left testis orchietomy specimen weighed 9 g and measured $3.2 \times 2.2 \times 1.5$ cm. A 0.6-cm incision indicated the site of previous biopsy. Palpation and bisection revealed normal testicular parenchyma without an obvious neoplasm. The entire specimen was fixed in zinc-substituted Zenker's solution. The spermatic cord and epididymis were normal. Histologic changes in the orchietomy specimen resembled those in the biopsy specimen with intratubular and interstitial malignant germinal cells (Figs. 2 and 3). These changes were present in every block, and in some, foci were much more evident than in the biopsy specimen. An inflammatory reaction with polymorphonuclear neutrophils (PMNs) and lymphocytes was present at the previous biopsy site. The neoplastic process extended to the edge of the rete testis without involving the rete testis epithelium. No organized seminomatous or nonseminomatous tumor was present. Occasional seminiferous tubules contained laminated calcific bodies; other calcific bodies were in tubules containing neoplastic germinal cells.

The right testis biopsy specimen measured $1.5 \times 0.4 \times 0.2$ cm and was fixed in zinc-substituted Zenker's solution. Microscopically, this specimen closely resembled the biopsy specimen from the opposite testis, although in this instance, only a few malignant interstitial germ cells were present (Fig. 4). Numerous malignant cells were present within the seminiferous tubules. The PAS reaction of the germinal and

Sertoli cells was positive. Areas of hyaline droplet change were also PAS positive and diastase resistant.

The right orchietomy specimen measured $3.5 \times 2.0 \times 2.0$ cm. The testicular parenchyma was a uniform tan-shaded brown and contained no demonstrable neoplasm. The entire specimen was sectioned and processed, but unfortunately, most of the testis was fixed in 10% formalin. The remainder of the testis was fixed in zinc-substituted Zenker's solution. Many sections contained malignant intratubular germ cells, but only a few were present in the interstitium. Hyaline droplet change was present in some seminiferous tubules (Fig. 5). Suture granulomas were present in the testis and peritesticular soft tissue at the site of the previous biopsy. No neoplasm was identified in the rete testis, epididymis, or spermatic cord.

Discussion

The patient underwent orchiopexies for bilateral cryptorchidism when he was 26 years old; by this time, both testes were atrophic and contained malignant intratubular and interstitial germinal cells. If germinal neoplasms of the testis originate in the seminiferous tubules, then these tumors were no longer in situ, but had invaded the testicular interstitium and were possibly capable of metastasizing. Radiotherapy given after the first orchietomy was predicated on a diagnosis of seminoma. Neoplasms beginning as intratubular malignant germ-cell neoplasia may

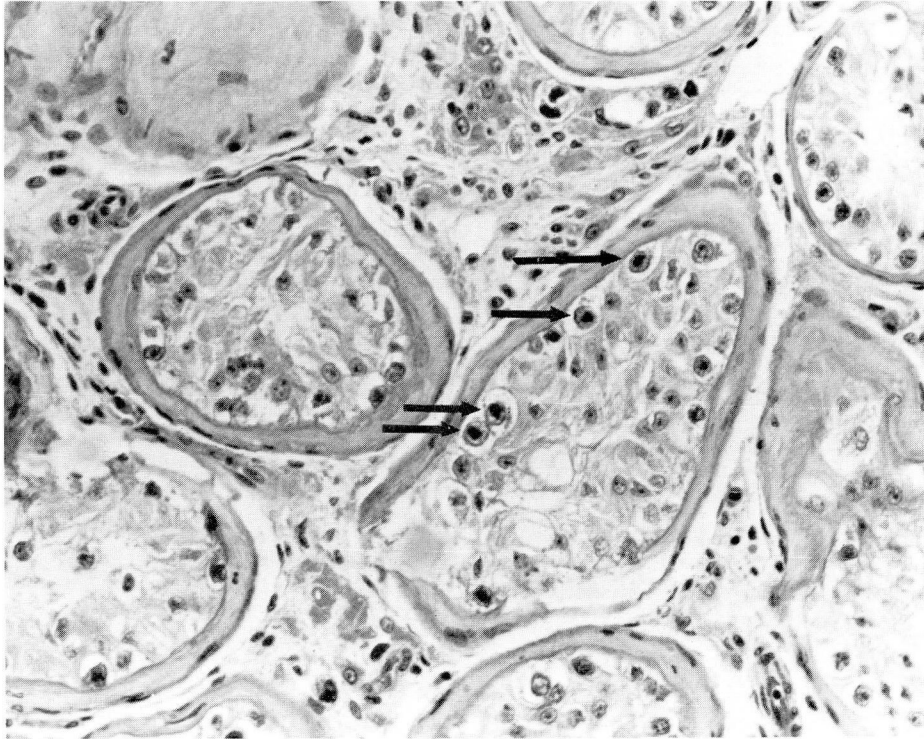


Fig. 3. Left orchiectomy specimen. Numerous malignant intratubular germinal cells (*arrows*) within a seminiferous tubule (hematoxylin-eosin stain, $\times 160$).

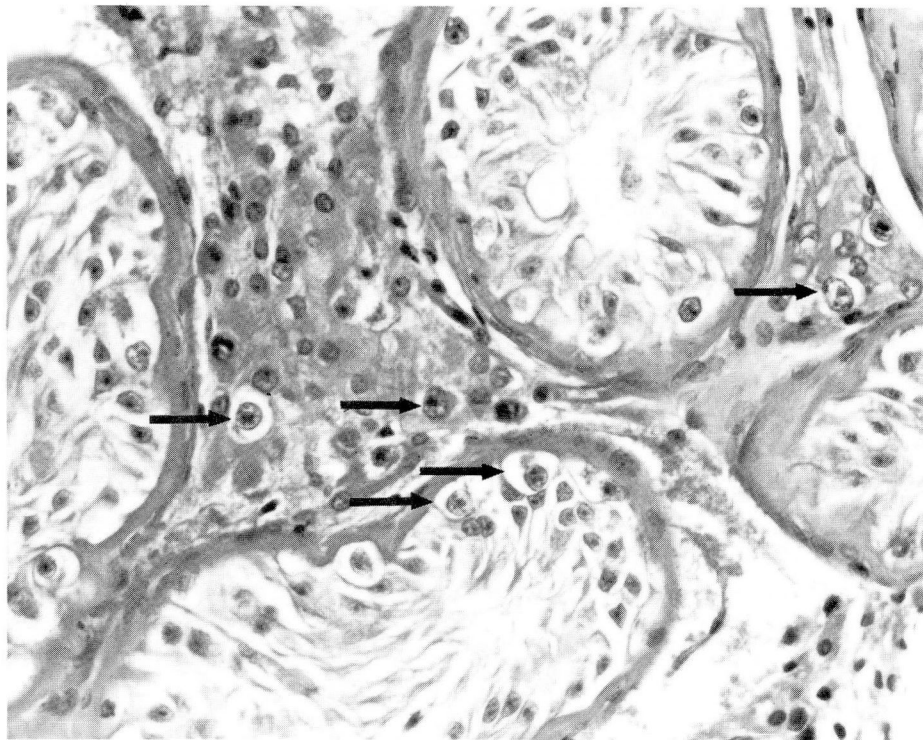


Fig. 4. Right testis biopsy specimen. Malignant intratubular and interstitial germ cells (*arrows*). The interstitial neoplastic germinal cells are nucleolated and found among smaller Leydig cells (hematoxylin-eosin stain, $\times 160$).

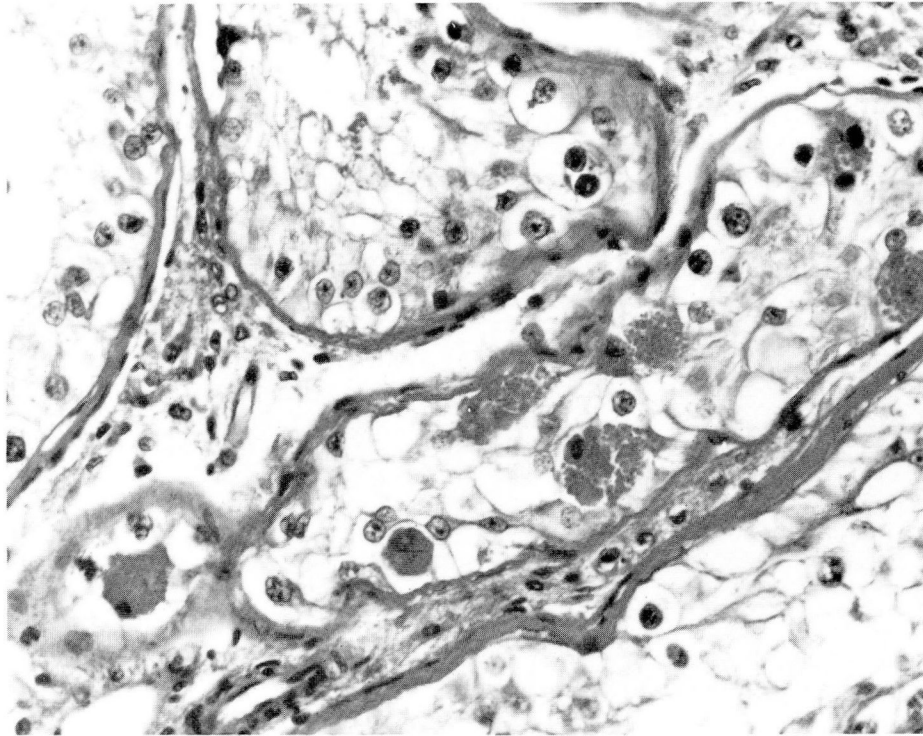


Fig. 5. Right orchiectomy specimen. Extensive hyaline droplet change in a seminiferous tubule is shown (hematoxylin-eosin stain, $\times 200$).

evolve into seminomas or nonseminomatous tumors.¹ In this case, a delayed orchiopexy guaranteed infertility. Although the patient had normal secondary sex characteristics, his serum testosterone level was in the low-normal range and the serum gonadotropin value was elevated. A postponed orchiopexy probably increased the likelihood that germinal neoplasms would develop.

Failure of the testicles to descend has long been associated with infertility. Morphologic study has identified histologic abnormalities in the seminiferous tubules of undescended testes by the second year of life.² Consequently, modern urologists have advocated surgical fixation of the testes performed early in the patient's life (early orchiopexy) to correct cryptorchidism, based on the likely assumption that progressive tubular damage will mean decreased spermatogenic function later in life. Nonetheless, little firm data exist dealing with the effect of an early orchiopexy on future fertility, since controlled studies of such operations with long follow-ups have not been carried out. In the patient reported here, it is not surprising that the testes were small since repair of cryptorchidism was not attempted until

he was 26 years old. Seminiferous tubules of reduced diameter were populated by numerous Sertoli cells, spermatogonia, and malignant intratubular germ cells. Spermatogenesis was not present beyond the spermatogonial level, and post-pubertal Leydig cells were prominent. Since the patient had normal secondary sex characteristics, was able to sustain an erection, and ejaculate, yet had a borderline, low serum level of testosterone and elevated serum gonadotropin values, the hormonal function of the testes was apparently adequate only with increased LH stimulation.

The risk of a germinal-cell neoplasm developing in a patient with an undescended testis or testes is well recognized and has been estimated as being at least 14 times that in a patient with normally descended testes.³ Most malignant tumors that develop in patients with unilateral undescended testes occur in the undescended gonad. A small percentage of malignant germinal-cell neoplasms will appear in the opposite descended testis, suggesting that a testicular abnormality may be present in both testes. Although a seminoma is the most frequent germinal-cell neoplasm in undescended testes, any type of malignant germinal-cell neoplasm may

develop. In the series, described by Martin,⁴ most testicular tumors in patients who had undergone orchiopexy were in men who had had the procedure performed after they were 13 years old. In another report,⁵ all cases of malignant germinal-cell tumor in patients with prior orchiopexy occurred in those whose orchiopexy had been performed when they were at least 11 years old. Only eight of 97 such instances documented by Martin⁴ occurred in patients who had had an orchiopexy when they were 10 years old or younger. In that series, the mean duration between the orchiopexy and orchiectomy for the malignant germinal-cell tumor was between 8.2 and 16.4 years, depending on the tumor's histologic type.

The etiology of undescended testes is frequently unclear. Insufficient gonadotropic stimulation, obstruction in the pathway of descent, and possibly, genetically determined testicular abnormality may be responsible. In the case described here, the cause is unknown. Results of the patient's karyotype, buccal smear, and phenotype were normal, and the androgen insensitivity syndrome was not clinically evident.

Malignant germinal cells have been identified in the lumen of seminiferous tubules in numerous circumstances. In 1978, Skakkebaek¹ reported a 1.1% incidence (6 patients) of intratubular germ-cell neoplasms among 555 patients who had undergone testicular biopsy for infertility. Two of the patients with intratubular germ-cell neoplasms had a cryptorchid condition. In 4 of the 6 patients, an invasive malignant tumor developed within 1.3 to 4.5 years. In 2 patients, the germ cells invaded the interstitium; in 1 patient, a seminoma was found, and in another, a teratoma with endodermal sinus tumor was discovered. Nüesch-Bachmann and Hedinger⁶ reviewed results of testicular biopsies obtained to evaluate fertility disturbance in 1,635 adults in a 26-year period. The biopsies were generally bilateral. Nine patients (0.55%) had "atypical spermatogonia." In 5 of these patients, malignant neoplasms (3 seminomas, 1 teratoma, and 1 mixed seminoma and teratoma) developed within months to six years. Krabbe et al⁷ obtained biopsy specimens from 50 testes which had been treated an average of 10 years earlier because they had not descended properly. Intratubular germ-cell neoplasia was found in four testes (8%); one also contained a seminoma, and one contained a nonseminomatous germ-cell tumor.

Skakkebaek⁸ found malignant intratubular

germ cells in an intraabdominal testis in a case of testicular feminization. In 1979, Berthelsen et al⁹ reported that the contralateral testis was examined by biopsy in 50 consecutive patients undergoing an orchiectomy for germinal neoplasia. The biopsy was performed either during the orchiectomy or in the interval between the orchiectomy and radiotherapy. Four patients (8%) had intratubular malignant germinal cells in the testis; 3 of the 4 had a seminoma in the orchiectomized testis, and the fourth had a nonseminomatous malignant germ-cell tumor. In 1 of the 4, interstitial malignant germ cells developed 46 months after the initial biopsy. Intratubular and interstitial germ cells have been reported in a cryptorchid testis by Dorman et al.¹⁰ Although it is well known that intratubular seminoma (seminoma in situ) occurs at the periphery of some seminomas and that intratubular spermatocytic seminoma generally occurs at the periphery of the main tumor mass, less well known is the fact that intratubular syncytial trophoblastic giant cells and embryonal carcinoma have also been reported. Thus, intratubular malignant germinal cells may occur without a palpable tumor and may precede the development of an invasive malignant germinal tumor—not necessarily a seminoma. While the neoplastic nonsyncytial trophoblastic giant cells and nonembryonal carcinoma cells are histologically identical to seminoma in situ, these cells may produce various germinal tumors, as noted by Skakkebaek.¹ Hence, in this case, the term "malignant intratubular germ cell neoplasia" is used, and when the neoplastic cells are present in the interstitium as well, the entity is termed "malignant intratubular and interstitial germ cell neoplasia."

The histology of the adjacent testis may vary, depending on cryptorchidism, infertility, or androgen insensitivity. In areas with malignant intratubular germ cells, the seminiferous tubules exhibit reduced diameters and thickened tunica propria.

Nielsen et al¹¹ described the neoplastic cells in malignant intratubular germ-cell neoplasia as having an increased diameter of 10 μ (compared with 6 μ for normal spermatogonia) and clear cytoplasm. Within the nuclei were several irregular chromatin clumps. Deoxyribonucleic acid (DNA) content exceeded that of diploid cells and almost equaled that of a tetraploid cell. Several mitoses were found in abnormal cells. Histologically identical cells were present in the interstitium.

The existence of malignant intratubular germ-cell neoplasia raises important questions concerning the histogenesis of tumors of germ-cell origin and suggests that, at least in some circumstances, an intratubular germinal cell may lead to the development of various types of germ-cell neoplasia and that perhaps the seminoma cell itself is multipotential in some instances.

The entity of malignant intratubular germ-cell neoplasia also raises questions regarding the diagnosis and management of patients at risk for germinal-cell tumors. Patients with cryptorchid testes, those with contralateral tumors, and infertile males are known to be at greater risk. All pubertal or postpubertal patients undergoing orchiopexy should also undergo a biopsy at that time. The biopsy specimen should be evaluated for neoplasia as well as for the degree of spermatogenesis. Intratubular neoplasia can occur at an early age; the patient reported by Dorman et al was only 13 years old.¹⁰ Although the incidence is low (probably 1%), pathologists should suspect intratubular neoplasia when reviewing testicular biopsy specimens for infertility. Early identification of such a patient may lead to the initiation of therapy before metastases are likely. The development of invasive tumors within a period of six years in 60% of the cases reported by Skakkebaek¹ and Nüesch-Bachmann and Heding⁶ suggests that patients such as these should have undergone orchiectomy following the establishment of a diagnosis. The risk of a contralateral malignant germ-cell tumor developing in a patient who has undergone or may presently undergo an orchiectomy for a malignant germ-cell tumor is debatable. Older data suggest that only 1% to 2% of patients will have *bilateral* testicular germ-cell tumors; these tumors may be present concurrently or sequentially. The recent study by Berthelsen et al⁹ that demonstrated 8% bilateral neoplasia should be repeated. Urologists are reluctant to obtain a biopsy specimen from the remaining testis of a young man who probably will have an infertility problem resulting from retroperitoneal lymph node dissection, radiotherapy, and/or chemotherapy. The argument has been made that if a patient with a metastatic germinal tumor has intratesticular malignant germ cells in the remaining testis, postsurgical chemotherapy should eradicate them. Fowler and Whitmore¹² described residual intratesticular seminoma in one case and intratesticular embryonal carcinoma and endodermal sinus tumor in a second case; both pa-

tients were treated extensively with chemotherapy for a disseminated tumor. In both cases, destruction of distant metastases was extensive, despite persistence of the primary testicular tumor. Thus, the testis may be a chemotherapy-resistant organ, perhaps in part because of the tight Sertoli cell junctions that determine the blood-testis barrier. Primary therapy of the testicular tumor may be necessary in a patient with extratesticular disease.

In every type of malignant disease, efforts are being made to establish an earlier diagnosis. Fine-needle aspiration, endoscopic techniques, tumor markers, and sophisticated radiologic procedures have been used to treat different organ systems. To wait until a tumor is palpable is to ensure that it has invaded the testicular interstitium. Invasion also enhances the risk of metastasis, particularly from nonseminomatous tumors. Recent studies have identified undescended testes, including those subjected to an orchiopexy in patients in the second decade of life; testes of infertile males; and the contralateral testis of patients with germinal-cell tumors of the testis as being at increased risk of developing malignancy. The intratubular origin of some or perhaps all germ-cell neoplasms suggests that biopsy is the best method of early and definitive diagnosis. In many instances, biopsy specimens may be taken during the orchiopexy or as part of the diagnostic evaluation of infertility. Urologists should carefully perform biopsies of these and other testes at increased risk, taking care not to compromise spermatogenic or hormonal function. Pathologists must take extreme care of testicular tissue, carefully fixing it in a non-formalin fixative, preferably Bouin's fluid.¹³ Other fixatives, such as Hollande's or Zenker's solution, also produce satisfactory results. As in the left orchiectomy specimen described in this case, a formalin artifact may complicate definitive evaluation such that the diagnosis may be overlooked. Formalin fixation hinders evaluation of testicular morphology in testis biopsy specimens obtained for evaluation of infertility and should be avoided.

References

1. Skakkebaek NE. Carcinoma in situ of the testis: frequency and relationship to invasive germ cell tumours in infertile men. *Histopathology* 1978; **2**:157-170.
2. Heding C. Histopathology of the cryptorchid testis. [In] Bierich JR, Giarola A, eds. *Cryptorchidism: Proceedings of the International Symposium on Cryptorchidism*. New York, Academic Press, 1979, pp 29-38.
3. Mostofi FK, Price EB. Tumors of the male genital system.

- [In] Atlas of Tumor Pathology. Series 2, fasc. 8. Washington, D.C., Armed Forces Institute of Pathology, 1973, p 8.
4. Martin DC. Germinal cell tumors of the testis after orchiopexy. *J Urol* 1979; **121**:422-424.
 5. Dow JA, Mostofi FK. Testicular tumors following orchiopexy. *South Med J* 1967; **60**:193-195.
 6. Nüesch-Bachmann IH, Hedinger C. Atypische spermatogonien als Präkanzerose. *Schweiz Med Wochenschr* 1977; **107**:795-801.
 7. Krabbe S, Berthelsen JG, Volsted P, et al. High incidence of undetected neoplasia in maldescended testes. *Lancet* 1979; **1**:999-1000.
 8. Skakkebaek NE. Carcinoma-in-situ of testis in testicular feminization syndrome. *Acta Pathol Microbiol Scand, Sect A* 1979; **87**:87-89.
 9. Berthelsen JG, Skakkebaek NE, Mogensen P, Sørensen BL. Incidence of carcinoma in situ of germ cells in contralateral testis of men with testicular tumours. *Brit Med J* 1979; **2**:363-364.
 10. Dorman S, Trainer TD, Lefke D, Leadbetter G. Incipient germ cell tumor in a cryptorchid testis. *Cancer* 1979; **44**:1357-1362.
 11. Nielsen H, Nielsen M, Skakkebaek NE. The fine structure of a possible carcinoma-in-situ in the seminiferous tubules in the testis of four infertile men. *Acta Pathol Microbiol Scand, Sect A* 1974; **82**:235-248.
 12. Fowler JE Jr, Whitmore WF Jr. Intratesticular germ cell tumors: observations on the effect of chemotherapy. *J Urol* 1981; **126**:412-414.
 13. Levin HS. Testicular biopsy in the study of male infertility. Its current usefulness, histologic techniques, and prospects for the future. *Human Pathol* 1979; **10**:569-584.