

Aneurysm of an aberrant right subclavian artery: repair using circulatory arrest¹

Richard G. Baillot, M.D.
Edwin G. Beven, M.D.
Delos M. Cosgrove, M.D.

An arteriosclerotic aneurysm of an aberrant right subclavian artery was repaired by median sternotomy with use of deep hypothermia and circulatory arrest. The procedure was combined with myocardial revascularization. All reported cases of aneurysmal dilatation of this vessel are reviewed, and the technical aspects of repair are described.

Index terms: Aneurysm, subclavian • Subclavian artery

Cleve Clin Q 51:173–175, Spring 1984

Although anomalous origin of the right subclavian artery is the most common aortic arch anomaly, aneurysms of this artery are rare. Described in 1735 by Hunauld,¹ this congenital malformation is usually asymptomatic, but in 1794, Bayford² reported dysphagia associated with this malformation. In 1899, Holzapfel³ stated that “dysphagia lusoria” could be expected only when an aneurysmal dilatation of the proximal part of the aberrant vessel exists. Kommerell⁴ described the roentgen characteristics in 1936, and in 1946, Gross and Ware⁵ were the first to sever the aberrant vessel through a left thoracotomy with good results.

With use of deep hypothermia and circulatory arrest, an aneurysm of an aberrant right subcla-

vian artery was repaired in conjunction with myocardial revascularization. The operative technique is reported and the literature reviewed.

Case Report

A 66-year-old white woman was admitted to the hospital for dysphagia. A chest radiograph showed a mediastinal mass compatible with a thoracic aneurysm. A barium study disclosed posterior compression of the thoracic esophagus and computed tomography (CT) demonstrated an aneurysmal dilatation 7 cm in diameter. Thoracic angiography confirmed the presence of an aneurysm of an aberrant right subclavian artery (*Fig. 1*). Coronary angiography demonstrated 50% stenosis of the left main trunk with 90% stenosis of the posterior descending coronary artery of the right system.

The right carotid and right subclavian arteries were exposed *via* a sternotomy incision extending into the right neck. Prior to initiation of cardiopulmonary bypass, the right subclavian artery was ligated and transected just distal to the aneurysm. Continuity was re-established *via* a Dacron graft anastomosed end-to-side to the right carotid artery and end-to-end to the right subclavian artery. Cardiopulmonary bypass was established *via* the right femoral artery and right atrium, and systemic cooling was begun. The aorta was clamped, crystalloid cardioplegia induced, and the saphenous veins anastomosed to the diagonal, circumflex, and distal right coronary arteries. The left anterior descending coronary artery could not be grafted. With circulatory arrest at 20°C, a longitudinal incision was made in the arch of the aorta and a Dacron patch sewn over the origin of the aneurysmal right subclavian artery (*Fig. 2*). The aorta was then closed; cardiopulmonary bypass was resumed and the proximal coronary anastomoses performed during rewarming. The patient recovered and was discharged without neurologic sequelae. A postoperative aortogram demonstrated obliteration of the aneurysm of the right subclavian artery, continuity of this right subclavian with the right

¹ Departments of Thoracic and Cardiovascular Surgery (R.G.B., D.M.C.), and Peripheral Vascular Disease (E.G.B.), The Cleveland Clinic Foundation. Submitted for publication July 1983; accepted Aug 1983.

1-3

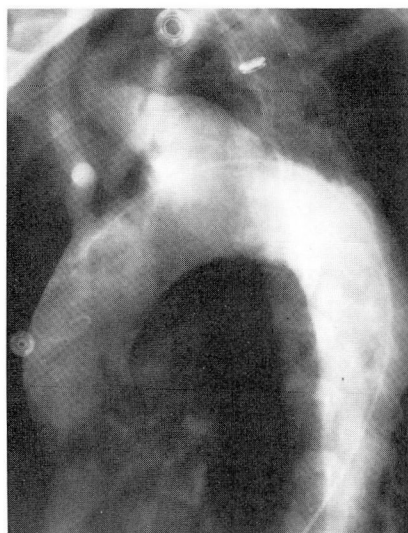


Fig. 1. Aortic arch angiography

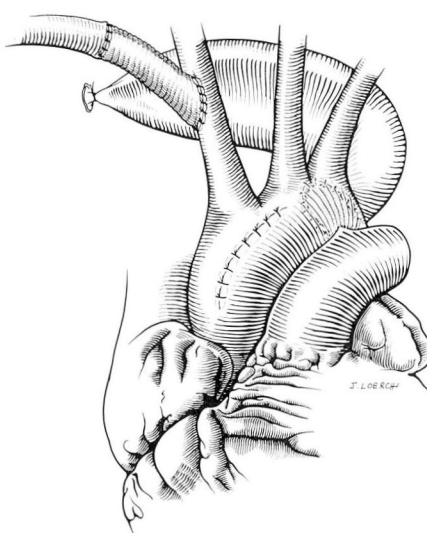


Fig. 2. Technical details of the procedure

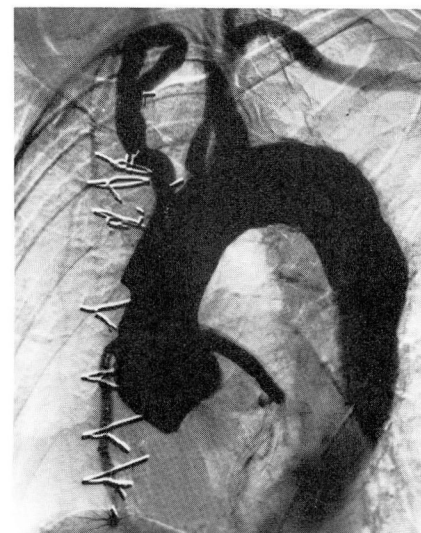


Fig. 3. Postoperative aortogram

Table. Review of the literature

No.	Author	Year	Sex/ Age	Surgery	Out- come
1.	McCallen ⁶	1955	M 50	Exploration	Died
2.	Richards ¹³	1957	M 70	...	Died
3.	Gomes ¹⁶	1968	M 60	Excision	Alive
4.	Campbell ¹⁹	1970	M 69	Excision	Alive
5.	Hunter ¹⁰	1970	M 55	Excision	Alive
6.	Hunter ¹⁰	1970	M 71	Excision	Died
7.	Hunter ¹⁰	1970	M 71	Excision	Alive
8.	Engelman ¹¹	1972	M 71
9.	Engelman ¹¹	1972	M 74	Excision	Died
10.	Sakurai ¹²	1973	F 40	Excision	Alive
11.	Sarot ⁹	1973	M 65	Excision	Alive
12.	Lui ¹⁴	1973	M 77	...	Alive
13.	Stoney ¹⁵	1975	M 63	Excision	Alive
14.	Reynes ⁷	1976	F 72	...	Died
15.	Rodgers ¹⁷	1977	F 11	Excision	Alive
16.	Cunningham ¹⁸	1977	M 56
17.	Schmidt ⁸	1980	M 67	Excision	Alive
18.	Cosgrove Baillot	1982	F 66	Obliteration	Alive

common carotid artery, and patency of the coronary artery bypasses (Fig. 3).

Discussion

Since the original report by McCallen and Schaff⁶ in 1956, 18 cases of aneurysmal dilatation of aberrant right subclavian artery have been reported, including this one (Table).⁶⁻¹⁸ There were 14 men (77.7%) and 4 women (22.2%) with a mean age of 61.5. Five patients in the series were asymptomatic whereas 8 (44%) had dysphagia; one aneurysm perforated into the esophagus, causing a fatal hemorrhage and another

patient had small emboli¹⁸ to the upper right arm as the mode of presentation.

Thirteen patients underwent surgery, 7 *via* a left thoracotomy. Three patients were approached by a right thoracotomy and 3 by sternotomies, including this case. In 2 patients, the procedure was done in conjunction with extracorporeal circulation and hypothermia. To our knowledge, ours is the first patient with obliteration of the aneurysm through the aortic arch under deep hypothermia and circulatory arrest and the first to undergo this procedure combined with myocardial revascularization.

This approach has several advantages. Ligation of the subclavian artery distal to the aneurysm prior to its manipulation prevents the embolization of atherosclerotic debris, while obliteration of the origin of the aneurysm from within the aorta during circulatory arrest avoids potential embolization distally.

Reconstruction of the distal right subclavian artery was done in 3 patients, but omitted in the other 10. One patient was reported to have fingertip necrosis which was successfully treated with cervical sympathetic blockade.⁹ Subclavian steal syndrome has not been reported although it has been a concern.

Avoidance of right arm ischemia can only be ensured by maintenance of vascular continuity. For this reason, graft reconstruction is preferable to simple ligation and is possible through the extended sternotomy approach.

Finally, through one incision, it is possible to maintain vascular continuity to the right arm, obliterate the aneurysm while avoiding the risk

of embolization, and perform myocardial revascularization if indicated.

Arteriosclerotic aneurysm of an aberrant right subclavian artery remains rare, appearing primarily in the older patient who may have associated coronary arteriosclerosis. Coronary angiography was performed to evaluate angina pectoris and should be considered in all older patients. Combined operation through a median sternotomy with deep hypothermia and circulatory arrest has provided a simple approach to this complex problem.

References

1. Hunauld P. Histoire de L'Academie Royale, 1735, p 20. [In] Richards WCD, Elliot CE. Aneurysm of an anomalous right subclavian artery. *Br Heart J* 1957; **19**:141-143.
2. Bayford D. An account of a singular case of obstructed deglutition. *Mem Med Soc London* 1794; **2**:271-282. [In] Drucker MH, Symbas PN. Right aortic arch with aberrant left subclavian artery symptomatic in adulthood. *Am J Surg* 1980; **139**:432-435.
3. Holzapfel G. Ungewöhnlicher Ursprung und Verlauf der Arteria subclavia dextra. *Anat Hefte (Wiesbaden)* 1899; **12**:369-521 [In] Richards WCD, Elliot CE. Aneurysm of an anomalous right subclavian artery. *Br Heart J* 1957; **19**:141-143.
4. Kommerell B. Verlagerung des Ösophagus durch eine abnorm verlaufende Arteria subclavia dextra (Arteria lusoria). *Röfo* 1936; **53**:590-595.
5. Gross RE, Ware PF. The surgical significance of aortic arch anomalies. *Surg Gynecol Obstet* 1946; **83**:435-448.
6. McCallen AM, Schaff B. Aneurysm of an anomalous right subclavian artery. *Radiology* 1956; **66**:561-563.
7. Reynes JB, Errasti CA, Ercoreca FJB, Landa AO. Aneurysm of aberrant right subclavian artery with esophageal perforation (letter). *Chest* 1976; **70**:105.
8. Schmidt FE, Hewitt RL, Flores AA Jr. Aneurysm of anomalous right subclavian artery. *Southern Med J* 1980; **73**:255-256.
9. Sarot IA (Discussion). [In] Engelman RM, Madayag M, Spencer FC. Aneurysm of aberrant right subclavian artery. *NY State J Med* 1973; **73**:290-292.
10. Hunter JA, Dye WS, Javid H, et al. Arteriosclerotic aneurysm of anomalous right subclavian artery. *J Thorac Cardiovasc Surg* 1970; **89**:754-758.
11. Engelman RM, Madayag M. Aberrant right subclavian artery aneurysm: a rare cause of a superior mediastinal tumor. *Chest* 1972; **62**:45-47.
12. Sakurai H, Lukban S, Litwak RS. Coarctation of aorta associated with anomalous right subclavian artery and its aneurysm. *NY State J Med* 1973; **73**:292-296.
13. Richards WC, Elliott CE. Aneurysm of an anomalous right subclavian artery. *Br Heart J* 1957; **19**:141-143.
14. Lui AHF. Aneurysm of anomalous right subclavian artery: report of a case. *Am Surg* 1973; **39**:187-190.
15. Stoney WS, Alford WC Jr, Burrus GR, Thomas CS Jr. Aberrant right subclavian artery aneurysm. *Ann Thorac Cardiovasc Surg* 1975; **19**:460-467.
16. Gomes MMR, Bernatz PE, Forth RJ. Arteriosclerotic aneurysm of an aberrant right subclavian artery. *Dis Chest* 1968; **54**:549-552.
17. Rodgers BM, Talbert JL, Hollenbeck JI. Aneurysm of anomalous subclavian artery: an unusual cause of dysphagia lusoria in childhood. *Ann Surg* 1978; **187**:158-160.
18. Cunningham GC. Radiologic case presentation. *Cardiovas Dis* 1977; **4**:4-6.
19. Campbell CF. Repair of an aneurysm of an aberrant retroesophageal right subclavian artery arising from Kommerell's diverticulum. *J Thorac Cardiovasc Surg* 1971; **62**:330-334.