

Aicardi's syndrome: report of an autopsied case and review of the literature¹

Gerald Erenberg, M.D.

The clinical and autopsy findings in a female infant with Aicardi's syndrome are presented. A clinical entity consisting of seizures, mental retardation, and chorioretinal lacunae, Aicardi's syndrome is found only in females and is associated with agenesis of the corpus callosum. Vertebral anomalies may also occur. Although the time of developmental arrest appears to be within the first trimester of pregnancy, the etiology of this disorder remains unknown.

Index terms: Aicardi's syndrome • Corpus callosum
Cleve Clin Q 50:341-345, Fall 1983

In 1965 Aicardi et al described a syndrome consisting of infantile spasms, mental retardation, and multiple ocular anomalies occurring in females with agenesis of the corpus callosum.¹ Vertebral and rib anomalies are often present, and the electroencephalographic (EEG) abnormalities include asynchrony between the two hemispheres. Approximately 100 cases of Aicardi's syndrome have now been reported,² although most have been in the non-English literature and few have been autopsied.³ The following case of Aicardi's syndrome was seen recently at The Cleveland Clinic Foundation. Diagnosis was made during life and confirmed at autopsy.

Case report

The patient was a 3770-g girl born at term on May 19, 1981, to a 29-year-old gravida I para 1 woman in good health. Delivery was by caesarean section because of pre-eclampsia manifested by maternal hypertension. Apgar scores were 9 at one and five minutes. Acrocyanosis and

fever developed at four days of age, and sepsis was suspected. All cultures were negative except for cerebrospinal fluid, which grew *Streptococcus viridans*. Although it was suspected that this represented a contaminant, intravenous antibiotic therapy was continued for 14 days. An initial DPT immunization was administered at eight weeks of age. The patient became febrile, and 24 hours later myoclonic seizures developed. She was hospitalized elsewhere, and her EEG showed rare left hemisphere spikes as well as hemisphere asymmetry. The computed tomography (CT) scan of the head was interpreted as indicating possible agenesis of the corpus callosum. TORCH titers were negative; blood and urine amino acid chromatography were normal.

The infantile myoclonic seizures did not respond to phenobarbital, and valproic acid was substituted. Frequent seizures continued and were unresponsive to combinations of adrenocorticotrophic hormone, diazepam, clonazepam, and ethosuximide. She was first seen at the Cleveland Clinic on January 26, 1982, at the age of eight months. The head circumference was below the third percentile, and the patient was markedly hypotonic with little spontaneous movement. Hyperreflexia and extensor toe responses were present bilaterally. She showed little awareness of her surroundings, exhibited no head control, and was unable to sit or support weight.

The patient's seizures did not respond to treatment with nitrazepam, carbamazepine, or phenytoin. Lethargy, feeding difficulties, and inadequate weight gain were ongoing problems. She was hospitalized in July and again in August 1982 in an attempt to improve her seizure control and to investigate methods of improving her nutritional state. Three EEGs performed during these hospitalizations showed bursts of multifocal sharp and slow waves occurring asynchronously in the right and left hemispheres (Fig. 1). The bursts alternated with episodes of suppression lasting two to three seconds. Sleep spindles and vertex sharp transients could be identified.

Cerebrospinal fluid was normal. A CT scan of the head showed agenesis of the corpus callosum and large subarachnoid spaces around the frontal lobes, consistent with hypoplasia (Fig. 2). Thoracic and lumbar spine roentgenograms were normal with no evidence of skeletal defects. Eye examination revealed a coloboma of the right disc with an area of chorioretinal atrophy surrounding it. The left retina

¹ Section on Child Neurology, Departments of Neurology and Pediatric and Adolescent Medicine, The Cleveland Clinic Foundation. Submitted for publication May 1983; accepted June 1983.

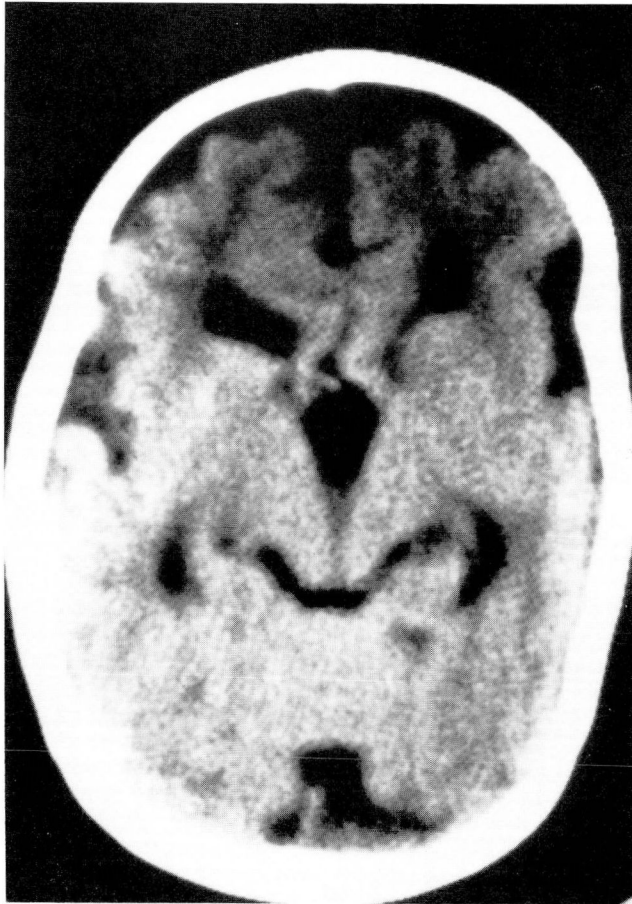


Fig. 1. Computed tomography scan showing agenesis of the corpus callosum. There is also marked enlargement of the subarachnoid spaces surrounding the frontal lobes.

showed large areas of chorioretinal atrophy with a spotty, peppery type of pigmentation. The atrophic areas were yellowish, consistent with absence of retinal pigment epithelium rather than with inflammatory destruction.

When she was last seen on September 20, 1982, myoclonic seizures had continued to occur daily, and no developmental progress had been made. Microcephaly, lethargy, hypotonia, and hyperreflexia were again noted.

At 17 months of age she was found pale and unresponsive in bed. Resuscitative attempts were unsuccessful.

Autopsy findings

The autopsy was performed at University Hospitals of Cleveland. Multiple sections through both lungs showed a diffuse suppurative exudate filling the bronchioles and alveoli, amidst remnants of vegetable matter and skeletal muscle fibers. Numerous gram-positive cocci were identified and thought to be indicative of aspiration pneumonia. The brain was remarkable for polymicrogyria in the frontal lobes involving both supraorbital and parietal surfaces, and demonstrated microscopically by abortive sulci and

thinning of the cerebral cortex. There was partial agenesis of the corpus callosum with preservation of the anterior portion (*Fig. 3*). The lateral ventricles were displaced laterally and stretched vertically. The cingulate gyrus was absent. Heterotopia was seen in the frontal horn on the left. An additional abnormality was the complete disorganization of the layers in the lateral geniculate body. Permission to examine the eyes was refused.

Discussion

The *Table* lists the clinical and anatomic abnormalities that characterize Aicardi's syndrome. Several features universally present in all case reports and reviews³⁻⁷ are female sex, seizures, mental retardation, ocular anomalies, and partial or complete agenesis of the corpus callosum. Other abnormalities occur in varying percentages in patients with this syndrome. Most patients die within the first decade of life.

Sex of patient: Except for one report,⁸ only females have been reported to have Aicardi's syndrome. The validity of the single case report of a male has been questioned on the basis of whether the ocular findings are truly those seen in Aicardi's syndrome.² It has been postulated that this syndrome is caused by a single dominant gene mutation on the X chromosome.⁴ The gene possibly arises as a mutation either in the maternal oocyte or paternal X-carrying sperm, and the condition is lethal in the male fetus.

Family history: There have been no reports of Aicardi's syndrome occurring in more than one member of a family. The absence of a familial pattern has important implications for family counseling since there is no increased risk of the condition recurring in affected families.

Seizures: All patients have presented for medical attention because of seizures. Seizures begin within the first few months of life. Combinations of generalized tonic-clonic seizures and infantile myoclonic seizures have been universal and are usually resistant to treatment with antiepileptic drugs. The types of seizures are not diagnostic, but Aicardi's syndrome should be considered in a female infant with infantile myoclonic seizures of unknown etiology.

Mental retardation: Severe mental retardation with delayed psychomotor development has been present in all reported cases. This retardation is accompanied by marked hypotonia.

Ocular anomalies: The ocular manifestations may be varied, but chorioretinal lacunae are

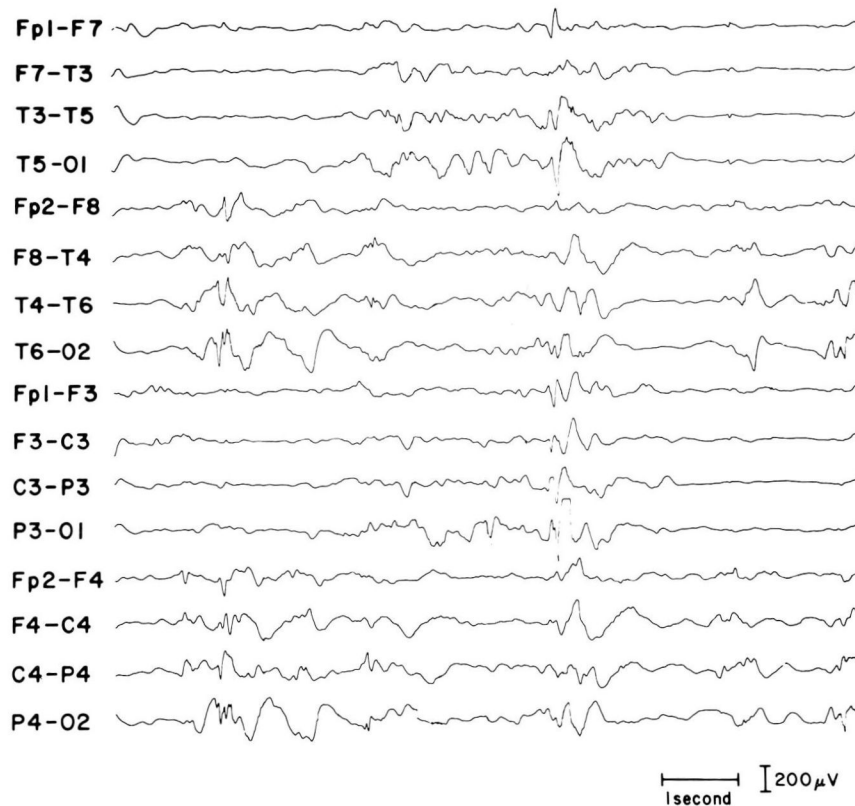


Fig. 2. Bursts of multifocal sharp and slow waves occurring asynchronously in the right and left hemispheres. These alternate with episodes of suppression.

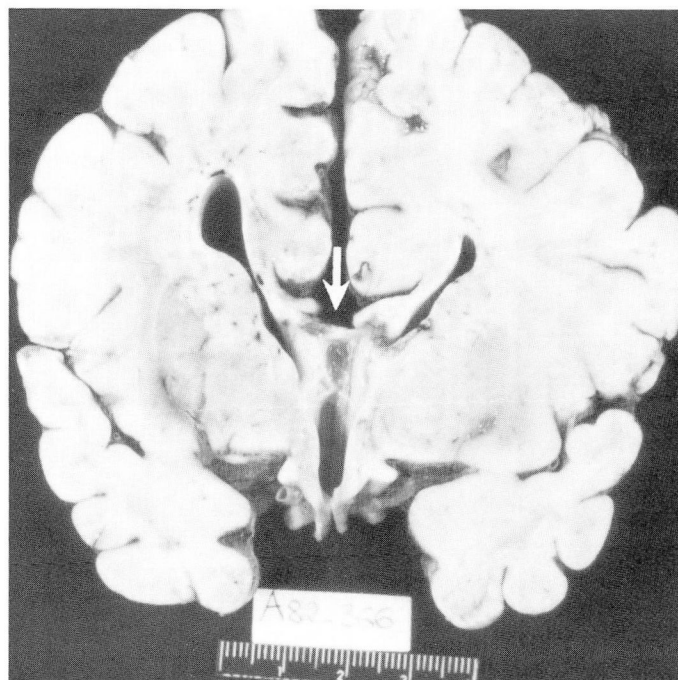


Fig. 3. Absence of the corpus callosum (*arrow*). The gross specimen is approximately the same level as shown on the CT scan in *Figure 2*.

Table. Findings in Aicardi's syndrome

Females only
Lack of family history
Seizures of early onset
Mental retardation
Chorioretinal lacunae
Vertebral anomalies
Agenesis of the corpus callosum
Cortical heterotopias
Hypsarrhythmic pattern on EEG
Asynchronous burst suppression on EEG

thought to be characteristic, if not pathognomonic, of this disorder.⁹ The lacunae vary in size, have various amounts of pigment around their borders, are multiple in number, and usually occur bilaterally. The alterations appear to be in the retinal pigment epithelium and the underlying choroid. The retina itself is normal, and the electroretinogram has been normal or minimally altered in the few cases in which it has been recorded. Less common anomalies include colobomas of the choroid and optic nerve, gliosis of the optic disc, persistent pupillary membrane, and microphthalmia.

Skeletal abnormalities: Although a frequent feature of Aicardi's syndrome, bony anomalies are not universally present. Abnormalities of the vertebral bodies are the most common and include hemivertebrae, fused vertebrae, variations in vertebral size, and spina bifida. Hand, finger, and costovertebral anomalies have also been reported, but there are no reports of long-bone abnormalities.

Radiographic studies: Total or partial agenesis of the corpus callosum is seen in all cases. This anomaly was initially diagnosed by pneumoencephalography, but the CT scan has established this finding in more recent cases.¹⁰ Intracranial calcifications are not seen, but there have been case reports of Aicardi's syndrome in association with choroid plexus papillomas.¹¹ All autopsy cases have demonstrated cortical heterotopias as well, but heterotopias are often not diagnosable by radiographic studies.

Electroencephalographic findings: The combination of EEG findings seen in patients with Aicardi's syndrome is suggestive of the diagnosis, but there is no pathognomonic pattern.⁵ The most frequent features include a hypsarrhythmic pattern manifested by widespread spikes of irregular rates and by high voltage slow waves replacing the normal background. The background is also characterized by a burst-suppression pattern

with burst and suppression portions of approximately equal duration. The most striking feature, when present, is a variable degree of asynchrony between the activity of the two hemispheres. In its most dramatic form, brain wave activity is completely asynchronous with the burst-suppression pattern shifting randomly between the two hemispheres. Normal sleep characteristics with spindles and vertex transients may be present or absent.

Laboratory studies: No studies other than EEGs or neuroimaging have been of value in diagnosing Aicardi's syndrome.⁷ With rare exception, cerebrospinal fluid studies have been normal. No abnormalities have been found in routine blood or urine studies. Generalized aminoaciduria has been reported occasionally, but is of doubtful significance. Many unsuccessful attempts have been made to implicate an intrauterine infection.¹² Multiple negative studies for infectious agents have been directed against toxoplasmosis, cytomegalovirus, herpes, rubella, and syphilis. Results of all chromosomal studies reported have also been normal.

Etiology: The events leading to Aicardi's syndrome are unknown. The developmental arrest leading to this syndrome is probably between the fourth and twelfth week of gestation. The commissural plate is formed from the fourth to seventh week, and the corpus callosum results from intussusception of this plate during the third month of fetal life. The retinal pigment, the choroidal pigment, and the sclerotomes that form the vertebral bodies all arise between the fourth and fifth week. No toxic agent or teratogenic drug has been found to cause Aicardi's syndrome. Although there are some superficial similarities between Aicardi's syndrome and the aftermath of severe intrauterine infections, no infectious etiology has ever been found.¹² In addition, agenesis of the corpus callosum and the specific ocular abnormalities do not occur in any of the known intrauterine infections.

It is not known if Aicardi's syndrome is caused by a genetic abnormality. No chromosomal abnormalities have been found in patients who have had karyotyping performed. Several possible contributing factors can be considered. One possibility is an X-chromosomal-dominant inheritance with manifestation in the heterozygote and with a male lethal factor. A gene defect lethal to males has been proposed to explain female preponderance in incontinentia pigmenti and the Goltz syndrome.⁷ Another possibility is that the

syndrome is due to a multiple gene effect with a greatly increased tendency to appear in females. Finally, it is possible that all cases represent new mutations.

Acknowledgments

Harold Morris, M. D., interpreted the EEG records, and Ronald Price, M. D., performed the ophthalmological examinations. The results of the autopsy were kindly supplied by T. C. Nguyen, M. D., and Uros Roessman, M. D., of Case Western Reserve University.

References

1. Aicardi J, Lefebvre J, Lerique-Koechlin A. A new syndrome: spasm inflexion, callosal agenesis, ocular abnormalities. *Electroencephalogr Clin Neurophysiol* 1965; **19**:609-610.
2. Aicardi J. Aicardi syndrome in a male infant (letter). *J Pediatr* 1980; **97**:1040-1041.
3. deJong JGY, Delleman JW, Houben M, Manschot WA, deMinjer A, Mol J. Agensis of the corpus callosum, infantile spasms, ocular anomalies (Aicardi's syndrome); clinical and pathological findings. *Neurology* 1976; **26**:1152-1158.
4. Dennis J, Bower BD. The Aicardi syndrome. *Dev Med Child Neurol* 1972; **14**:382-390.
5. Fariello RG, Chun RWM, Doro JM, Buncic R, Prichard JS. EEG recognition of Aicardi's syndrome. *Arch Neurol* 1977; **34**:563-566.
6. Denslow GT, Robb RM. Aicardi's syndrome: a report of four cases and review of the literature. *J Pediatr Ophthalmol Strabismus* 1979; **16**:10-15.
7. Bertoni JM, von Loh S, Allen RJ. The Aicardi's syndrome: report of 4 cases and review of the literature. *Ann Neurol* 1979; **5**:475-482.
8. Curatolo P, Libutti G, Dallapiccola B. Aicardi syndrome in a male infant. *J Pediatr* 1980; **96**:286-287.
9. Hoyt CS, Billson F, Ouvrier R, Wise G. Ocular features of Aicardi's syndrome. *Arch Ophthalmol* 1978; **96**:291-295.
10. Rothner AD, Duchesneau PM, Weinstein M. Agensis of the corpus callosum revealed by computerized tomography. *Dev Med Child Neurol* 1976; **18**:160-166.
11. Tachibana H, Matsui A, Takeshita K, Tamai T. Aicardi's syndrome with multiple papilloma of choroid plexus. *Arch Neurol* 1982; **39**:194.
12. Willis J, Rosman NP. The Aicardi syndrome versus congenital infection: diagnostic considerations. *J Pediatr* 1980; **96**:235-239.