

The benign appearance of Wilms' tumor¹

Thomas Maatman, D.O.
Robert Kay, M.D.

Intrarenal masses in children are uncommon, with Wilms' tumor the most prevalent of these. Two cases are presented in which the preoperative evaluation of renal masses was highly suggestive of benign disease, renal abscess, and multilocular cyst. Surgical exploration was performed in both patients, and Wilms' tumor was found and treated successfully with radical nephrectomy. These two cases emphasize the need for surgical exploration to accurately diagnose intrarenal masses in children even when all diagnostic modalities are suggestive, but not confirmatory, of benign disease.

Index terms: Kidney neoplasms • Nephroblastoma • Wilms' tumor

Cleve Clin Q 50:279-282, Fall 1983

Malignant renal neoplasms of childhood are uncommon.¹ Wilms' tumor is the most common of these, with 450 cases reported per year in the United States. The correct diagnosis is essential to avoid progression of this fatal malignant disease, and, conversely, to avoid inappropriate treatment with radiation and chemotherapy in children with benign disease. We present two cases in which all preoperative studies indicated benign renal disease, renal abscess, and multilocular cysts. However, when surgery was performed to accurately diagnose the intrarenal mass, malignant disease was found.

Case reports

Case 1. An eight-year-old boy was referred to The Cleveland Clinic Foundation for evaluation of a possible right renal abscess. Four months before admission, he was seen at his local hospital with right flank pain,

¹ Department of Pediatric and Adolescent Medicine, Section of Pediatric Urology, Department of Urology, The Cleveland Clinic Foundation. Submitted for publication April 1983; accepted May 1983.

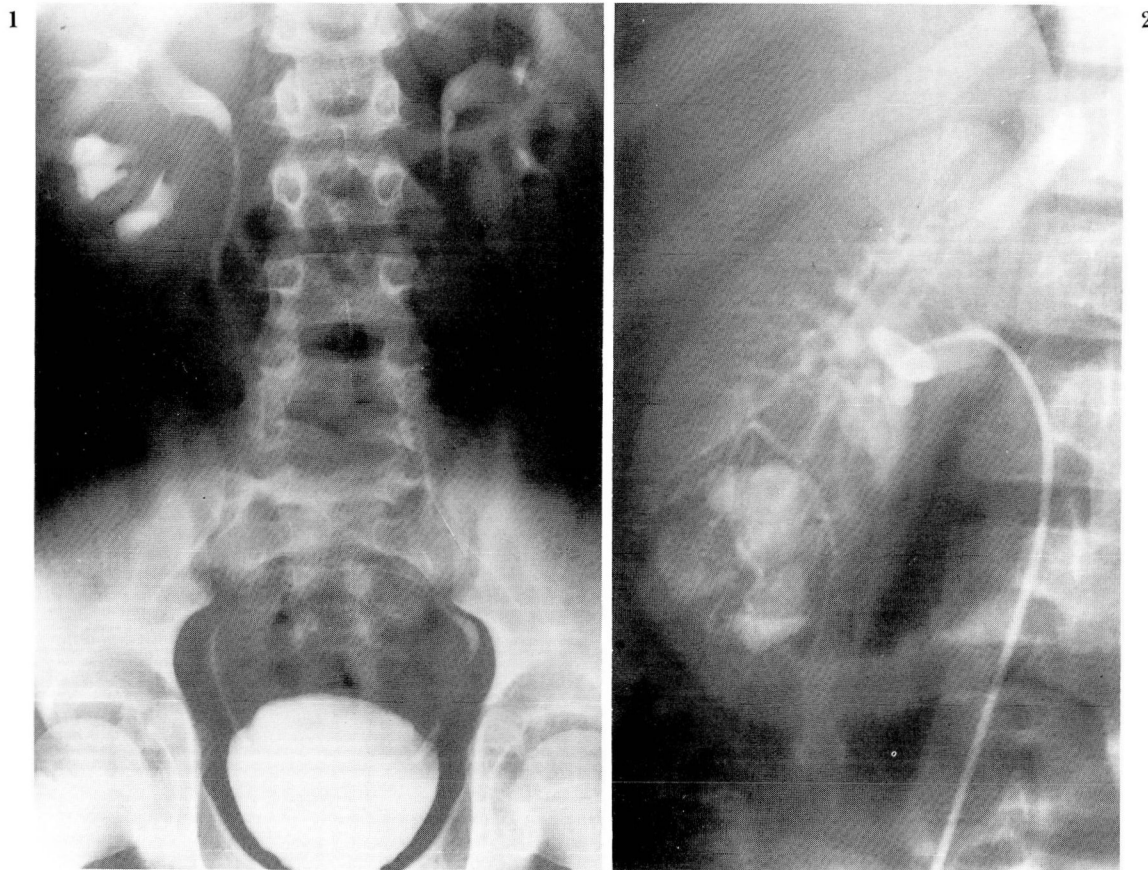


Fig. 1. Excretory urogram displaying a mass in the lower pole of the right kidney with stippled calcification.

Fig. 2. Renal angiogram demonstrating a 4 × 4-cm mass in the lower pole of the right kidney.

fever, chills, gross hematuria, and proteinuria. A diagnosis of acute pyelonephritis was made, and he was treated with intravenous antibiotics with the resolution of symptoms. Fever, pain, and hematuria returned, and his condition was reevaluated. An excretory urogram was obtained displaying a mass in the lower pole of the right kidney with calcifications (*Fig. 1*). He was referred to the Cleveland Clinic for further evaluation and treatment. On admission urine culture and sensitivities for aerobes and acid-fast bacillus were negative. Chest roentgenogram revealed a left hilar mass suggestive of granulomatous disease. Computed tomography (CT) and ultrasonography of the kidney confirmed the presence of a mass in the lower pole of the right kidney, which was suggestive of a renal abscess, but not confirmatory. Renal angiography revealed a 4 × 4-cm avascular mass in the lower pole of the right kidney (*Fig. 2*). Radiologic diagnosis was most likely that of a renal abscess. Because Wilms' tumor could not be completely excluded, the patient was taken to the operating room. Induration in the lower pole of the right kidney was noted, and a radical nephrectomy was performed. Pathologic report revealed a 3.5-cm Wilms' tumor invading the wall of the renal vein and the renal sinus classified as a stage II Wilms' tumor. Postoperatively the patient was treated with radiation therapy and chemotherapy and did well.

Case 2. A three-year-old boy was referred to The Cleveland Clinic Foundation for evaluation of an asymptomatic right upper quadrant mass that was detected on routine physical examination. Excretory urogram revealed an intrarenal mass of the right kidney with dilatation of the collecting system (*Fig. 3*). A CT scan of the right kidney revealed a large soft-tissue mass located in the anterior portion of the right kidney with irregular areas of decreased attenuation (*Fig. 4*). Ultrasound revealed a solid complex, cystic mass. Angiography demonstrated displacement of vessels, but no pathologic vessels were visualized (*Fig. 5*). Preoperative evaluation was believed to be compatible with a multilocular cyst. Because of the possible risk of an intrarenal mass in a patient of this age, surgical exploration was performed. A stage I Wilms' tumor was discovered, and a right radical nephrectomy was performed. Postoperatively the patient did well, and received chemotherapy as part of the National Wilms' Tumor Study Group protocol and currently is without evidence of disease.

Discussion

The preoperative diagnosis of Wilms' tumor is usually easily determined. However, in the National Wilms' Tumor Study I, 30 of 606 (5%)

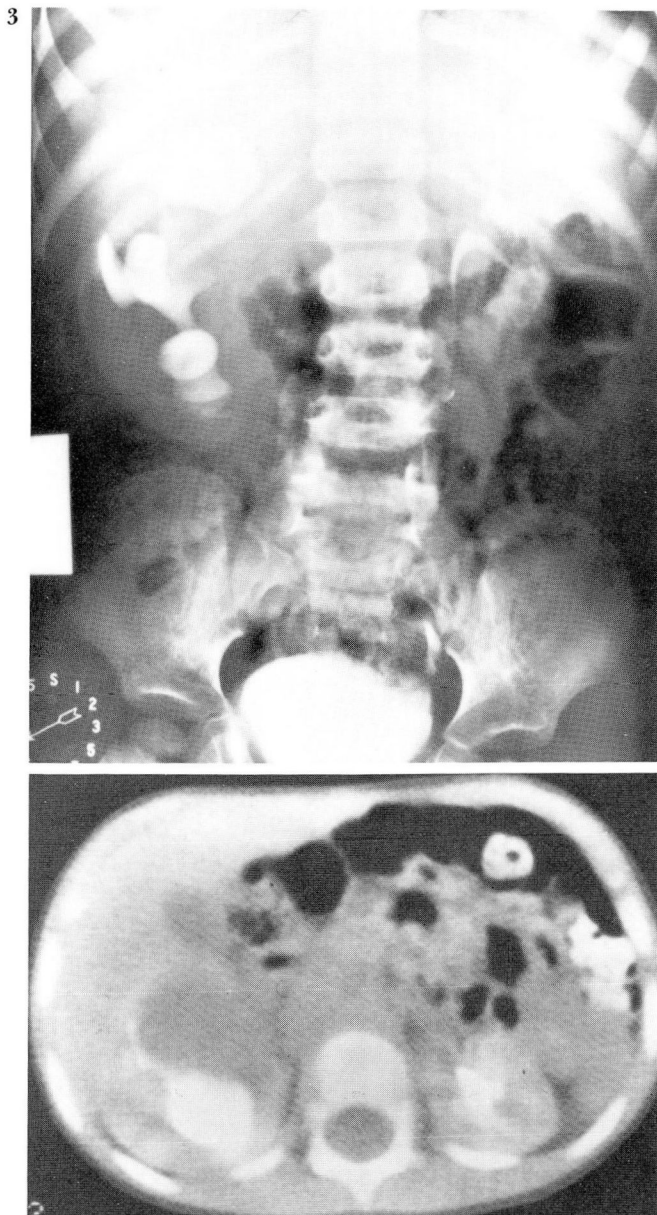


Fig. 3. Excretory urogram revealing dilatation and distortion of the right renal calyces.

Fig. 4. CT scan of the abdomen demonstrating right renal mass with cystic component.

patients had incorrect preoperative diagnoses and were ultimately proved not to have Wilms' tumor.² In our two cases, the preoperative evaluation suggested benign disease, and only surgical exploration confirmed the presence of malignant disease.

The diagnosis of Wilms' tumor is usually made on the basis of presenting symptoms, physical examination, and radiological findings. Excretory urography can usually detect a renal mass,

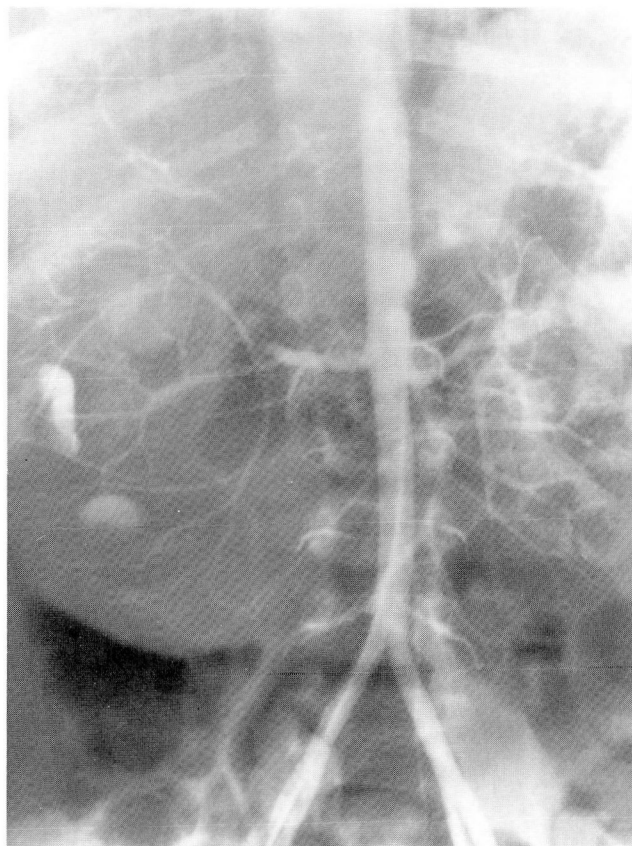


Fig. 5. Right renal angiogram displaying an avascular mass in the right kidney.

and other studies can confirm and clearly define the mass. Ultrasound and/or CT can determine the consistency, and help define the mass as solid or cystic. Cystic appearance usually suggests multicystic or polycystic kidney; however, tumor must be considered in selected cases. Necrosis and hemorrhage may lead to a cystic appearance of the tumor mass.³ In addition, tumors have been reported in multicystic kidney.^{4,5}

The necessity of arteriography in the diagnosis of Wilms' tumor remains controversial. However, it may be helpful in difficult diagnostic cases, with abnormal vascularity existing in 85% to 90% of all Wilms' tumors.⁶ The absence of pathologic vascularity, however, does not rule out Wilms' tumor as evidenced in our two cases.

Needle biopsy of selected renal masses has been used extensively in adults.⁷ The risk of disrupting the tumor and having local implantation is rare.⁸ In children, the procedure is rarely used, as the diagnosis is not usually in doubt, and a needle biopsy may potentially contaminate the local area, requiring postoperative radiation. In addi-

tion, the finding of tumor cells would be confirmatory, but a negative aspiration does not rule out the presence of a potentially malignant process. As in our two cases, if the diagnosis is in doubt, surgical exploration may be necessary as both a diagnostic and therapeutic step. The failure to correctly diagnose the renal mass in a child may allow fatal progression of the disease, and all diagnostic modalities from an excretory urogram to surgery may be required and must be used in selected cases.

References

1. Young JL Jr, Miller RW. Incidence of malignant tumors in US children. *J Pediatr* 1975; **86**:254-258.
2. Ehrlich RM, Bloomberg SD, Gyepes MT, et al. Wilms tumor, misdiagnosed preoperatively; a review of 19 National Wilms tumor study I cases. *J Urol* 1979; **122**:790-792.
3. Bloom DA, Brosman S. The multicystic kidney. *J Urol* 1978; **120**:211-215.
4. Raffensperger J, Abousleiman A. Abdominal masses in children under one year of age. *Surgery* 1968; **63**:514-521.
5. Uson AC, Del Rosario C, Melicow MM. Wilms tumor in association with cystic renal disease: report of two cases. *J Urol* 1960; **83**:262-266.
6. Clark RE, Moss AA, DeLorimier AA, Palubinskas AJ. Arteriography of Wilms' tumor. *AJR* 1971; **113**:476-490.
7. Cederlöf S. Assessment of asymptomatic space occupying lesions of the kidney. *Acta Chir Scand* 1979; **145**:185-189.
8. Gibbons RP, Bush WH Jr, Burnett LL. Needle tract seeding following aspiration of renal cell carcinoma. *J Urol* 1977; **118**:865-867.