

Petriellidium (Allescheria) boydii mycetoma in an immunosuppressed host¹

L. Stephen Kish, M.D.
James S. Taylor, M.D.
Wilma F. Bergfeld, M.D.
Geraldine S. Hall, Ph.D.

Mycetoma caused by *Petriellidium (Allescheria) boydii* was seen in a 28-year-old renal transplant recipient. This is the most common organism isolated from mycetomas in the United States and is an increasingly frequent cause of both localized and disseminated infections in debilitated or immunosuppressed patients.

Index terms: Fungus • Immunity, immunosuppression
• Kidneys, transplantation
Cleve Clin Q 50:209–211, Summer 1983

Petriellidium (Allescheria) boydii is a ubiquitous soil fungus, which is morphologically similar to *Aspergillus*. Although infection usually occurs through traumatic inoculation into the skin, infection by inhalation of ascospores also has been reported.¹ We describe mycetoma of the left leg caused by *P. boydii* in a renal transplant recipient.

Case report

A 28-year-old white man was first seen in the Dermatology Department of the Cleveland Clinic in October 1982 for evaluation of a "growing lump" on his left leg. He stated that the lesion had developed several years previously and occasionally produced pus, but denied injury at the affected site or any other skin problems. He had received a kidney transplant in 1973 for end-stage poststreptococcal glomerulonephritis and had been successfully maintained on immunosuppressive therapy since then (prednisone, 15 mg/day; azathioprine, 75 mg alternating with 100 mg/day at the time of his visit).

¹ Departments of Dermatology (L. S. K., J. S. T., W. F. B.), Pathology (W. F. B.), and Microbiology (G. S. H.), The Cleveland Clinic Foundation. Submitted for publication Feb 1983; accepted March 1983.

On physical examination, the patient appeared to be somewhat cushingoid and had a violaceous, crusted nodule, 3.5 × 2.5 cm, on the upper anterior aspect of the left leg (Fig. 1). Complete blood count, SMA-18, urinalysis, and 24-hour creatinine clearance were normal. Roentgenograms of the left leg showed a soft-tissue density corresponding to the nodule, but no significant bone abnormalities.

Microscopic examination of a skin sample from the left leg demonstrated multiple suppurative epithelioid granulomas surrounded by a lymphocytic infiltrate and a fibroblastic dermal reaction. Within the central portions of the granulomas were acute inflammatory cells and fibrinoid debris (Fig. 2). Methenamine silver and PAS stains demonstrated short, septate hyphae with terminal swellings (Fig. 3). The histopathological diagnosis was multiple infectious suppurative granulomas, compatible with mycetoma.

Multiple specimens of the exudate taken from the nodule were planted onto Sabouraud's dextrose agar with and without antibiotics and incubated at 30 C. A white, spreading aerial mycelium grew in five days and subsequently became a mousy gray as shown in Figure 4. Scotch-tape preparations revealed the typical appearance of *Petriellidium boydii* consisting of septate hyphae with simple oval conidia occurring separately or in small groups. Based upon these findings, a diagnosis of mycetoma was made. On excision of the nodule, in February 1982, there was no evidence of invasion deep into the fascia or underlying bone. To date, the postoperative course has been unremarkable.

Discussion

Petriellidium boydii is the most prevalent organism isolated from mycetomas in the United States³ and is an increasing cause of both localized and disseminated infections in debilitated or immunosuppressed patients. It has been identified as a cause of endocarditis,¹ sinusitis,⁴ necrotizing pneumonia,⁵ osteomyelitis,⁶ and brain abscesses.⁷ Usually it is easily isolated from appropriate spec-

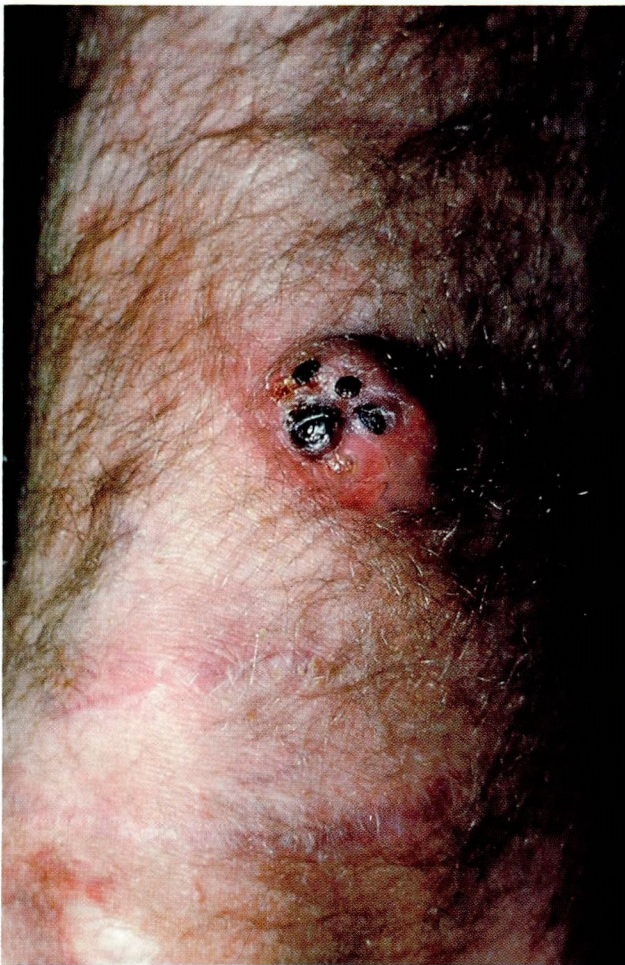

Figure 1. Violaceous, crusted nodule on the upper anterior aspect of the left leg.

imens such as exudate, tissue, or granules (often characteristic of mycetoma). Culturing onto media with antibiotics is necessary to ensure elimination of bacterial contaminants. Cultures become positive within seven days, and both the color of the mycelium and the microscopic appearance of the stained hyphae are usually sufficient for a presumptive identification of *P. boydii*. The diagnosis can be confirmed by the exoantigen test, which involves fungus-specific antisera; however, presumptive identification and a consistent clinical picture are usually adequate.

Treatment of *P. boydii* infection can be difficult. Surgical excision is the treatment of choice for localized disease, whether cutaneous or internal.^{3,8,9} Chemotherapy with intravenous miconazole has been reported to be beneficial;^{6,10} however, the fungus is generally resistant to amphotericin-B.

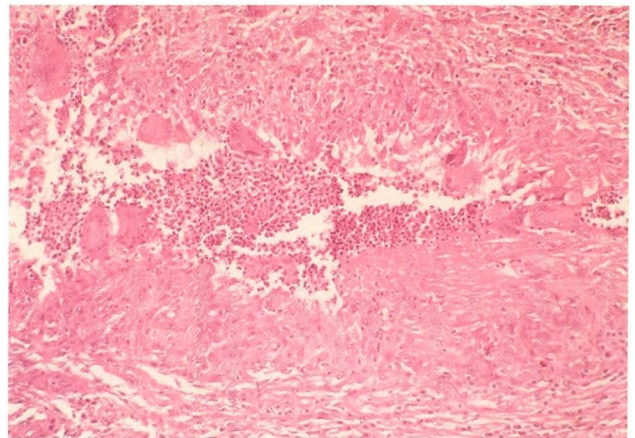


Figure 2. Suppurative epithelioid granuloma (hematoxylin and eosin, $\times 200$).

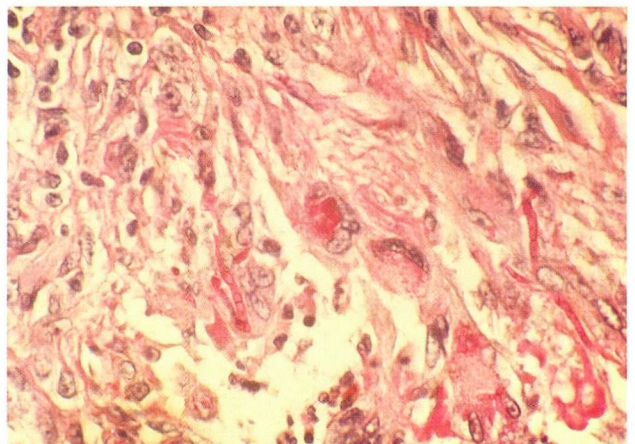


Figure 3. Central area of suppurative epithelioid granuloma containing septate hyphae with terminal swellings (PAS, $\times 400$).

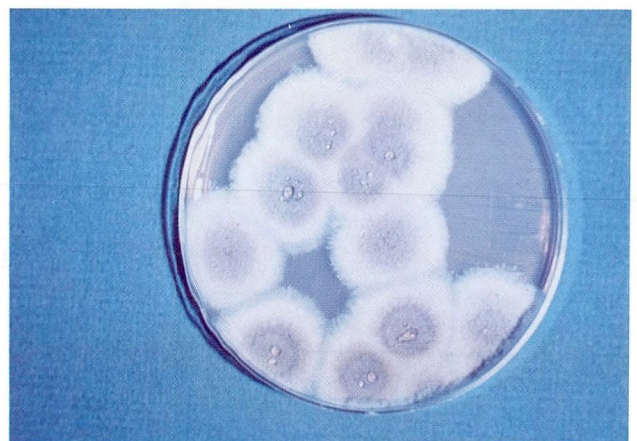

Figure 4. Gross culture of *Petriellidium boydii* on Sabouraud's dextrose agar after three to five days at 25–30°C. (Reprinted with permission from Dolan CT, Funkhouser JW, Koneman EW, Miller NG, Roberts GD. Atlas of Clinical Mycology V. Subcutaneous Mycosis. Chicago: The American Society of Clinical Pathologists, 1976.)²

P. boydii infection must be considered in the differential diagnosis of any chronic suppurative infection, especially in an immunocompromised host. The clinical appearance of mycetoma may mimic squamous-cell carcinoma, suppurative bacterial infections, or deeper fungal infections such as blastomycosis. Early recognition and prompt surgery offer the best chance for cure.

References

1. Davis WA, Isner JM, Bracey AW, Roberts WC, Garagus VF. Disseminated *Petriellidium boydii* and pacemaker endocarditis. *Am J Med* 1980; **69**:929-932.
2. Dolan CT, Funkhouser JW, Koneman EW, Miller NG, Roberts GD. Subcutaneous Mycoses. [In] *Atlas of Clinical Mycology*. Chicago: American Society of Clinical Pathologists, vol. 5, 1976.
3. Palestine RF, Rogers RS III. Diagnosis and treatment of mycetoma. *J Am Acad Dermatol* 1982; **6**:107-111.
4. Gluckman SJ, Ries K, Abrutyn E. *Allescheria (Petriellidium) boydii* sinusitis in a compromised host. *J Clin Micro* 1977; **5**:481-484.
5. Saadah HA, Dixon T. *Petriellidium boydii (Allescheria boydii)*. Necrotizing pneumonia in a normal host. *JAMA* 1981; **245**:605-606.
6. Halpern AA, Nagel DA, Schurman DJ. *Allescheria boydii* osteomyelitis following multiple steroid injections and surgery. *Clin Orthop* 1977; **126**:232-234.
7. Winston DJ, Jordan MC, Rhodes J. *Allescheria boydii* infections in the immunosuppressed host. *Am J Med* 1977; **63**:830-835.
8. Woodard BH. Asymptomatic pulmonary coin lesion with *Petriellidium boydii*. *South Med J* 1982; **75**:229-230.
9. Barnetson RS, Milne LJ. Mycetoma. *Br J Dermatol* 1978; **99**:227-231.
10. Lichtman DM, Johnson DC, Mark GR, Lack EE. Maduromycosis (*Allescheria boydii*) infection of the hand; a case report. *J Bone Joint Surg* 1978; **60A**:546-548.