

Juvenile plantar dermatosis: the “wet and dry foot syndrome”¹

Willard D. Steck, M.D.

Juvenile plantar dermatosis is a distinctive symmetrical fissuring dermatosis that affects the weight-bearing surfaces of the forefeet in prepubertal children. Most patients are hyperhidrotic and some are atopic; none has fungal disease or relevant contact allergy. The thick stratum corneum of the affected areas cracks as a result of being alternately too wet and too dry. Cure can be effected by preventing rapid drying of the skin.

Index terms: Foot, diseases • Skin, diseases
Cleve Clin Q 50:145–149, Summer 1983

Juvenile plantar dermatosis (JPD) has finally gained recognition as an entity by its inclusion in one major dermatologic textbook.¹ Few articles on the subject have appeared in the literature, and then only since 1968.² Descriptions of the condition are remarkably uniform despite a variety of names including *atopic winter feet in children*,³ *forefoot eczema*,⁴ *peridigital dermatosis*,⁵ and *recurrent juvenile eczema of the hands and feet*.⁶ Unfortunately, there has been only speculation concerning the etiology, and no form of treatment has proved satisfactory. I propose an explanation for the occurrence of JPD as well as a simple therapeutic protocol that has proved to be effective.

Background

JPD occurs almost exclusively in prepubertal children of both sexes. It symmetrically affects the weight-bearing surfaces of the feet, where the stratum corneum is thick and flexion forces are greatest, namely, the edges and

¹Department of Dermatology, The Cleveland Clinic Foundation. Submitted for publication Feb 1983; accepted March 1983.

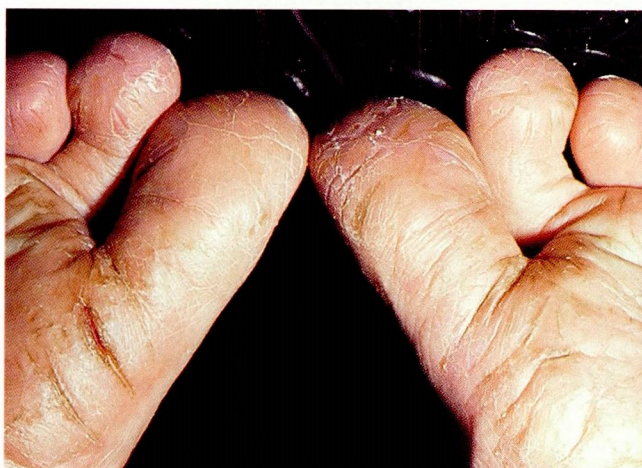

Figure 1. JPD showing crazing of horny layer.

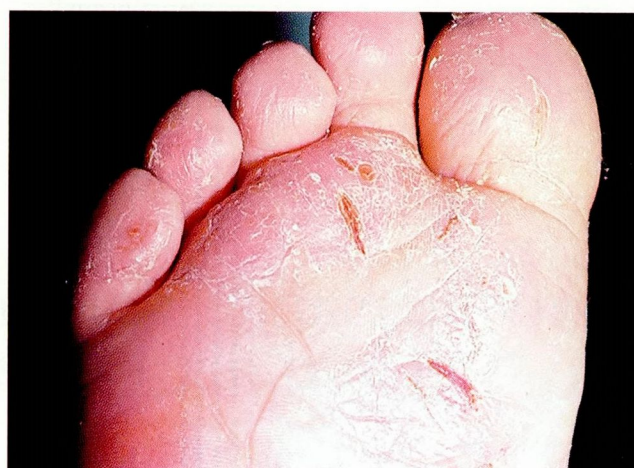

Figure 2. JPD showing fissures penetrating the dermis.

plantar pads of the forefeet; the medial edges, plantar pads, and tips of the great toes; the lateral edges and plantar pads of the little toes; the tips of the other toes; and occasionally the edges of the heel pads. The thin skin of the interdigital areas and arches is not involved.

The intact stratum corneum of the plantar pads has a glossy sheen, but most of the affected horny layer is crazed with fissures of various depths (*Fig. 1*). The deeper fissures follow the natural lines of flexion and penetrate well into the dermis (*Fig. 2*). Their edges curl outward, away from the rifts, as if they were being retracted by some force at the surface (*Fig. 3*). The fissures are usually clean but may contain remnants of blood, serum, or rarely pus. There is little erythema and no inherent eczema, although the latter may occur concomitantly. Pain is the usual symptom, and itching is uncommon. Nei-

ther fungal disease nor contact dermatitis is involved.^{3,5,7}

Only a few biopsies have been done on patients with JPD, and no distinctive histologic features were seen. Neering and van Dijk⁷ found hyperkeratosis, localized parakeratosis, acanthosis, spongiosis, dermal edema, and a slight mononuclear, perivascular infiltrate, which they interpreted to be consistent with asteatotic eczema. Shrank⁸ saw similar but even less impressive changes; however, they did note focal spongiosis around the sweat ducts in their course through the malpighian layer. In the stratum corneum, the coils were narrowed and some were blocked. Enta⁵ saw only evidence of chronic dermatitis.

Review of the literature

Prior to 1968, the literature contained few references to noninfectious, nonallergic derma-

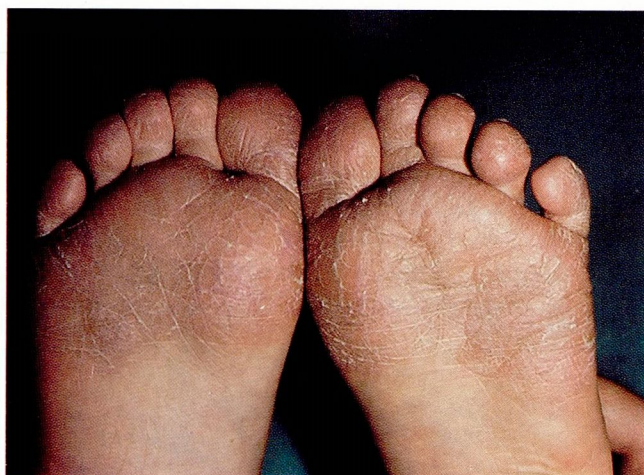

Figure 3. JPD in patient before treatment.

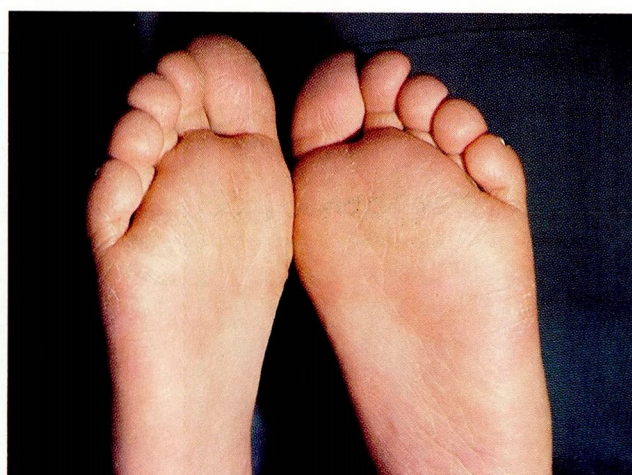


Figure 4. Same patient after two weeks of treatment.

tos of the feet. Silvers and Glickman² discussed such conditions in 15 children, among whom were several who probably had JPD. All were thought to have atopic dermatitis triggered by tight shoes, heat, friction, and perspiration, since exacerbation was common in hot weather.

Möller³ (Malmö, Sweden) described 7 boys and 6 girls between the ages of 2 and 11 years with typical JPD. They had no clinical evidence of atopic disease, and tests for "white dermographism" were equivocal. About half of them had a family history of atopy. Because of this, and since the condition was always worse in cold weather, it was called "atopic winter feet in children." Results of therapy were disappointing.

Enta⁵ (Calgary, Canada) reported 52 cases of what he called "peridigital dermatitis in children." Boys and girls 3 to 15 years of age were equally represented, as well as one 32-year-old man. All had typical changes of JPD, and some had fissuring of the fingers as well. Only one had mild flexural skin changes suggesting atopic dermatitis, but 32 had either a personal or family history of atopy. Since the disease was always worse in winter, Enta speculated that occlusive winter footwear caused extreme perspiration and rubbing of the feet, which when followed by exposure to "markedly low humidity in the household" added to the dryness and fissuring. Topical corticosteroids and a change to natural-fiber socks and cooler shoes gave reasonably good control.

Schultz and Zachariae⁶ (Aarhus, Denmark) studied 13 boys and 7 girls 7 to 12 years of age. Most undoubtedly had JPD, but many also had similar dermatitis of the hands. Although none had evidence of atopic dermatitis, 6 had a family history of atopy. Tests with nicotinic acid furfuryl (Trafuril)⁹ gave negative or doubtful results. Since most children were seen during winter, hyperhidrosis, tight shoes, and inadequate foot hygiene were suspected.

Mackie and Husain¹⁰ (Glasgow) studied 55 boys and 47 girls with a condition similar to that described by Möller³ and Schultz and Zachariae.⁶ Since they found no close association with atopy, they proposed the name "juvenile plantar dermatosis" and suggested that it was a new entity. They noted no distinct seasonal variations nor clear-cut etiologic factors. Thirteen children had positive patch tests, but only 8 were sensitive to constituents of footwear, and changes of footwear did not result in resolution of the dermatitis.

Millard and Gould¹¹ (Leeds) examined 11 boys

and 10 girls with JPD. The age range was a rather wide 2–16 years, and about half of the patients were atopic. No seasonal differences were noted. They credited recent changes in footwear style and construction with causing hyperhidrosis and suggested that infrequent changes of shoes and socks might contribute to the dermatosis.

Hambly and Wilkinson¹² (Paris) reported JPD in 27 children between 2 and 14 years of age, stating that they had seen their first case in 1968. The disease seemed worse in summer. Friction caused by nylon socks was thought to be the cause. Their patients obtained some benefit from coal tar.

Verbov⁴ (Liverpool) believed that JPD was a manifestation of atopy and found 12 cases among 104 children referred to him with a diagnosis of atopic eczema. The disease improved in warm weather.

Neering and van Dijk⁷ (Amsterdam) agreed that JPD was a new entity and added 23 patients, 4 of whom also had fissuring of the fingers. No seasonal bias was noted.

Stanker¹³ (Aberdeen) noted JPD in identical twin sisters 10 years of age. The condition was worse in the one who was "a bit of a tomboy."

Shrank⁸ (Shrewsbury) saw 38 children with JPD, none prior to 1967. None had atopic dermatitis nor a family history of atopy. Interference with the delivery of sweat to the affected areas was shown by several methods, although the sweat gland apparatus remained intact below the horny layer. Occlusive modern footwear was thought to be at fault.

Mackie¹⁴ (Glasgow) summarized 269 cases of JPD reported between 1972 and 1982. The appearance of the feet was highly typical. A few patients had similar changes affecting the hands. Most patients were prepubertal children, with boys outnumbering girls by a small margin. Slightly more than a normal number of children were atopic or had a family history of atopy. None had fungal disease, and contact sensitization (if any) was noncontributory. The recent trend toward the use of synthetic materials and rubber in manufacturing footwear was thought to account for the disease by causing maceration. Therapy has not been highly successful.

Discussion

Personal observations: Before the term *juvenile plantar dermatosis* was introduced,¹⁰ I called this condition "wet and dry foot syndrome" because it is the rapid alteration between excessive wet-

ness and dryness that causes the thick, horny plantar layer to crack. I have seen it with increasing frequency since 1962. Its occurrence at various times of the year in different parts of the world suggested its true nature. It occurred in a number of patients at Travis Air Force Base, California, always in the summer. Summers there are long and hot and there are many cases of asteatotic eczema or "winter itch." Although I did not realize then that JPD and asteatotic dermatitis are kindred processes, I noticed that children with JPD always had wet feet on examination and suggested that they wear leather shoes and cotton socks, and that they should give their feet a chance to dry out whenever possible. In retrospect, this was the worst possible advice.

In Germany between 1964 and 1967, asteatotic eczema reached epidemic proportions each winter among Americans stationed there. Fissured forefeet were also seen rather commonly in children, but in winter more than summer. Thus, I felt that the two conditions probably had something in common.

During World War II, Germans were usually cold in winter. Later, when fuel became plentiful, they kept their living quarters overly warm. Houses and apartments are snugly built, and little fresh air comes inside. Relative humidity is low. Children wear heavy, waterproof shoes outside the house, but these are usually taken off on reentering. Because the floors are warm, children often go barefoot in the house. Rapid drying of wet feet leads to JPD in those with hyperhidrosis.

I saw a few cases of JPD at Scott Air Force Base in southern Illinois between 1967 and 1971, always in winter. I have seen several at the Cleveland Clinic since 1971, most of them in winter as well. Those who have the disease in summer are almost invariably swimmers.

Pathomechanics: In 1952, Blank¹⁵ showed that the stratum corneum must contain about 10 mg of water per 100 mg of horny tissue to be soft and pliable; with less than 10% water, the horny layer becomes brittle and is easily cracked. He also showed that a hyperhydrated horny layer loses moisture to dry air faster than it can be infused from underlying tissues. An isolated strip of keratinous material will maintain a constant, adequate moisture content when the relative humidity of the surrounding air is about 60%. In moister air the keratinous strip will absorb water, while in air with less than 60% relative humidity it will dry out and become brittle. The stratum

corneum of intact skin also gains or loses moisture with variations in humidity. In most circumstances, sufficient moisture diffuses into the horny layer from underlying tissues to keep it soft, despite evaporation in dry surroundings. Gaul and Underwood¹⁶ studied the relationship between chapping of the skin and atmospheric conditions and showed that chapping occurs in otherwise normal skin when rapid moisture loss follows excessive hydration.

The above observations can be related to the development of JPD by recalling some anatomic and biologic features of the plantar stratum corneum as stated by Kligman¹⁷ in 1964. At 600 μ , it is about 40 times as thick as the membranous horny layer of most other parts of the body. Individual keratin cells have a diameter of about 30 μ but a thickness of only 0.8 μ . The plantar stratum corneum consists of several hundred layers of keratin cells bonded together by an intracellular cement, with the deeper layers being much more tightly coherent than the superficial layers. The stratum corneum is hygroscopic, capable of absorbing two to three times its own weight in water and swelling to twice its normal thickness in the process. Wrinkling of the palmar or plantar skin can be seen after it has been immersed for a time in water, indicating some increase in lateral dimensions; however, most of the swelling is manifested as an increase in thickness rather than breadth. This is fortunate, as the resultant shearing forces would otherwise be highly destructive. Finally, water can be lost from thick palmar or plantar skin much more rapidly than from thinner but more coherent horny layers of other parts of the body. It is fortunate that moisture can diffuse rapidly through the thick plantar pads; otherwise extreme gradients of water content, coupled with the consequent disparity between the size of the superficial and deep layers, would be likely to damage the hydrated palmar and plantar skin as it dries.

My research suggests that saturation and desaturation of the keratin layer, with attendant swelling and shrinking, produce minor damage on each occasion. If distortion proceeds slowly and occurs infrequently, damage is negligible; however, if the hydrated skin is allowed to dry so rapidly that an appreciable saturation gradient develops, cellular bonds rupture as the cells of the outer layers shrink and lose their spatial relationships to the still swollen deeper cells. Each rent in the fabric of superficial layers permits

water to be lost more rapidly; if the process is repeated frequently, the damage caused by each previous event adds destructive momentum to the next.

Occurrence of JPD: Children whose feet are frequently wet (whether due to hyperhidrosis, occlusive footwear, or swimming) and who have habits that permit rapid drying are likely to get JPD. Dry, moving air, whether forced or natural, will cause overly rapid desiccation. In general, JPD can be expected to develop during winter in cold climates and during the driest season in milder climates.

Atopy may contribute to the process in some children; however, it is not mandatory for the development of JPD.

Although JPD has been seen infrequently for many years, it has only recently occurred in large enough numbers to be separated from other forms of eczema. Recent changes from natural to synthetic footwear materials and adoption of "sports shoes" for all occasions have been suggested by almost every author as contributing factors. Certainly, such materials are less absorptive and more occlusive, leading to excessive wetness of the feet. Possibly insulation, central heating, and wall-to-wall carpeting have furthered the process by providing an excessively dry environment, since children in homes warmed by fireplaces or space heaters are highly unlikely to have JPD.

Treatment

Since there is little that can be done about the conditions that contribute to JPD, treatment must approach the problem from the other aspect, namely, if this is prevented, JPD can be cured without need of special medication (*Fig. 4*). Whenever the shoes are taken off, an ointment must be applied to the feet immediately. Any type that is somewhat occlusive and can be applied to fissured skin with reasonable comfort, such as petrolatum, is generally satisfactory. However, it must be applied as soon as the child

takes off his shoes or emerges from his bath (unless shoes are put on immediately).

Swimming is permitted, but the child should remain in the pool only for a specified time, apply the ointment as soon as he comes out, and then stay out of the pool. Diving or other such activity is permissible as long as the feet are not allowed to dry out repeatedly. Only by compliance with this program on the part of the patient can the healing process be productive.

References

1. Rook A, Wilkinson DS. Eczema, lichen simplex and prurigo. [In] Rook A, Wilkinson DS, Ebling FJG, eds. *Textbook of Dermatology*. 3rd ed. London: Blackwell, 1979; pp 322-323.
2. Silvers SH, Glickman FS. Atopy and eczema of the feet in children. *Am J Dis Child* 1968; **116**:400-401.
3. Möller H. Atopic winter feet in children. *Acta Derm Venereol* 1972; **52**:401-405.
4. Verbov J. Atopic eczema localized to the forefoot; an unrecognized entity. *Practitioner* 1978; **220**:465-466.
5. Enta T. Peridigital dermatitis in children. *Cutis* 1972; **10**:325-328.
6. Schultz H, Zachariae H. The Trafturil test in recurrent juvenile eczema of hands and feet. *Acta Derm Venereol* 1972; **52**:398-400.
7. Neering H, van Dijk E. Juvenile plantar dermatosis. *Acta Derm Venereol* 1978; **58**:531-534.
8. Shrank AB. The aetiology of juvenile plantar dermatosis. *Br J Dermatol* 1979; **100**:641-648.
9. Murrell TW Jr, Taylor WM. The cutaneous reaction to nicotinic acid (niacin)-furfuryl. *Arch Dermatol* 1959; **79**:545-550.
10. Mackie RM, Husain SL. Juvenile plantar dermatosis; a new entity? *Clin Exp Dermatol* 1976; **1**:253-260.
11. Millard LG, Gould DJ. Juvenile plantar dermatosis (letter). *Clin Exp Dermatol* 1977; **2**:186-187.
12. Hambly EM, Wilkinson DS. Sur quelques formes atypiques d'eczéma chez l'enfant. *Ann Dermatol Venereol (Paris)* 1978; **105**:369-371.
13. Stanker L. Juvenile plantar dermatosis in identical twins. *Br J Dermatol* 1978; **99**:585.
14. Mackie RM. Juvenile plantar dermatosis. *Semin Dermatol* 1982; **1**:67-71.
15. Blank IH. Factors which influence the water content of the stratum corneum. *J Invest Dermatol* 1952; **18**:433-440.
16. Gaul LE, Underwood GB. Relation of dew point and barometric pressure to chapping of normal skin. *J Invest Dermatol* 1952; **19**:9-19.
17. Kligman AM. The biology of the stratum corneum. [In] Montagna W, Lobitz WC Jr, eds. *The Epidermis*. New York: Academic Press, 1964, pp 387-433.