

Long-term and short-term histopathologic changes in the skin after PUVA therapy¹

Daniel M. Ingraham, D.O.
Wilma F. Bergfeld, M.D.
Philip L. Bailin, M.D.
Willard D. Steck, M.D.
James S. Taylor, M.D.
Kenneth J. Tomecki, M.D.

Psoriatic patients engaged in chronic psoralen and long-wave ultraviolet light therapy (PUVA) were evaluated for temporary and permanent histologic changes of the skin. Biopsies of skin from the buttock were taken before, during, and three years after PUVA therapy and histologic changes were compared. Hyperkeratosis, acanthosis, melanosis, and occasional focal dysplasia were noted in the epidermis. Increased deposition of acid mucopolysaccharide (hyaluronic acid), decreased, fragmented elastic fibers within the papillary dermis, and increased, thickened elastic fibers within the reticular dermis were observed. Comparison between changes seen after long-term continuous PUVA therapy and those seen three years later showed no significant differences, indicating that these changes may be irreversible.

Index terms: Psoriasis, therapy • PUVA • Skin, diseases
Cleve Clin Q 50:133-139, Summer 1983

The combination of oral methoxsalen and long-wave ultraviolet light (PUVA) was shown to be effective therapy for psoriasis by Parrish et al¹ in 1974, and guidelines for treatment were established by a comparative study in 1977.² However, subsequent studies have demonstrated various unforeseen effects on the skin after PUVA therapy. Bergfeld³ reported epidermal hyperkeratosis, acanthosis, and basilar melanosis as well as acid mucopolysaccharide deposition in the papillary dermis and variable changes of the elastic fibers in PUVA-treated skin. Abel et al⁴ observed focal epidermal dysplasia in approximately half of their PUVA-treated patients. Amyloid deposition has also been found in the epidermis⁵ and superficial dermis^{5,6} after PUVA therapy.

¹ Department of Dermatology, The Cleveland Clinic Foundation. Submitted for publication Feb 1983; accepted March 1983. An extended abstract of this article was previously published in Farber EM, et al: *Psoriasis*. New York, Grune & Stratton, 1982.

In the present histologic study, 30 psoriasis patients were treated with PUVA from 1975 to 1981. Biopsy specimens of uninvolved skin from the buttock were taken after continuous therapy in 14 patients an average of three years after therapy in 16 and were compared with pre-PUVA biopsy specimens to see whether PUVA-related histologic changes are permanent or reversible.

Materials and methods

Thirty psoriasis patients who had had biopsy of the skin from the buttock prior to and/or during PUVA underwent additional 4-mm punch biopsies from nonpsoriatic, unfreckled buttock skin after prolonged PUVA therapy as described by Melski et al.² The 14 patients in Group I (4 women and 10 men) had biopsy after accumulating 820–6150 joules/cm² (median, 1380 joules/cm²) of long-wave ultraviolet light (UVA) over a period of 50–73 months (median, 65 months). The 16 patients in Group II (11 women and 5 men) had biopsy 8–36 months (median, 38 months) after completing PUVA therapy, during which they accumulated 140–5412 joules/cm² (median, 1124 joules/cm²) of UVA. This group had previously received PUVA over a period of 30–61 months (median, 32 months). Age and skin types are indicated in *Tables 1 and 2*.

The punch biopsy specimens were obtained after intradermal infiltration of 1% lidocaine (Xylocaine), placed in formalin solution, and stained with hematoxylin and eosin, periodic

acid-Schiff, digested and undigested colloidal iron, Verhoeff or Gomori elastic, and crystal violet stains. Multiple sections of pre-PUVA, mid-PUVA, and post-PUVA biopsy specimens were examined by the same dermatopathologist, looking for relative changes in the epidermis and for dermal changes in vascularity, collagen, elastic fibers, and acid mucopolysaccharide deposition.

Results

Clinically, patients receiving on-going, long-term PUVA therapy had general tanning with scattered ephelides, occasional mildly hypopigmented macules, mild to moderate general dryness, and in some cases fine wrinkling of the skin (*Fig. 1*). In the patients who discontinued PUVA therapy, mild hyperpigmentation persisted; most had residual ephelides, a few had residual hypopigmented macules, and some had residual fine wrinkling of the skin.

Histologically, both groups showed mild lamellar orthokeratosis, slight acanthosis, and variable patchy or diffuse epidermal melanosis (*Fig. 2*). Most specimens demonstrated increased dermal fibroblasts and mild vascular ectasia within the papillary dermis. Mild focal epidermal dysplasia (*Fig. 3*) was found in 2 patients in Group I and 3 in Group II. Colloidal iron stains demonstrated increased deposition of mucopolysaccharide (hyaluronic acid) within the papillary dermis after prolonged PUVA therapy (*Fig. 4*). Acid mucopolysaccharide deposition was increased in 9 patients in Group I and 12 in Group II, unchanged in 3 patients in Group I and 2 in Group II, and

Table 1. Histopathologic changes after prolonged PUVA therapy

Age	Skin type	Total joules/cm ²	Elastic fibers		Acid mucopolysaccharides			
			Decreased and fragmented in the papillary dermis	Increased and thickened in the reticular dermis	Unchanged	Decreased	Increased	Unchanged
48	III	2971	+	+	+	...
63	III	1097	...	+	+	...
39	III	2825	+	+	+
57	IV	1078	+	+
38	III	819	+	+	+	...
35	III	1383	+	+	+	...
61	IV	6149	...	+	+
52	II	1200	+	...	+	...
48	III	3735	+	+	+	...
46	III	1587	+	+	+	...
37	III	1396	+	+
47	III	1580	+	+	+	...
50	IV	2686	+	+	+
29	III	870	...	+	+	...

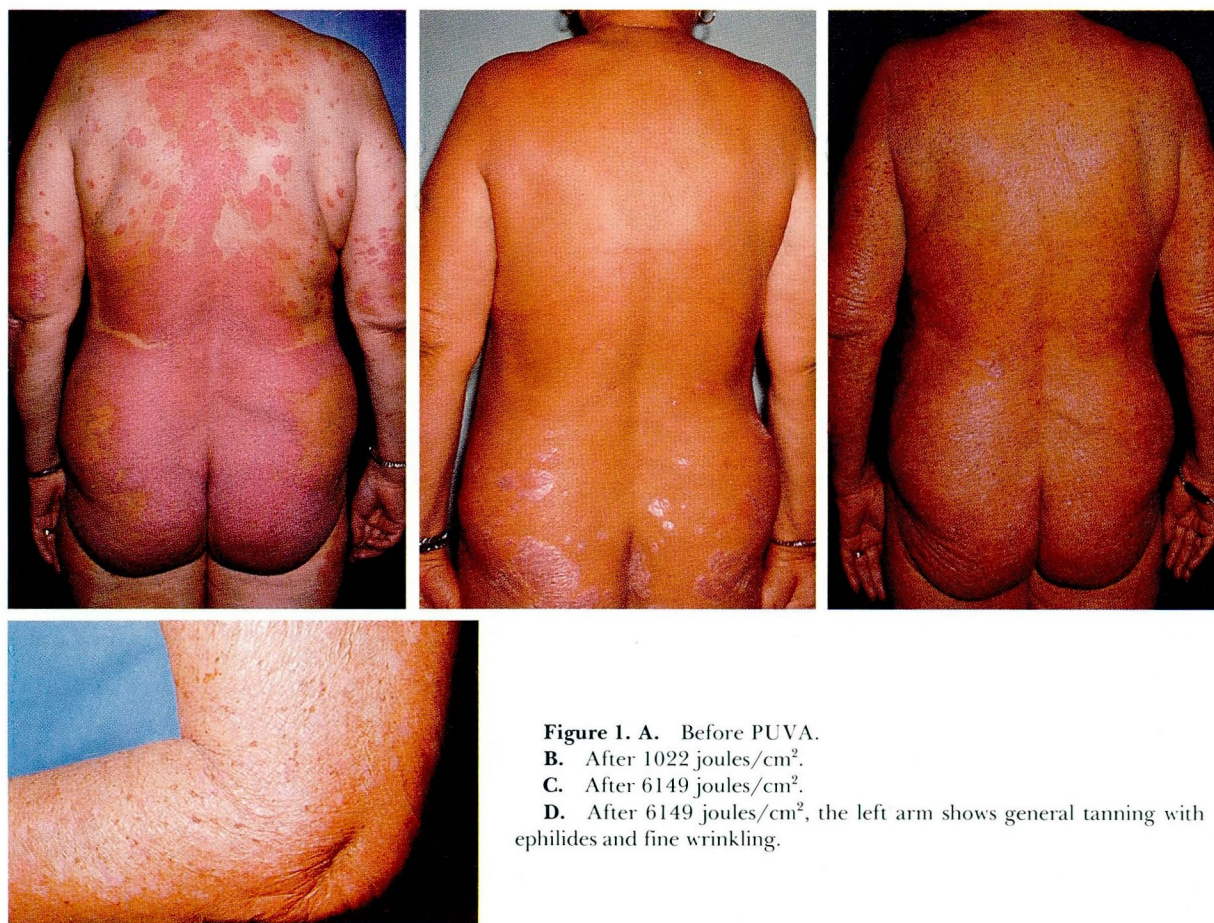

Table 2. Histopathologic changes after discontinuance of PUVA therapy

Age	Skin type	Total joules/cm ²	Time off PUVA (Mo)	Elastic fibers			Acid mucopolysaccharides		
				Decreased and fragmented in the papillary dermis	Increased and thickened in the reticular dermis	Unchanged	Decreased	Increased	Unchanged
61	II	3437	8	+	+	+	...
60	IV	1522	38	+	+	+	...
67	II	466	46	+	+	+
54	III	1328	28	+	...	+	...
66	III	5412	11	...	+	+	...
55	II	1186	43	...	+	+	...
53	II	140	63	+	+	...
20	III	872	17	+	+	...	+
59	II	1124	14	+	+	...
42	III	2071	19	...	+	+	...
79	III	577	48	+	+	+	...
50	III	338	49	+	+
52	III	659	54	...	+	+	...
66	IV	198	61	+	+
30	II	357	36	+	+	+	...
54	III	1666	17	+	+	...

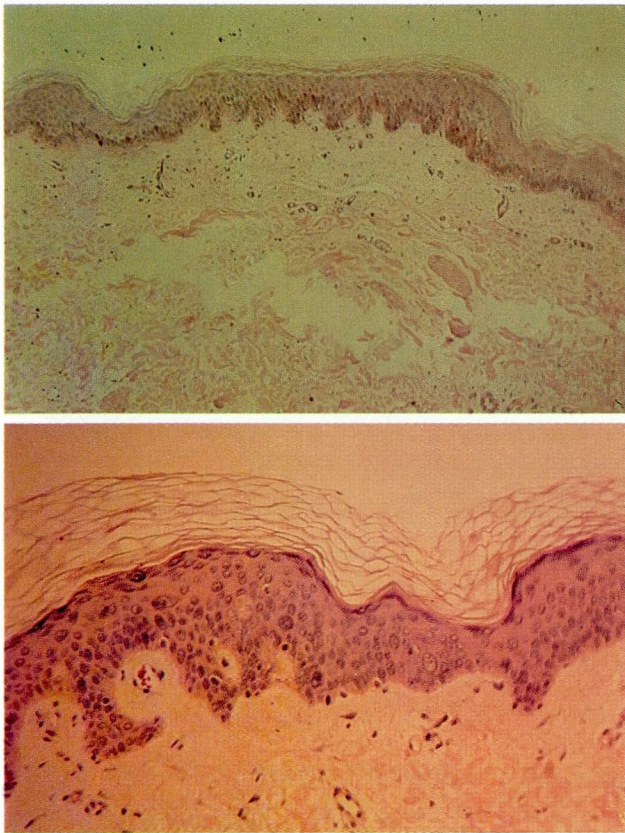


Figure 2. After 3736 joules/cm², lamellar orthokeratosis, mild acanthosis, and melanosis are present (periodic acid-Schiff, $\times 10$).

Figure 3. After 820 joules/cm², focal dysplasia can be seen (hematoxylin and eosin, $\times 20$).

decreased in 2 patients in Group I and 2 in Group II. Elastic stains showed distinctive but variable changes (*Tables 1 and 2*). Most specimens demonstrated fragmentation, loss of arborization, and a general decrease in the number of elastic fibers in the papillary dermis, as observed in 8 patients in Group I and 9 in Group II. The upper and mid-reticular dermis demonstrated thickening, clumping, shortening, and increased numbers of elastic fibers (*Fig. 5*), seen in 11 patients in Group I and 10 in Group II. Elastic fibers were unchanged in 3 patients in Group I and 3 in Group II. Dermal fibrosis was seen in 2 patients in Group I and 4 in Group II. Crystal violet stains were negative for amyloid deposition in all 30 patients (*Tables 1 and 2*).

There was no statistically significant difference between Groups I and II with regard to mucopolysaccharide deposition or elastic fiber changes in the papillary or reticular dermis, as measured by the chi-square test. Skin typing did not correlate with changes according to Fisher's exact test. Acid mucopolysaccharide deposition was signifi-

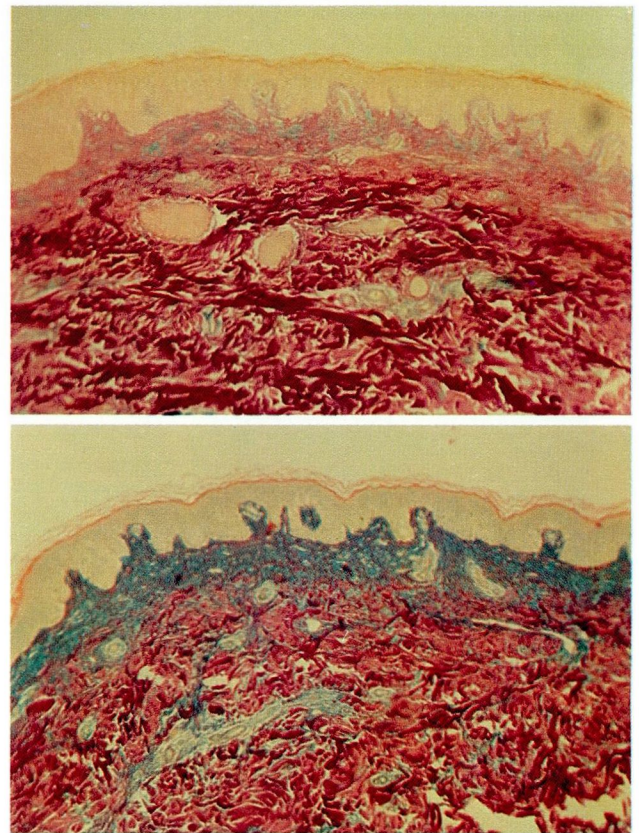


Figure 4. A. Before PUVA (colloidal iron, $\times 4$).

B. After 1522 joules/cm², deposition of acid mucopolysaccharides is evident in the papillary dermis (colloidal iron, $\times 4$).

cantly more pronounced in those receiving more than 1000 joules/cm² by Fisher's test ($p < 0.04$) among the patients in Group II, but not in Group I. No significant correlation of elastic fiber changes with total joules/cm² could be made.

Discussion

Rosario et al⁷ studied the histopathological changes in the skin after equally erythemogenic doses of ultraviolet irradiation and found that the effects of UVB and UVC were greater in the epidermis, whereas those of UVA were greater in the dermis. PUVA produced prominent changes in both the epidermis and dermis, as confirmed by our study.

The epidermis responds to UVB, UVC, and PUVA with hyperkeratosis and acanthosis.⁷ Epidermal melanosis is a well-known effect of PUVA therapy, often accompanied by the development of ephelides and occasionally by mottled hypopigmentation and hyperpigmentation.⁸ Melanocytic changes have been described ultrastructurally^{9,10} as an increase in the number and size of melanocytes, with large numbers of melanosomes in all

stages of melanization. In Zelickson's study⁹ some melanocytes extended into the dermis by means of epidermal columns and some remained free within the dermis; in addition, pigmentary changes were present 15 months after PUVA therapy was discontinued. In our study, melanosinosis was prominent after chronic PUVA therapy and was still present histologically in some patients, although to a lesser degree, three years after therapy.

Mild focal epidermal dysplasia was seen less frequently in our study than in the study of Abel et al.⁴ However, we were more concerned with persistence of epidermal dysplasia three years after PUVA therapy. Abel et al also noted development of actinic keratoses in 17% of their 104 patients after one year of PUVA therapy. These findings raise the question of whether PUVA might initiate and/or promote skin cancer in man. There is some controversy in the literature concerning this topic. No significant increase in skin cancer in PUVA patients could be documented by Roenigk and Caro,¹¹ Lassus et al,¹² Stüttgen,¹³ and Grupper.¹⁴ However, Stern et al¹⁵ and Lobel et al¹⁶ observed such an increase and found that a higher proportion of these were squamous-cell carcinomas rather than the usually predominant basal-cell carcinomas; they were seen in an older age group and probably represented a dose-response phenomenon. Risk factors that may have promoted cutaneous carcinomas included ionizing irradiation, ingestion of arsenic, and light-colored, poorly tanning skin (types I and II).

Levin et al¹⁷ noted progressive mucin deposition that appeared to correlate with the length of PUVA therapy, as we did. In our study, deposition persisted after cessation of PUVA therapy; however, Levin suggested that mucin deposition was reversible, as seen in 4 patients evaluated 18 months after discontinuation of PUVA therapy with an average total dosage of 600 joules/cm². Our study also suggested progressive deposition of acid mucopolysaccharides in the papillary dermis with PUVA therapy, believed to be secondary to the effects of PUVA on the fibroblasts. However, this deposition appeared to persist three years after PUVA was discontinued, indicating that mucin deposition in man may be irreversible or slowly reversible.

Kligman¹⁸ reviewed the phenomenon of solar elastosis and proposed that sunlight affects the fibroblasts, thereby altering the usual ratio of ground substance (mucin), elastic fibers, and col-

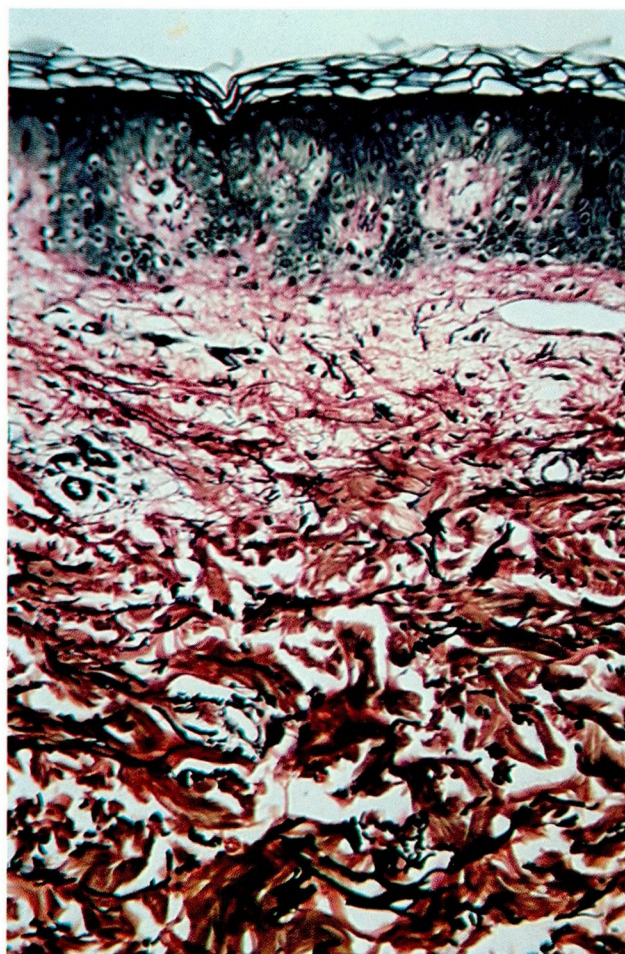


Figure 5. After 1522 joules/cm², elastic fibers are decreased and fragmented, with loss of arborization in the papillary dermis and increased, clumped, thickened elastic fibers in the reticular dermis (Verhoeff elastic, $\times 10$).

lagen production. The effects of PUVA on elastic tissue in our study appear to differ from the solar elastosis described by Kligman¹⁸ and more recently by Epstein.¹⁹ In solar elastosis, the elastic fibers become thickened, curled, clumped, and generally increased in the papillary and reticular dermis. Our study demonstrated similar changes in the reticular dermis; however, in the papillary dermis PUVA appeared to cause fragmentation, loss of arborization, and a decrease in the number of elastic fibers. Moreover, other studies^{8,20} have shown a thin zone of homogenization and loss of elastic fibers below the dermal-epidermal junction, felt to represent reduplication of the basal lamina,⁸ whereas our study showed extensive changes in the elastic fibers throughout the papillary dermis.

Zelickson et al²¹ analyzed the ultrastructural sequence of alteration of elastic tissue with PUVA

therapy, demonstrating loss of elastin followed by breakdown of the microfibrils and fragmentation of the elastic fibers. These changes did not appear to be significantly changed 15 months after discontinuance of PUVA therapy. Again, in our study, both acid mucopolysaccharide deposition and elastic fiber changes persisted three years after PUVA was discontinued. The mechanism for the destruction of elastic tissue and alteration of fibroblast production by PUVA is unknown. Whereas the effect of PUVA on the elastic fibers in the reticular dermis is similar to that seen in actinically damaged skin as described by Kligman¹⁸ and Epstein,¹⁹ the relative fragmentation and decrease in elastic fibers in the papillary dermis are not.

Although it is difficult to formulate a precise quantitative comparison of epidermal and dermal changes in our two groups of patients, we observed no statistically significant changes after long-term PUVA therapy, compared with those seen after therapy was discontinued. As a result, we believe that these changes are either irreversible or slowly reversible. Further long-term studies of larger numbers of patients, including a longer follow-up period, will be necessary to correlate skin type, total PUVA exposure, and risk factors associated with PUVA-induced histologic skin changes and cutaneous carcinogenesis.

Summary

PUVA is an effective form of therapy for psoriasis, which appears to cause irreversible or slowly reversible clinical and histologic skin changes. In our study, the chronic changes observed immediately after long-term PUVA therapy were not significantly different from those seen three years after PUVA therapy was discontinued. Epidermal changes included hyperkeratosis, acanthosis, and melanosis; dysplasia was only occasionally observed. Deposition of mucopolysaccharide (hyaluronic acid) was increased in the papillary dermis. Elastic tissue was decreased and fragmented in the papillary dermis and increased and thickened in the reticular dermis. Amyloid stains of all biopsy specimens were negative.

Since focal epidermal dysplasia was seen after prolonged PUVA therapy as well as three years after PUVA therapy had been discontinued, we recommend that the skin of these patients be monitored every 6–12 months even after therapy has been completed. The long-term effects of PUVA on the skin, including loss of elasticity,

irreversible solar damage, and carcinogenesis, must be considered, especially in younger patients who may require many years of PUVA therapy and in patients with prior skin cancer, ionizing irradiation, arsenic ingestion, or poor tanning capability.

References

1. Parrish JA, Fitzpatrick TB, Tanenbaum L, Pathak MA. Photochemotherapy of psoriasis with oral methoxsalen and long-wave ultraviolet light. *N Engl J Med* 1974; **291**:1207–1211.
2. Melski JW, Tanenbaum L, Parrish JA, Fitzpatrick TB, Bleich HL. Oral methoxsalen photochemotherapy for the treatment of psoriasis; a cooperative clinical trial. *J Invest Dermatol* 1977; **68**:328–335.
3. Bergfeld WF. Histopathologic changes in skin after photochemotherapy. *Cutis* 1977; **20**:504–507.
4. Abel EA, Cox AJ, Farber EM. Epidermal dystrophy and actinic keratoses in psoriasis patients following oral psoralen photochemotherapy (PUVA); follow-up study. *J Am Acad Dermatol* 1982; **7**:333–340.
5. Hashimoto K, Kumakiri M. Colloid-amyloid bodies in PUVA-treated human psoriatic patients. *J Invest Dermatol* 1979; **72**:70–80.
6. Greene I, Cox AJ. Amyloid deposition after psoriasis therapy with psoralen and long-wave ultraviolet light. *Arch Dermatol* 1979; **115**:1200–1202.
7. Rosario R, Mark GJ, Parrish JA, Mihm MC Jr. Histological changes produced in skin by equally erythemogenic doses of UV-A, UV-B, UV-C, and UV-A with psoralens. *Br J Dermatol* 1979; **101**:299–308.
8. Gschnait F, Wolff K, Hönigsmann H, et al. Long-term photochemotherapy; histopathological and immunofluorescence observations in 243 patients. *Br J Dermatol* 1980; **103**:11–22.
9. Zelickson AS, Mottaz JH, Muller SA. Melanocyte changes following PUVA therapy. *J Am Acad Dermatol* 1979; **1**:422–430.
10. Kanerva L, Niemi KM, Lassus A. Hyperpigmentation and hypopigmentation of the skin after longterm PUVA therapy; light and electron microscopic observations on three patients. *J Cutan Pathol* 1981; **8**:199–213.
11. Roenigk HH Jr, Caro WA. Skin cancer in the PUVA-48 cooperative study. *J Am Acad Dermatol* 1981; **4**:319–324.
12. Lassus A, Reunala T, Idänpää-Heikkilä J, Juvakoski T, Salo O. PUVA treatment and skin cancer; a follow-up study. *Acta Dermatovenereol* 1981; **61**:141–145.
13. Stüttgen G. The risk of photochemotherapy. *Int J Dermatol* 1982; **21**:198–202.
14. Grupper C. Tar, ultraviolet light, PUVA, and cancer (editorial). *J Am Acad Dermatol* 1980; **3**:643–646.
15. Stern RS, Thibodeau LA, Kleiner RA, Parrish JA, Fitzpatrick TB. Risk of cutaneous carcinoma in patients treated with oral methoxsalen photochemotherapy for psoriasis. *N Engl J Med* 1979; **300**:809–813.
16. Lobel E, Paver K, King R, LeGuay J, Poyzer K, Wargon O. The relationship of skin cancer to PUVA therapy in Australia. *Aust J Dermatol* 1981; **22**:100–103.
17. Levin DL, Roenigk HH Jr, Caro WA, Lyons M. Histologic, immunofluorescent, and antinuclear antibody findings in PUVA-treated patients. *J Am Acad Dermatol* 1982; **6**:328–333.

18. Kligman AM. Early destructive effect of sunlight on human skin. *JAMA* 1969; **210**:2377–2380.
19. Epstein JH. Phototoxicity and photoallergy in man. *J Am Acad Dermatol* 1983; **8**:141–147.
20. Wolff K, Gschnait F, Hönigsmann H, et al. Oral photochemotherapy; results, follow-up, and pathology. [In] Cox AJ, Jacobs PH, Nall ML, eds. *Psoriasis. Proceedings of the Second International Symposium, Stanford University, 1976*. New York, 1977, pp 300–309.
21. Zelickson AS, Mottaz JH, Zelickson BD, Muller SA. Elastic tissue changes in skin following PUVA therapy. *J Am Acad Dermatol* 1980; **3**:186–192.