

ARSPHENAMINE RESISTANT SYPHILIS

Report of 2 Cases

E. W. NETHERTON, M. D.

The rapid disappearance of the cutaneous lesions of early syphilis and the *Treponema pallidum* from the exudate of moist lesions following the injection of an arsphenamine is one of the most spectacular achievements of modern therapy. The surface lesions almost invariably disappear within two or three weeks after treatment has begun and the darkfield examination usually becomes negative within twelve hours after the initial injection of a potent arsphenamine.

There are, however, rare cases in which the early lesions of syphilis do not heal following the injection of an arsphenamine. In these cases the darkfield examination remains positive even after several injections of arsphenamine. In still more rare cases, the manifestations of acute syphilis do not respond favorably to either the arsphenamines or the heavy metals. Because of this, Moore¹ prefers to designate this type of syphilis as treatment resistant rather than arsphenamine resistant. He states that treatment resistance occurs about once in 500 cases of patients with early syphilis.

During the past two decades numerous cases of arsphenamine resistant syphilis have been reported in the European literature and, more recently, reports of similar cases by American observers have been increasing.

Certain types of late acquired visceral syphilis and of congenital syphilis respond slowly to antisypilitic therapy and failure to attain a complete and permanent reversal of a positive serologic test is not uncommon in acute syphilis; however, these phenomena differ from those of arsphenamine resistant early syphilis. Arsphenamine or treatment resistance is a term used to designate only that type of acute syphilis in which intensive treatment fails to remove promptly and permanently all mucocutaneous manifestations of the disease. The positive proof of resistance is the persistence of *Treponema pallidum* in the lesions in spite of arsphenamine therapy.

In treating resistant early syphilis, the lesions may enlarge and become more numerous in spite of treatment; the first injections may produce partial involution of the lesions, while subsequent injections fail to prevent their recurrence and the appearance of new lesions, or the lesions may heal during arsphenamine therapy but relapses occur when the course of heavy metal is started.

The cause of treatment resistance in early syphilis has not been determined. Most authorities feel that it is due neither to a decrease in the

efficacy of antisyphilitic drugs, nor to the fact that the universal use of arsphenamines has produced a strain of spirochetes resistant to the drug. It is more probable that the cause of arsphenamine resistance is due to some peculiarity of the host—either the host is unable to metabolize antisyphilitic drugs or there is an alteration in the reaction of the host to the infection. There may be a disturbance in body defense mechanism of the host.

Patients with arsphenamine resistant syphilis usually do not tolerate arsphenamine as well as do other individuals and, because of this, some observers have suggested that such patients metabolize arsphenamine differently than the patients with acute syphilis in which the infection responds favorably to the drug. Moore¹ and his coworkers have pointed out that arsphenamine resistance and repeated infectious relapses in spite of treatment are more common in the rare cases of seronegative secondary syphilis and in secondary syphilis where relatively small amounts of reagin are present in the blood.

In arsenoresistant syphilis the eruption is frequently psoriasiform or serpiginous or occurs as seborrheic papules on the face, especially on the nose and about the corners of the mouth. The scales of a psoriasiform syphilid are more oily, larger, less adherent, and of a yellowish gray color, while those of psoriasis are usually smaller, gray, imbricated, and more adherent. A squamous syphilid is more infiltrated and is frequently surrounded by a collarette of loose epithelium. This can be seen in the illustrations.

Although cases of arsphenamine or treatment resistant syphilis are rare, it is extremely important from the standpoint of public health that such cases be recognized, for the potentialities of the spread of the disease due to infectious relapses are exceedingly great. The following two cases of treatment resistant early syphilis have been observed at this Clinic during the past two years.

REPORT OF CASES

Case 1: On January 5, 1937, a married man, 31 years of age, was referred to the Clinic because of a non-pruritic squamous eruption which had been present for approximately twelve weeks. The referring physician stated that, since the patient had been receiving antisyphilitic treatment from another physician but had not experienced any improvement, he had concluded that the lesions probably were those of psoriasis instead of secondary syphilis; however, he did not want to proceed with treatment without a consultation.

The past history was unimportant except that, at the age of 26, the patient had had a small penile lesion which was diagnosed by a physi-

ARSPHENAMINE RESISTANT SYPHILIS

cian as a "hair cut." This lesion disappeared without treatment. He denied having gonorrhea or recent extramarital coitus.

Present Illness: The initial lesion, which was a small ulcerated papule on the prepuce, appeared about three months prior to our first examination. Within a short time, small red spots on the arms were noticed and he consulted a physician who, after finding that the serology of the blood was weakly positive (2+), instituted antisyphilitic therapy. Treatment consisted of a course of eight intravenous injections followed by three intramuscular injections. We did not ascertain what type of arsenical was used but assumed that it was neoarsphenamine. The drug was administered with a syringe and needle and at the time of each injection the patient noticed a strong ether-like odor. The initial lesions almost disappeared following the first intravenous injection but again enlarged as treatment was continued. In addition, new lesions continued to appear on the extremities and some of the older ones enlarged to form red, scaly areas. Many lesions had developed on the forehead, face, neck, and upper and lower extremities while the trunk had remained clear. There were infiltrated papules on each palm. These eruptions were limited to the genitalia and the areas just mentioned. They consisted of papules of various sizes which roughly simulated the squamous lesions of psoriasis, differing in that the scales were large, oily, and more crustaceous. The bases of the large lesions were duller red and more infiltrated than those of psoriasis. On removal of the scales, small hemorrhagic points did not appear on the surface of the papules. As can be seen in figure 1, the scales or thin crustations were thicker at the central portion of the lesions and in many instances they failed to extend to the extreme margins of the papules. Likewise, the dull red periphery of many of the papules was surrounded by a collarette of loose epithelium. There were several dull red, smooth areas of nodular infiltration on the forehead, upper lip, and chin. There were no lesions in the mouth (Fig. 2).

There was a large, moist, infiltrated papule on the prepuce just to the left of the midline. The surface of the lesion was fissured but there was no destruction of tissue such as is seen in a chancroidal infection. The regional lymph nodes were discrete and enlarged.

Darkfield examination of material obtained from the moist lesion on the prepuce was positive for *Treponema pallidum*. Both the blood Wassermann and Kahn tests gave strongly positive reactions (4+).

A diagnosis of arsphenamine resistant syphilis was made and intensive antisyphilitic treatment was recommended. The treatment was to be regular, continuous, and prolonged, and to consist of alternating courses of an arsenical and a heavy metal in accordance with the recommendations of the Cooperative Clinical Group² for the treatment of

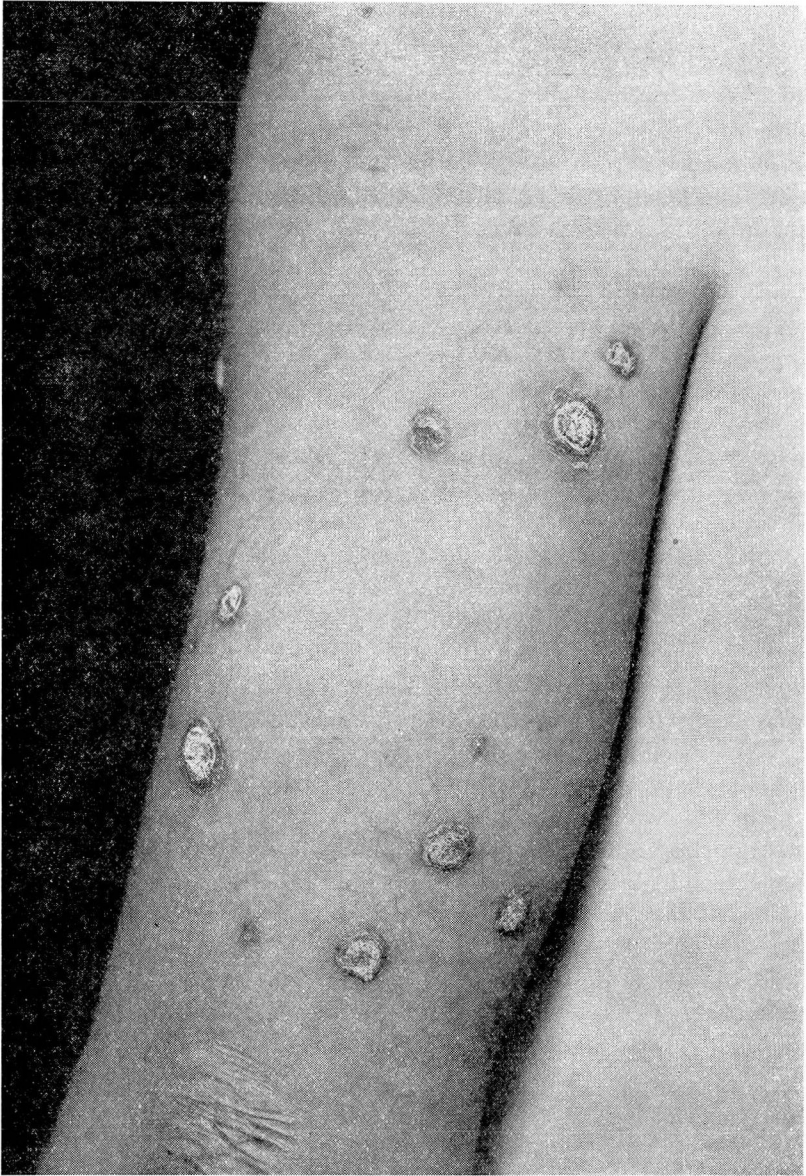

FIGURE 1, CASE 1: Psoriasiform syphilids. Note the collarette of loose epithelium at periphery of the lesions.

early syphilis. The arsenical which had been administered (probably neoarsphenamine) was ineffective; therefore, mapharsen was selected as the arsenical to be used and the heavy metal therapy was to consist of intramuscular injections of bismuth salicylate.

On February 25, 1938, 13 months after our first examination, the

ARSPHENAMINE RESISTANT SYPHILIS

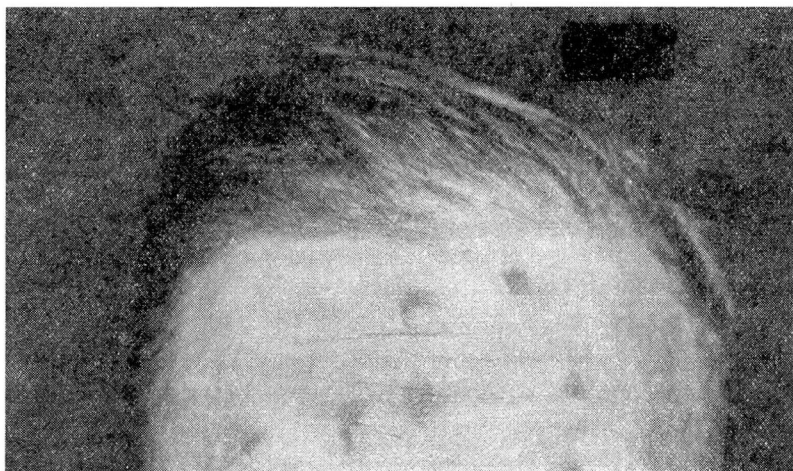

FIGURE 2, CASE 1: Dull red, smooth cutaneous nodules on forehead. There were similar lesions on the upper lip and chin.

referring physician reported that the eruption had disappeared after a few injections of mapharsen and that there had been no mucocutaneous relapses. A recent report on the blood serology was not available, but the patient was still under treatment and was cooperating satisfactorily.

Summary: This patient had psoriasiform secondary syphilis which was resistant to neoarsphenamine. Lesions continued to develop even though eight treatments had been administered. A conclusive proof that the patient had an arsphenamine resistant syphilis was the demonstration at the conclusion of neoarsphenamine therapy of motile *Treponema pallidum* in the serum from the penile lesion. The infection was resistant to one member of the arsphenamine group, namely, neoarsphenamine; however, the lesions healed under mapharsen therapy.

Case 2: An unmarried man, 59 years of age, came to the Clinic on January 20, 1938, complaining of a non-pruritic eruption on the hands, right foot, face, and trunk.

The past history was irrelevant.

Present Illness: In August, 1936, seventeen months previously, the patient had sustained an injury to the right hand. This was a superficial puncture of the skin on the dorsal surface of the right hand near the base of the thumb. Within a week, the base of the wound became indurated and a serous exude could be obtained from its surface. There was no acute cellulitis. In a few days the right epitrochlear lymph gland become enlarged. He then consulted a physician who thought the indurated lesion on the hand was an extragenital chancre. A dark-field examination was made on three different occasions and at the third examination it was positive for *Treponema pallidum*.

Antisymphilitic treatment was started and a few hours following the administration of the initial injection of neoarsphenamine a generalized pruritus developed but this disappeared the following day. Three days later, he received another injection of neoarsphenamine and that night the ankles and eyelids became edematous and the generalized pruritus was intense. The edema and itching disappeared within two days and later a third injection of neoarsphenamine produced a similar but more mild reaction. Since neoarsphenamine was not tolerated, intravenous therapy was discontinued and treatment was changed to intramuscular injections of bismuth. He had received 40 injections of bismuth since arsenical therapy has been discontinued.

A few days following the first injection of neoarsphenamine, dull red, scaly areas appeared on the tips of the middle and ring fingers of the right hand. The initial lesion on the hand gradually disappeared, but the lesions on the fingers enlarged and extended to involve the respective nail folds and nail beds, causing the nails to become friable, rough, and broken (syphilitic onychia). Practically the whole circumference of the distal half of each finger became involved by painless, non-pruritic, dull red, scaly, infiltrated plaques (Fig. 3). Several attempts had been made to find a fungus on the scales and friable nails. Roentgen therapy and topical applications failed to be beneficial. Several blood Wassermann tests had been made during the preceding year and all had been reported as negative.

The eruption remained limited to the right middle and ring fingers until October, 1937, when red spots began to appear on the dorsal surface of both hands, on the flexoral surface of the right wrist, and palm, on the palmar and lateral surfaces of the right thumb, on the right foot, the trunk, face, and neck. Recently, a large, moist, gray patch had developed on the dorsal surface of the tongue.

When this patient came under our observation, there was a large, scaly, infiltrated, dull red, irregular plaque on the dorsal surface of the right hand. It extended laterally over the ulnar surface of the hand to involve a portion of the palm. A similar but more infiltrated serpiginous plaque involved the flexoral surface of the right wrist and extended to the thenar and hypothenar portions of the palm (Fig. 4). The radial side of the right wrist and right thumb were involved by the same plaque. The right middle and ring fingers were involved by a similar eruption, particularly their distal portions. Both nails were rough and broken, and their folds were red, infiltrated, and scaly. There was no suppuration beneath the nail folds.

The infiltration was a definite characteristic of the lesions and it was especially noticeable in the lesion on the flexoral surface of the wrist.

ARSPHENAMINE RESISTANT SYPHILIS

The scales were large, oily, and adherent. There was a collarette of loose epidermis at some portions of the periphery of each lesion.

There was a similar squamous lesion on the dorsal surface of the right foot at the base of the large toe and the one adjacent to it. The plaque also involved these toes. The soles were free of lesions.

There were large, flat, scaly papules on the back and upper extremities.

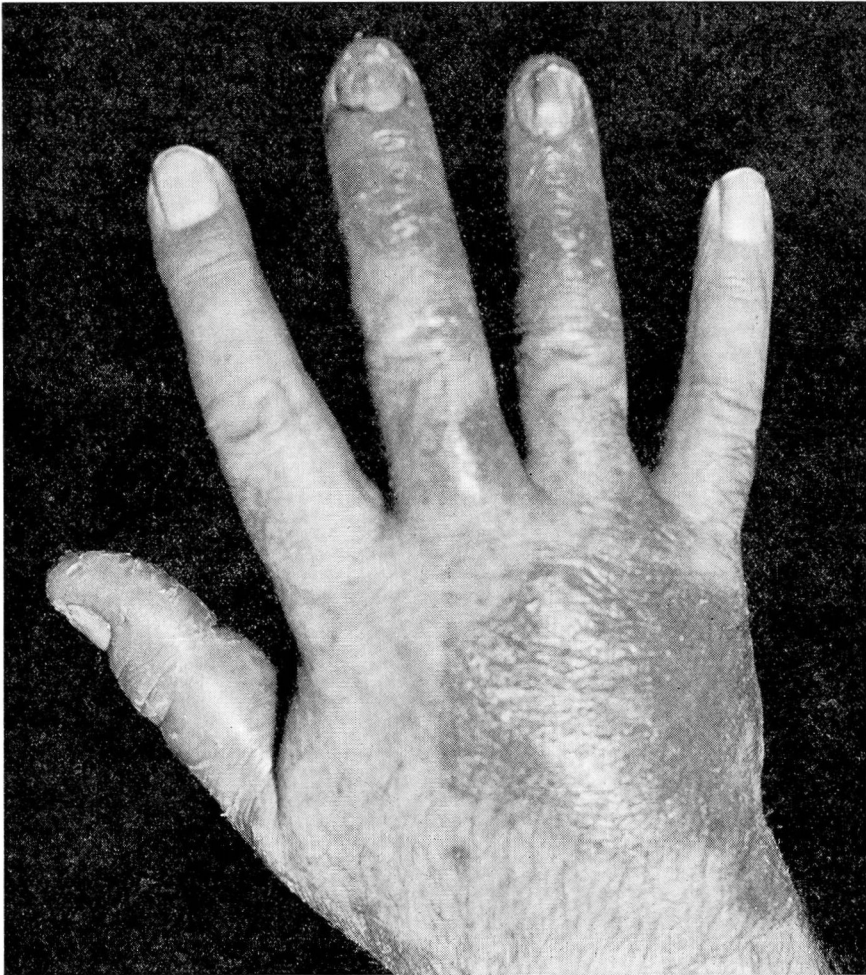

FIGURE 3, CASE 2: Large, squamous plaque on dorsal surface of the hand. Syphilitic onychia of nails of ring and middle fingers.

The scales were large, oily, and loosely adherent. Each lesion was infiltrated. There were a few dull red, smooth, cutaneous nodules on the face, there was one on the upper lip and another near the right corner of the mouth as can be seen in figure 5. There was a large, gray,

moist patch on the dorsal surface of the tongue. There was no bismuth line on the gums and there were no signs of a bismuth stomatitis.

The blood Wassermann and Kahn tests gave strongly positive reactions (4+) and a darkfield examination of serum from the patch on the tongue was positive for *Treponema pallidum*.

A biopsy of one of the papules on the back showed a chronic inflam-

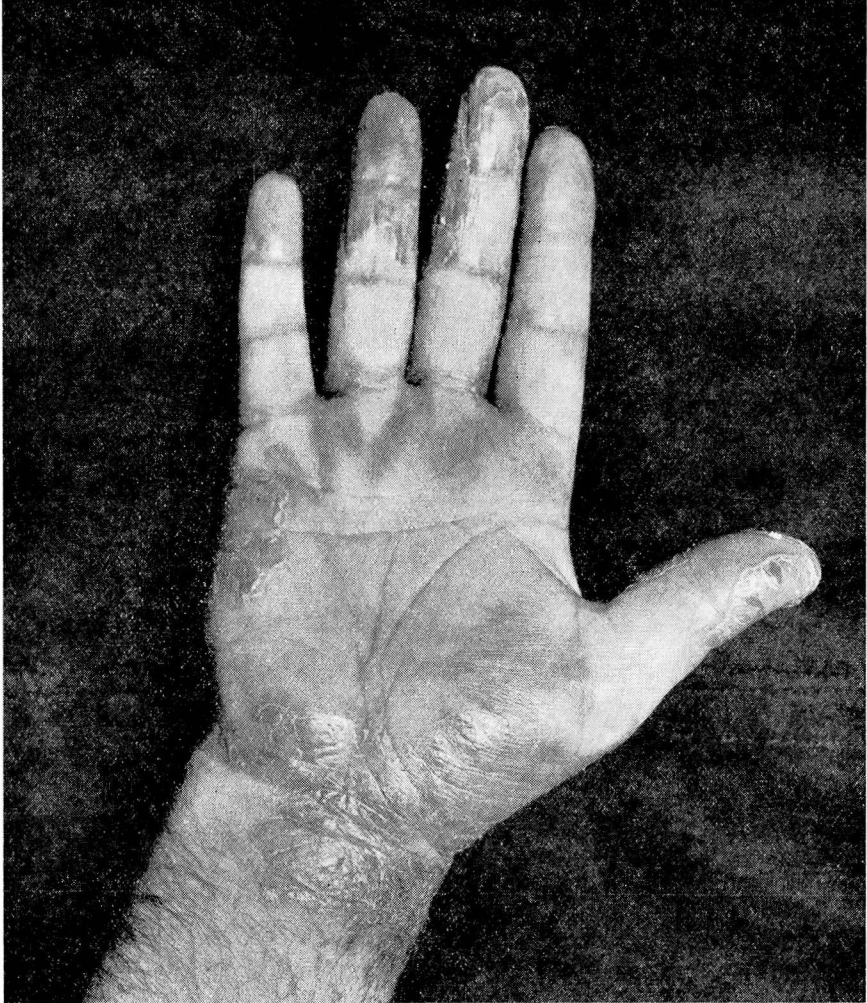

FIGURE 4, CASE 2: Infiltrated squamous plaque on wrist and palm. Note collarette of loose epithelium at margins of the lesions.

matory perivascular lymphocytic infiltration and fixed tissue proliferation in the corium which was compatible with the diagnosis of syphilis.

A diagnosis of treatment resistant early syphilis was made and treatment was begun. Since neoarsphenamine was poorly tolerated, treat-

ARSPHENAMINE RESISTANT SYPHILIS

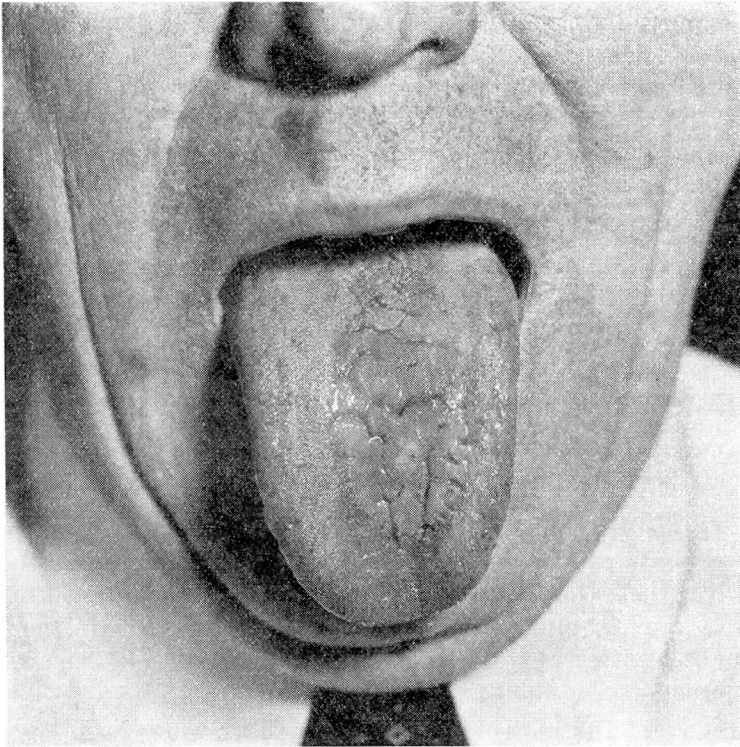


FIGURE 5, CASE 2: Large mucous patch on dorsum of tongue. Note smooth cutaneous nodule on upper lip and one near right corner of the mouth.

ment was to consist of courses of mapharsen alternating with courses of mercury. After two injections of mapharsen, a total of 0.08 gm., which were given four days apart, the infiltration in the lesions was less and the patient stated that he felt better than he had for a long while.

Treatment was continued by the patient's physician and at the end of two months the lesion on the tongue and those on the face, trunk, and arms had disappeared; however, there was still some redness and infiltration of those on the right hand and wrist. Treatment was continued with 0.06 gm. mapharsen every five days until he had taken 15 injections and then, contrary to previous recommendations, his physician advised that he take mixed treatment in the form of pills. At this time there was some redness of the lesions on the hands although infiltration was slight.

Within two weeks there was a recurrence of the infiltration in the reddened areas on the right hand and large, dull red, infiltrated plaques and papules appeared on the sole of each foot. The blood Wassermann and Kahn tests still gave strongly positive reactions. Although most of the cutaneous lesions had disappeared following fifteen injections of

mapharsen, recurrences developed rapidly after arsenical medication was discontinued. The patient tolerated mapharsen better than neoarsphenamine, but he complained of having some nausea and of feeling listless a few hours after each treatment. Because of this he was reluctant to have further intravenous medication; however, it was obvious that treatment had so far failed to produce complete healing of the lesions and had not prevented cutaneous relapses when treatment was stopped.

Arsphenamine therapy was begun and following three injections or a total of 1.0 gm., there was marked improvement. The dose of arsphenamine was increased to 0.5 and 0.6 gm. and a total of nine injections were given. The response to arsphenamine therapy continued to be satisfactory. He frequently was troubled with nausea and vomiting two or three hours after receiving an injection of arsphenamine, but there were no serious reactions due to treatment.

This patient lives out of the city and he has continued treatment under the supervision of a physician near his home. Up to the present time he has had six injections of bismuth. He has been requested to return for more arsphenamine therapy or to arrange for such treatment near his home. In a recent letter he states, "My hands, aside from a feeling of tenderness, seem almost as good as new."

Summary: This patient had an extragenital chancre in August, 1936. The diagnosis was made by a darkfield examination and during the seronegative primary stage of the infection. The primary lesion disappeared following three injections of neoarsphenamine. This drug was tolerated poorly by the patient so treatment was continued with intramuscular injections of bismuth. Forty injections were given during the first 16 months of the infection. Shortly after the initial neoarsphenamine therapy and at about the time treatment with bismuth was started, a red, scaly eruption appeared on the tips of the middle and ring fingers of the right hand. These lesions enlarged until the distal half of each finger was involved. These lesions continued to persist in spite of various therapeutic procedures. During the first year, several blood Wassermann tests were reported as negative. Fourteen months later, papulosquamous psoriasiform syphilis appeared on the upper extremities, feet, trunk, face, and neck; a large mucous patch also developed on the dorsum of the tongue. *S. pallida* were found by darkfield examination of material from the lesion on the tongue and the blood serology had become strongly positive.

Bismuth therapy had failed to prevent the development of clinical and serologic manifestations of syphilis. Fifteen injections of mapharsen, most of which were 0.06 gm. each, failed to produce complete or permanent disappearance of the lesions when the interval between

ARSPHENAMINE RESISTANT SYPHILIS

treatment was decreased to five days. Arsphenamine was effective and the lesions have not returned during the past six weeks while the patient has been receiving bismuth therapy. Further treatment and observation is necessary before the value of arsphenamine therapy can be determined. It may finally be necessary to give this patient fever therapy as an adjunct to the standard treatment procedures now being used.

DISCUSSION

In arsphenamine resistant syphilis, the resistance is often specific for a single member of the arsphenamine group. If the resistance is to all of the arsphenamines, the lesions will heal after the administration of bismuth or mercury. Cases of early syphilis which were resistant to arsphenamine, bismuth, and mercury have been reported but they are very rare. In Case 1 the infection was resistant to neoarsphenamine but responded favorably to mapharsen and bismuth, while in Case 2, 40 injections of bismuth failed to prevent the appearance of mucocutaneous lesions and mapharsen failed to heal all the lesions and to prevent relapses when the drug was discontinued. However, the infection responded favorably to arsphenamine. In both cases the *Treponema pallidum* was demonstrated in moist lesions following the administration of standard arsenicals in amounts more than sufficient to cause the complete disappearance of the clinical manifestations in the average case of acute syphilis. The second case has not been under observation long enough to be certain that more drastic measures, such as fever therapy, will not be necessary to achieve satisfactory results.

In the management of patients with arsphenamine resistant syphilis the treatment must be intensified. The type of arsenical should be changed and if necessary the dose should be increased and the interval between treatments should be shortened. Treatment should be continuous and regular. If response to intensified treatment is satisfactory, the intensity of the therapeutic attack may be gradually decreased but treatment should be continued without rest periods until the serology of the blood and spinal fluid have become and remained permanent for at least one year. If relapses continue to occur, the use of drugs should be discontinued and fever therapy with induced malaria should be given. As soon as the fever therapy has been terminated, treatment with standard methods should again be started. Following fever therapy the lesions will usually heal promptly and relapses will not occur under treatment which previously had been ineffective.

REFERENCES

1. Moore, Joseph Earle: *The Modern Treatment of Syphilis*, Charles C. Thomas, 1933, Springfield, Illinois.
2. Stokes, J. H., Cole, H. N., Moore, J. E., O'Leary, P. A., Wile, W. G., Parron, T., Vanderlehr, R. A., and Usilton, L. G.: Standard treatment procedure in early syphilis, J.A.M.A., 102:1267-1272, (April 21) 1934.