

CLINICAL APPLICATION OF THOROTRAST MYELOGRAPHY AND SUBSEQUENT FORCED DRAINAGE*

Report of a Case

WM. A. NOSIK, M. D.

In a high percentage of surgical lesions of the spinal cord, no changes in the bony structure are demonstrable by the ordinary methods of roentgen examination, even when the clinical findings are suggestive of a certain cord level. In the interest of an accurate preoperative diagnosis, so essential to the surgeon, it is necessary to resort to the use of certain substances which, when injected intraspinally and followed by roentgen examination, will outline the offending lesion and establish not only its location but often its character.

The radio-opaque oils, particularly lipiodol, have been favored for clinical usage, but not without certain reservations as to their adequacy as diagnostic media. It is obvious that they do not meet the requirements of the ideal intraspinal agent, namely: (1) that it should be non-toxic, (2) of sufficient atomic weight to cast a clear-cut shadow, (3) non-irritating, (4) miscible with the spinal fluid, and (5) readily eliminated (Coe, Otell and Hedley¹).

Because it most nearly fulfilled the qualifications of the ideal medium, thorotrast attracted much attention, particularly since the work of Schoenfeld and Freeman², and Twining and Rowbotham³ in their application of this agent to encephalography and ventriculography with apparently good results but with evidence of meningeal irritation. In spite of the mild irritative reaction that attends the introduction of thorotrast, like any other foreign body, into the subarachnoidal space and also the fact that the body is forced to dispose of the injected material through its own agencies, this substance gave such a nicety of cerebrospinal anatomical detail that it offered quite a temptation as a potential diagnostic aid. Realizing that it is desirable to remove any foreign substance which has been introduced into the body as a diagnostic aid after it has served that purpose, it occurred to the author that, because of its miscibility with cerebrospinal fluid, much of a subarachnoidal injection of thorotrast could possibly be removed by using the forced drainage method suggested by Kubie and Retan⁴. With Mortensen, a series of experiments with dogs and monkeys was begun to test the practicability of such a procedure. These experiments are discussed in a previous publication⁵. It was observed at once that not only could the thorotrast be almost entirely removed but that the degree of reaction to this substance was brought to a minimum; likewise, it was felt quite likely that the drainage could be equally as effective in the elimination

*Abstract of thesis which was awarded the William E. Lower Fellowship Thesis Prize for 1938.

THOROTRAST MYELOGRAPHY AND SUBSEQUENT FORCED DRAINAGE

of both the thorium dioxide and the reaction in the human subject. Accordingly, the procedure was used and the theoretical considerations established in practical form.

In the case reported the basic principles were applied.

REPORT OF CASE

The patient, a white girl of 24 years, who complained of difficulty in walking was seen at the Cleveland Clinic on March 1, 1938. The patient first became aware of slight spasticity of her legs one morning in September, 1933. She began to have pain of sharp, piercing nature, shooting from the gluteal regions to the backs of the legs. The pain gradually subsided to a mild chronic ache. Coughing, sneezing, and bending would exaggerate her discomfort. Two weeks previous to examination the old sharp pain with the spasticity of the legs recurred and progressed until the patient sought relief.

Past Medical History: Tonsillitis and tonsillectomy, 1930.

Physical Examination: The patient was a well developed and nourished white girl who walked with guarded gait. General examination revealed no evidences of pathological changes.

The pertinent neurological findings were: Bilateral hyperactive patellar reflexes, absent lower abdominals, questionable Babinski bilaterally, perception to both touch and pain decreased below the eleventh dorsal segment, moderate spasticity of the legs.

The clinical impression was that of an irritative lesion of the lower dorsal cord, possibly a ruptured nucleus pulposus.

Laboratory examinations of the blood serology, chemistry and counts gave entirely normal findings. Urinalysis presented no evidence of renal changes. Roentgenograms of the lumbar spine were negative. Lumbar puncture was done with no evidence of a block. Examination of the spinal fluid revealed 0 cells, negative Pandy reaction, negative gold sol, negative Wassermann reaction, and 30 mg. protein.

Because of the strong suspicion of a surgical lesion of the spinal cord, thorotrast myelography was advised by Dr. W. James Gardner, with whom these investigations are being continued. This was carried out on March 12, 1938, when 10 cc. of thorotrast were slowly injected into the lumbar sac with the patient reclining in a 30 degree angle. Fluoroscopic examination revealed a normal canal outline. Roentgenograms were made with the injection mass in the caudal sac (Fig. 1). This was then allowed to diffuse upward by shifting the level of the patient and films were made at the new level after observing it with the fluoroscope (Fig. 3). The roentgenograms revealed no evidence of a pathological process.

The patient was then returned to her room and a drainage needle

inserted into the lumbar canal. An intravenous injection of 1500 cc. of 0.45 per cent hypotonic saline solution was made and the thorotrast-containing fluid collected. The drainage of the cerebrospinal fluid was markedly increased due to the decrease of the osmotic tension of the blood. A total return of 128 cc. was obtained in one hour which quantitatively contained 90 per cent of the thorotrast injected (Figs. 2, 4).* The patient complained only of slight headache at the completion of the procedure. The following day was attended by a moderately severe headache which was controlled with ice caps and codeine.

The patient was discharged on March 15, 1938, in good condition, the neurological signs being unchanged. A recheck examination on March 31, 1938, revealed a definite improvement in the neurological picture.

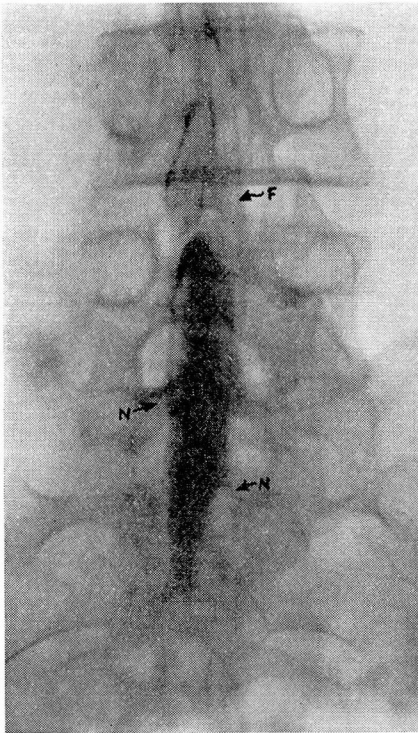


FIGURE 1: Visualization of the caudal sac with 10 cc. thorotrast. The substance had been allowed to diffuse widely before the roentgenogram was made. Fibers of the cauda equina (F) and the extension of the subarachnoid distension along the nerves are seen (N).

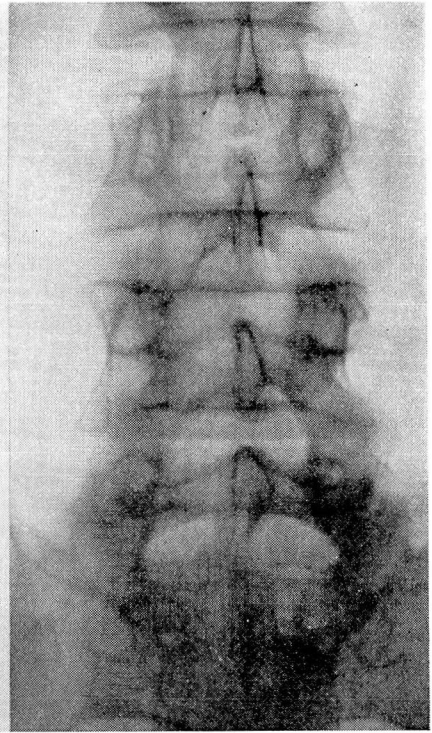


FIGURE 2: Roentgenogram made after forced spinal drainage with recovery of 90 per cent of the injected thorotrast.

Comment: There has been presented here a case in which thorotrast myelography was used, employing a new technic. This procedure

* This analysis was made by Dr. D. Roy McCullagh.

THOROTRAST MYELOGRAPHY AND SUBSEQUENT FORCED DRAINAGE

represents a combination of experimentally and clinically proved procedures, i.e., the visualization of bodily structures with thorotrast and the forced spinal drainage of Kubie and Retan⁴. By the use of this method it was possible to visualize the spinal canal, prove the absence of pathology of surgical nature, and remove 90 per cent of the injected radio-opaque diagnostic medium, leaving the canal free of an otherwise permanent foreign body mass. The radio-activity of the thorotrast

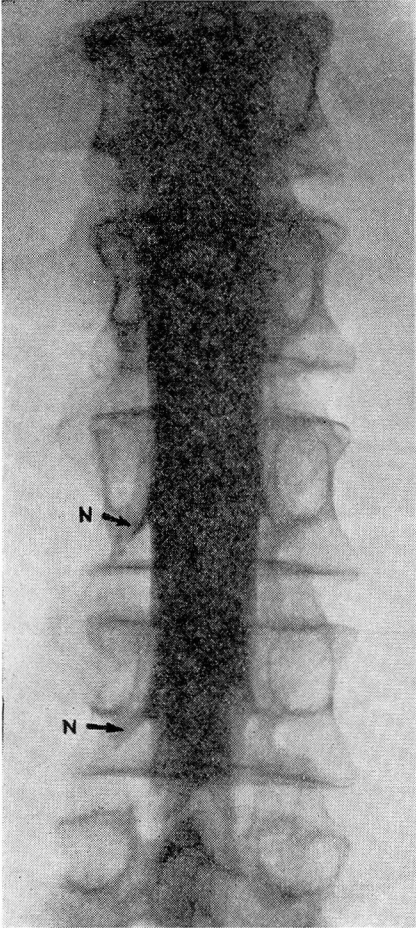


FIGURE 3: Injection-mass of 10 cc. of thorotrast taken during fluoroscopic examination of thoraco-lumbar region to demonstrate its control by gravity. N represents the perineural extension of the subarachnoid.

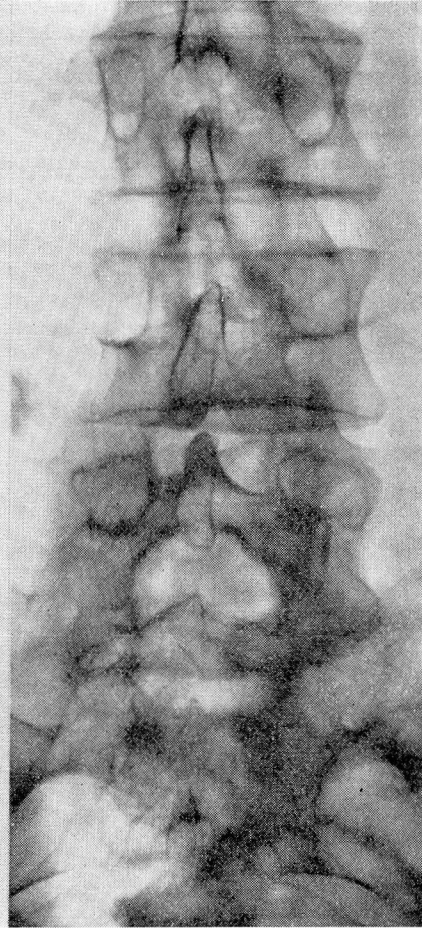


FIGURE 4: Roentgenogram made after drainage of subarachnoid space. The efficacy of the drainage is obvious.

dissipated in the body was calculated and found to be 0.0108×10^{-6} gm. radium equivalent, an amount far below that reported as the minimal toxic figure. By the use of this method the tenets of the ideal intraspinal

diagnostic agent have been upheld to a greater degree than was previously possible.

From the nature of the drainage, it is obvious that this diagnostic procedure should be applied only to cases with partial or non-obstructive lesions in the canal—the very lesions which present the greatest diagnostic problems and the most favorable surgical possibilities. With more experience, highly satisfactory myelograms and possibly even encephalograms might be made. The application of forced cerebrospinal fluid drainage to the removal of diagnostic agents of suitable physical nature is presented here.

CONCLUSIONS

1. A case is presented in which myelography with thorotrast and its subsequent removal by forced drainage was successfully applied.

2. One of our first applications of forced cerebrospinal fluid drainage to the removal of a diagnostic substance of suitable physical nature from the patent subarachnoidal space of man is presented here and is considered to be of basic importance.

3. A recovery of 90 per cent of the injected colloidal thorotrast was obtained after forced drainage.

4. The residual thorotrast represents a radium equivalent of 0.0108×10^{-6} gm., an amount far below the minimal toxic level.

I wish to acknowledge the kind assistance and suggestions of Dr. W. James Gardner of the Neurosurgical Department whose patient is presented here, and members of the Department of Roentgenology under Dr. B. H. Nichols, namely Dr. J. C. Root and Dr. C. R. Hughes.

REFERENCES

1. Coe, F. O., Otell, L. S. and Hedley, O. F.: Thorotrast encephalography by cisterna puncture, *Med. Ann. Dist. Columbia*, 2:277-279, (December) 1933.
2. Schoenfeld, H. H. and Freeman, W.: Ventriculography and encephalography by means of thorium dioxide solution, *Med. Ann. District of Columbia*, 2:279-282, (December) 1933.
3. Twining, E. W. and Rowbotham, C. F.: Ventriculography by opaque injection (thorotrast—ThO₂ preparation), *Lancet*, 2:122-125, (July 20) 1935.
4. Kubie, L. S. and Retan, G. M.: Forced drainage of the cerebrospinal fluid, *J.A.M.A.*, 101:354-358, (July 29) 1933.
5. Nösik, W. A. and Mortensen, O. A.: Myelography with thorotrast and subsequent removal by forced drainage; an experimental study, *Am. J. Roentgenol.*, 39:727-730, (May) 1938.