

TRANSPLANTATION OF ENDOCRINE TISSUE

Preliminary Report on Experimental Work

WILLIAM E. LOWER, M.D.

When an endocrine gland is destroyed by disease or operation, treatment, in most cases, comprises substitutional therapy administered orally or by injection and this generally must be continued for the remainder of the patient's life. In these cases, substitution of a functional gland is the desideratum for which everyone hopes.

The successful transplantation of tissues, however, is not a simple matter and depends upon a large number of factors, some of which concern the graft itself and others the host. To any graft, for example, a host may set up a natural defense reaction to injury or the introduction of a foreign body. Other factors of great importance are related to proper vascularization of a graft and the age, time, and relation of the transplant to the host. In considering the relation of the transplant to the host, there arise such questions as the auto-, homo-, or hetero-plastic character of the tissues and the genetic compatibility between tissue and host. Loeb and Wright¹ have stressed the importance of considering the genetic constitution of both donor and recipient.

Studies of sub-human animal grafting have almost invariably shown that hetero-transplantation, that is, transplantation between different species, is unsuccessful. Such studies lead one to regard with caution



FIGURE 1: Host: Castrated male rat. Ear in foreground shows testis from rat one day old, transplanted four months previously. Ear in background shows prominence made by seminal vesicle grafted simultaneously with testis.

TRANSPLANTATION OF ENDOCRINE TISSUE

the announcement that hetero-glandular grafting in human beings has brought favorable returns (Voronoff²).

Homoplastic grafting in human subjects is a more logical procedure than hetero-grafting. The preliminary studies of Stone, Owing, and Gey and more recently those of Gey³ who used the tissue culture technic, offer considerable promise. Gey has reported that more than one-third of a series of 16 patients with marked parathyroid tetany are well from 2 to 6 years after homologous grafting with tissue cultures.

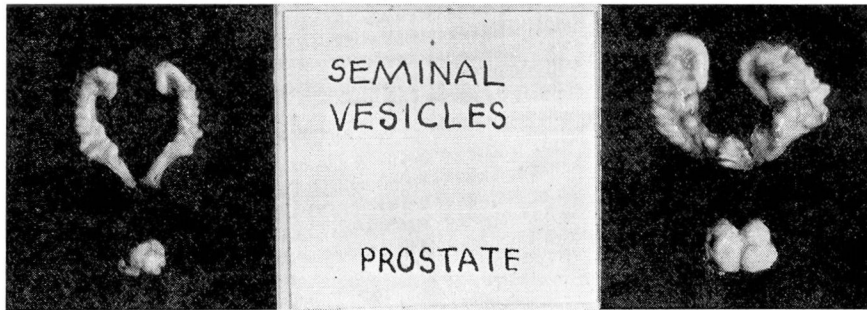


FIGURE 2: A: From a castrated male rat.

FIGURE 2: B: From a castrated male rat with a functional testis graft in the ear. Tissue from a rat one day old had been grafted two months before photograph was taken.

In well documented works (Werner⁴), the scanty literature dealing with successful transplantations in human subjects attests to the relatively little knowledge there is about this subject. On the other hand, there is a vast literature on the subject of transplantations in sub-human animal forms. Much information has derived from studies on transplantations of glands in rats. The studies to be reported here have been made on the rat, the technical work and the follow-up studies having been done by Eugene and Elizabeth Cutuly.

In our work, the first factor to be considered was determination of a suitable site for grafting of the glands. The tip of the ear seemed satisfactory because it readily afforded a good supply of blood and because the growth of a transplant could be watched from day to day.

Grafting to the ear is a comparatively simple procedure. About midway between the tip and the base of the dorsal side of the ear a short incision is made through the skin. The blades of scissors are inserted through this incision into the subcutaneous tissues and spread apart gently a number of times until a subcutaneous pocket has been formed. Tissue to be grafted is inserted through the opening of this pocket and gently pressed toward the tip of the ear. Sutures are not needed to keep

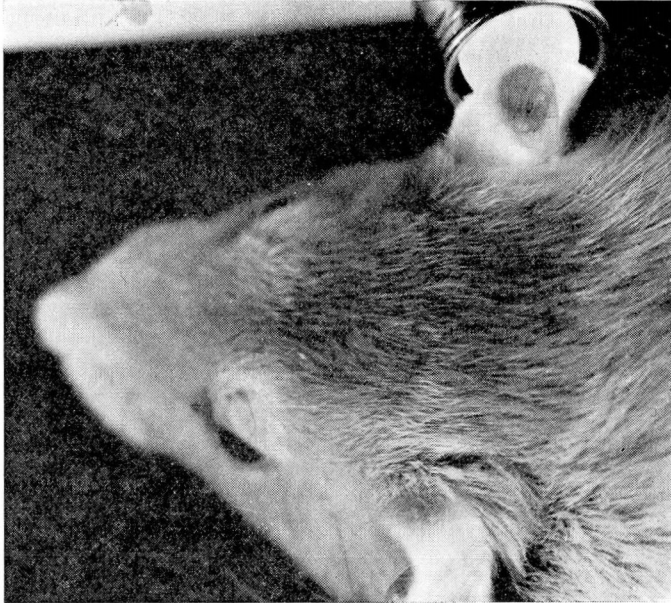


FIGURE 3: Host: Castrated male rat. Seminal vesicle graft in ear transilluminated to show secretion (light areas.) Flashlight bulb in background. This graft was stimulated by hormone from a testicular graft in the other ear.

the grafts in place or to close the slit in the skin. Usually, there is a little hemorrhage around the graft, but this does not seem to be injurious.

By this method, we have made more than 100 grafts into the ears of rats. All experiments in which adult tissues were used as transplantation material gave negative results. We have, however, had remarkable success with grafts from newly-born donor rats. The following tissues have been grafted: testis, prostate, seminal vesicle, pituitary, ovary, adrenal, thyro-parathyroid, and pancreas.

Testis grafts have taken well both in castrated hosts (30 out of 40 cases) and in normal hosts (20 out of 30 cases).

Accessory sexual organs, such as seminal vesicles, have grown in the presence of testicular male hormone (3 cases out of 3) but have uniformly failed to grow in castrated animals (10 cases).

Adrenal grafts have also uniformly failed to take in normal animals, but one adrenalectomized animal, bearing a homoplastic adrenal graft in the ear, is still alive more than one month after adrenalectomy.

Two thyro-parathyroid grafts have taken in normal animals.

In six cases of ovarian grafts, distinct nodules have formed at the site of transplantation, but where the hosts are spayed females, these nodules have apparently not been functional, as the spayed animals have not yet shown estrous vaginal smears.

TRANSPLANTATION OF ENDOCRINE TISSUE

Our results with transplants of the pituitary and pancreas are at present indefinite.

At the present time, we are interested primarily in reporting some of the results obtained with testis grafts.

Testes which have been grafted to the ears of castrated rats (Fig. 1) develop and produce male hormone, as judged by the return of the host's atrophied accessory organs toward a normal condition (Fig. 2), or by stimulation of grafted accessory sexual tissue (Fig. 3). Since male hormone is elaborated by the interstitial component of the testes, it would be expected that the graft seen in figure 1 would possess normal interstitial cells. This is confirmed histologically in figure 4. This experiment establishes the fact that a testis grafted in a subcutaneous pocket in the ear will produce sufficient male hormone to stimulate the seminal vesicles and prostate.

It is known that testes transplanted to other subcutaneous sites, as well

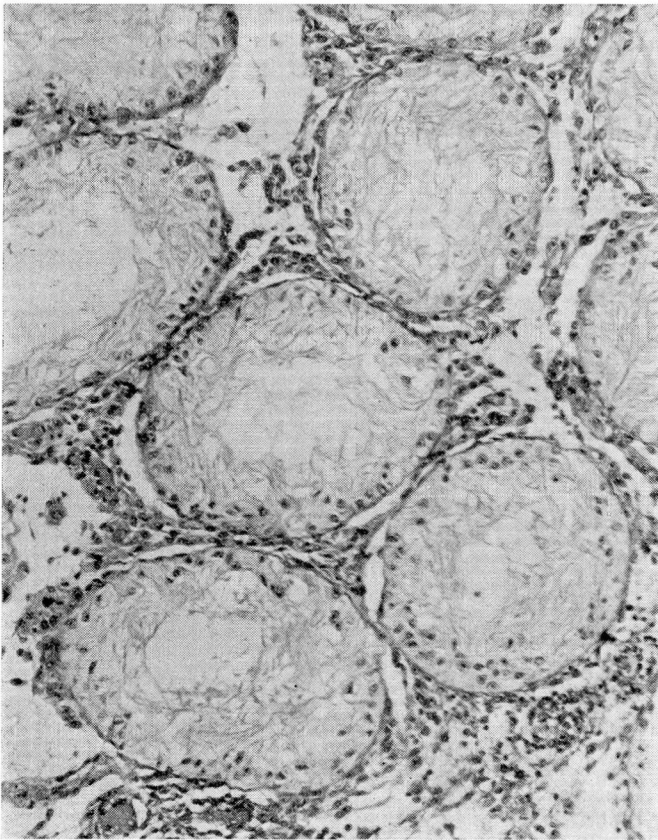


FIGURE 4: Testis from rat one day old taken from ear of a castrated host four months after transplantation.

as those transplanted to the scrotum, also may become functional. Scrotal grafts of testes differ from subcutaneous grafts in that the former may produce mature spermatozoa, as well as functional interstitial cells. Testes transplanted subcutaneously or intraperitoneally have never been known to develop spermatozoa (Moore⁵). This brings up one of the fundamental concepts concerning testicular physiology.

In most mammals, a scrotum is absolutely essential to spermatogenesis. Perhaps it would be more accurate to say that it is the thermoregulation effected by the scrotum which is essential to spermatogenesis. There is some evidence, in fact, which indicates that spermatozoa may develop in testicular tissue growing outside the scrotum—in the anterior chamber of the eye (Turner⁶). However, it was shown in these studies that the temperature of the anterior chamber of the eye is quite similar to that which obtains in the scrotum. It is hoped that the tip of the ear, too, may in some way be made to provide testis grafts with an environment favorable to spermatogenesis. While this has not been possible thus far, it may be that grafts transplanted for periods longer than four to six months will show some activity of the germ cells. Studies to determine this question are in progress.*

SUMMARY

The material presented here is preliminary. Thus far it has been our purpose to develop a technic which will yield consistently good returns. When this has been accomplished, data will have accumulated which can be used as a standard for future studies. It is our plan to study in greater detail factors which are concerned in the successful or unsuccessful incorporation of grafted endocrine tissue in related and unrelated hosts. It is hoped that the results of our investigations will help in the understanding of principles which may apply to the problem of transplantation in human beings.

* There is some recent evidence which indicates that some germ cell development can occur in testis tissue grafted in the ear. Microscopic examination of a testis from a newborn rat grafted to the ear and removed several months later revealed the presence of spermatogonia and primary spermatocytes in the tubules.

REFERENCES

1. Loeb, L. and Wright, S.: Transplantation and individuality differentials in inbred families of guinea pigs, *Am. J. Path.*, 3:251-283, (May) 1927.
2. Voronoff, S.: Results followed up for 20 years after grafting of the thyroid in cases of myxedematous cretinism, *Bull. Soc. de Path. Comparé (Paris)* No. 492, (October) 1937.
3. Gey, G. O.: Some problems in the maintenance of tissue cultures of endocrine organs to be used for transplantation purposes in cases of specific endocrine deficiency, *Anat. Rec.*, 70:30, (Suppl.), (March) 1938.
4. Werner, A. A.: *Endocrinology. Clinical Application and Treatment*, Lea and Febiger. Philadelphia, 1937.
5. Moore, C. R.: *Sex and Internal Secretions*, Williams & Wilkins, Baltimore. Chapter VII, 1932.
6. Turner, C. D.: Intra-ocular homotransplantation of prepuberal testes in the rat, *Anat. Rec.*, 70:80 (Suppl.), (March) 1938.