

## SYMPTOMATOLOGY OF RIGHT TEMPORAL LOBE LESIONS

LOUIS J. KARNOSH, M. D.

The right temporal lobe has a paucity of known physiological centers, and lesions in this area may grow to extensive proportions with impunity. Not until perversions of contiguous functions occur do reliable diagnostic phenomena present themselves to the clinician. Frequently no intracranial pathology is suspected until the patient is overwhelmed by the generalized symptoms of increased intracranial pressure. Tumors of the right temporal lobe are imposters, frequently simulating lesions of the frontal lobe, of the ipsilateral and the contralateral cerebellar structures and of the suprasellar region. Moreover, the few focal symptoms referred to the right temporal lobe have not been clearly elucidated as being irritative phenomena on the one hand and ablation signs on the other.

To add to the confusion, several writers have discussed the two temporal lobes indiscriminately, disregarding the fact that the left lobe is the site of internal language which generally yields a rich symptomatology whenever it is assaulted by disease. Thus, Rowe<sup>1</sup> reviews 52 cases from Frazier's clinic, stating that visual field disturbances occurred in 29 per cent, cerebellar signs in 53 per cent, mental changes in 50 per cent, and epilepsy in 36 per cent. Auditory defects were encountered in about 25 per cent and uncinate attacks were reported as being infrequent. Koutseff<sup>2</sup> submitted a similar study of 59 cases and emphasized the high frequency of hemianopsia and uncinate seizures.

The outstanding symptoms of right temporal lobe disease are centered about the functions of taste, vision, smell and hearing. There may not only be a simple blunting of these senses, but also explosive sensations referred to the opposite side of the body and various elaborations of these phenomena into psychic states, such as dreams and hallucinations.

*Visual Disturbances:* Undoubtedly, all students of the problem will admit that the most accurate localizing sign in the right temporal lobe has been described elaborately by Cushing: a quadrantic hemianopic defect in the contralateral field. This is due to an implication of Meyer's temporal detour in the geniculo-calcarine system. Should the lesion extend deeper into the brain and involve the optic system near the pulvinar and the geniculate body, a complete homonymous hemianopsia is likely to develop.

As a part of this visual aberration there may be contralateral visual hallucinations, physiologically comparable to uncinate aurae and other cortical "discharges" along various sensory systems. Koutseff

noted that 22 per cent of his cases manifested such paroxysms. Janbon and Viallefont<sup>3</sup> described hallucinations limited to a visual semi-field in a case in whom the attacks were attributed to a spasm of the sylvian artery. Stone's<sup>4</sup> patient had visual hallucinations which were homolateral with the lesion. This paradoxical state of affairs was explained on the basis of mixed hemispheric dominance, the lesion being a right-sided temporal tumor with an aphasia in the presence of right-handedness. Among other visual symptoms, Hauptmann<sup>5</sup> has emphasized a sign which he believes to be unique for right-temporal lobe disease. His patient complained of macropsia, that is, objects at times appeared much larger than they should be.

Horrax<sup>6</sup> found that complex visual hallucinations were present in a large number of temporal lobe tumors and disagrees with the old view held by Henschen that such disturbances are primarily due to occipital lobe irritations. The visual experiences may be vivid phantasies, shadows, colored beams, animals, etc. These are particularly useful in localization if the hallucinations come on suddenly and show a definite laterality, being projected toward the side opposite the lesion of the brain.

Schlesinger<sup>7</sup> is of the opinion that occasionally enlargement of the contralateral pupil may be an indication of temporal lobe tumor, but offers no neurophysiological explanation.

*Olfactory and Gustatory Phenomena:* These disturbances, which are generally referred to the hippocampal lobes, are a familiar expression of tumors lying along the temporo-sphenoidal ridge. The dramatic features of expanding lesions at this site are explosive sensations of smell and taste, which are blended with peculiar dream states. A disgusting odor permeates the phantasy which for the moment is terrifyingly real to the patient. The uncinate irritation gives rise to a panoramic mental experience which may expand to include every possible sensory component. Several of these amplified dreams are beautifully described by Kennedy<sup>8</sup> who also observed characteristic chewing reflexes, grimaces of disgust and expressions of fear as concomitant motor patterns.

*Auditory Disturbances:* Even though it is generally presumed that the right temporal lobe has something to do with the function of hearing, auditory symptoms due to tumors or other lesions in this portion of the brain are not clearly understood. Koutseff found no disturbances of hearing in his entire series. Out of six cases of temporal lobe tumor, Ganner and Stiefler<sup>9</sup> found diminution of hearing in only one patient and this was in a homolateral ear. Rowe believes that an impairment of hearing, particularly for spoken words, tinnitus and auditory hallucina-

## SYMPTOMATOLOGY OF RIGHT TEMPORAL LOBE LESIONS

tions occur very frequently, but again he made no attempt to differentiate right from left temporal lobe defect. Hauptmann's patient suffered with occasional head noise in the homolateral ear. Lawson<sup>10</sup> also reported deafness in the homolateral ear in a destruction of the left lobe, but admitted that there was some deafness also in the opposite ear.

Routine auditory tests done on three patients in whom a right hemispherectomy had been performed by Gardner at the Cleveland Clinic revealed that two had "normal" hearing in both ears. The third claimed deafness in the contralateral ear, but was in such poor condition that her subjective data were not very reliable. Penfield<sup>11</sup>, who made similar studies of his surgical ablations of the right hemisphere, conceded that ordinary hearing acuity may not be badly blunted but suggested that, if more careful studies of auditory agnosia were made, such a defect may be found in the contralateral ear.

*Psychic Disturbances:* Closely allied to those mental auras arising out of uncinate irritation are psychic components described by several writers under the term "le sentiment du déjà vu." These intellectual auras consist largely of a sensation of having lived through the exact scene then being enacted, of being able to tell what is going to happen next. Keschner<sup>12</sup> regards this as being exceedingly rare, finding not a single instance of this symptom in 110 cases. Dream states have been also described which are said to have such a peculiar quality that they may be clearly expressive of right temporal lobe pathology. Objects and experiences may appear as phantoms but when these pass away they are always regarded by the patient as having been phantoms and nothing more. Apparitions appear at the bedside in the same room with startling clarity; some of these vivid visual visitations may have an infusion of olfactory and gustatory components, may take on the "déjà vu" quality and the entire subjective experience may become such a voluminous psycho-sensory episode that it can hardly be said to have any localizing value. It is this psychic complexity that prompts such psychiatrists as Hoffman<sup>13</sup> to conclude that no true psychic state is characteristic of any one portion of the brain. Kolodny<sup>14</sup> lists the psychic disturbances most often observed in tumors of this area as: loss of memory, changes of character and temperament, hypersomnia and mental confusion.

Either temporal lobe "irritation" upsets the entire mental harmony by an overflow of abnormal stimuli to other parts, or the lesion by direct pressure on adjacent structures creates these profound psychic changes so that their localizing value can be seriously questioned.

The possibility that a study of an actively expanding right temporal lobe lesion with all of its "irritative" potentialities, contrasted with

the study of a patient in whom this lobe was not primarily involved but was ablated by surgical resection, would have some value in clarifying a few of the many controversial points, prompts this discussion.

To this end, two patients having neoplasms of the right hemisphere, both proved oligodendrogliomas, are presented for comparison. In the first patient, the growth began clearly in the right temporal lobe and expanded into the adjacent parietal and frontal lobes. In the second individual, the neoplasm originated in the parietal zones and did not implicate the temporal lobe, which however was removed because in the opinion of the neurosurgeon an almost complete hemispherectomy was indicated. It is assumed that in the first case, some of the symptoms can be ascribed to direct invasion, irritation and compression of the right temporal lobe, to extension and to involvement of the parietal and frontal lobes. In the second patient, whatever symptoms can be found which may be attributed to temporal lobe disease are due to ablation of it and adjacent structures.

*Case 1:* A man, 39 years of age, was admitted to the Clinic on August 22, 1934. He was a feature writer, having worked for various newspapers in Cincinnati, San Francisco and Cleveland. For two years he had been having minor attacks of dizziness and periods of momentary unconsciousness. For the preceding three months, the attacks had been preceded by an olfactory aura of metallic quality. Occasionally he had paroxysmal sensations of bright light to his left side, and also noted that while driving he could not see the stoplights above and to his left, if his vision was directed straight ahead. He had ringing in both ears during the attacks and some loss of hearing for low tones.

His chief complaint, however, was a tendency to exaggerate, for which he was taken to task by his editor. Lately he complained of loss of memory and because of this on several occasions could not recall where he had parked his car. Two months before, he had proposed to his landlady's immature daughter, in spite of the fact that he was not legally divorced. He denied dream states.

The discs were bilaterally choked. There was a left upper, quadrantic hemianopsia. The left pupil was dilated, and roentgen examination revealed a calcified mass in the right temporal lobe.

On August 24, 1934, the major portion of the right temporal lobe was excised, beginning exactly at the sylvian fissure and including everything but its anterior pole and the mesial surface. Recovery was uneventful and he was discharged on September 7, 1934.

Eighteen months later he returned because of frequent headaches, left hemianopsia and a bulging of his temporal decompression. He had been having increasing difficulty with his newspaper work. Feature articles were rejected because their content was silly or exaggerated. His landlady complained of his untidy bathroom habits.

Shortly after his second admission on March 22, 1936, he insisted that he had been married while in the Clinic to an 18-year-old socialite of Cleveland. He described the marriage scene with fine clarity, claiming that Doctor Crile arranged the marriage and two nurses presided as witnesses. The ceremony was always recalled as having taken place to the left side of his bed. Frequently,

## SYMPTOMATOLOGY OF RIGHT TEMPORAL LOBE LESIONS

however, he volunteered the information that the marriage was a "dream," and expressed a desire to write an article for the papers about his unusual experience. The left lower face was weak in both emotional and voluntary activation. The left hand was also weak and moderately spastic. The discs were edematous and there was now an almost complete homonymous hemianopsia.

On March 23, 1936, Doctor Gardner reopened the old site of operation and found the right temporal lobe had been replaced with tumor. The major portions of the adjoining parietal and frontal lobes were now removed. Most of the motor and premotor cortex were included in the excision.

Again he recovered very well from the operation but obviously with a left hemiplegia. During his convalescence he became progressively euphoric, demonstrating a definite "witzelsucht." He continued to write articles for his paper, among which was a review of Dr. Crile's book, "The Phenomena of Life." This was so well done that it was accepted and highly praised. Intermittently he reiterated that he had been married to a young heiress at the Clinic. His mental condition was marked by dysphoria, mental sluggishness and his insight became poor. He was transferred to a psychiatric hospital where he continued to be expansive, dictatorial and untidy. He lived until March 20, 1937. Necropsy was refused.

*Case 2:* A white man, 35 years of age, a salesman, was admitted to the Clinic on May 12, 1934. About 5 years before, while driving a stake, he had a peculiar sense of circumpulsion, a sensation that the stake was revolving and that he was whirling in unison. A month later he had a sudden tapping sensation in the left knee and elbow. Occipital headaches began two years ago, at which time he also developed Jacksonian sensory auræ over the entire left side of the body.

Examination revealed a long-standing papilledema. The left pupil was larger than the right. He veered to the left in walking. There was a paresis of the left leg with loss of sense of position in the left great toe. There was some astereognosis of the left hand. Roentgen examination showed a large, slightly calcified tumor in the right parietal region.

He never manifested any mental or other symptoms referable to the right temporal lobe. The defects were entirely of a somatic, sensory quality. The motor components were entirely negative.

On March 15, 1934, Doctor Gardner removed a tumor mass the size of a small orange (185 gm.) from the right parietal region. He had a normal convalescence with no paralysis and was discharged on May 29, 1934.

Jacksonian convulsions recurred on December 22, 1934. The left leg and arm became rapidly weaker. The discs were not choked, but rather pale.

On June 20, 1935, a second operation resulted in the removal of an additional 55 gm. of tumor and brain tissue from the site of the previous operation.

On March 4, 1936, a third operation was deemed necessary because of frequent convulsions, epigastric pain and headache. At this time the visual fields were markedly constricted and there was a suggestion of a lower left quadrantic hemianopsia. Mental disturbances and uncinæ fits were denied. At this time so much of the right hemisphere was removed that there only remained the basal ganglia, the uncinæ gyrus, the tip of the temporal lobe and the anterior two-thirds of the frontal lobe. The resected specimen weighed 605 gm. Examination of this mass revealed no tumor infiltration into either the occipital or temporal portions.

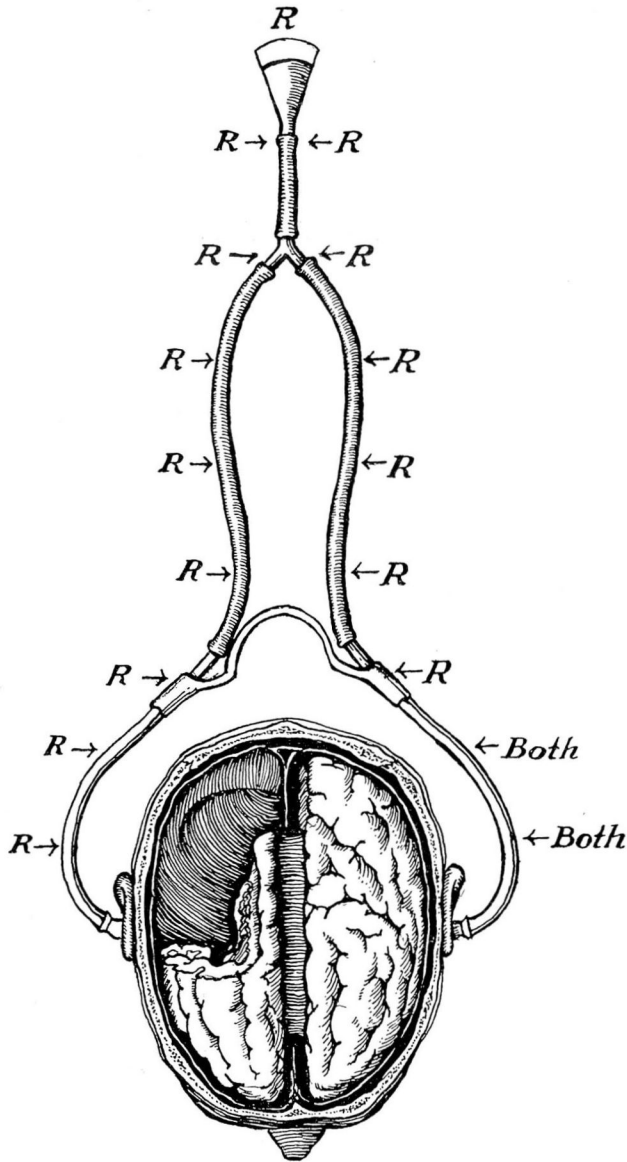


FIGURE 1: Scheme demonstrating a simple test for auditory agnosia. The stethoscope is applied, as shown, to the patient's ears and at various distances the instrument is rubbed with a tongue blade. The results are recorded in a patient in whom the right temporal, occipital and parietal lobes have been removed. There is an auditory agnosia in the left ear, for the patient did not at any time orient the source of the sound with this ear alone.

The patient continues to "carry on" to the present day, running a chicken farm.

In June, 1937, he began again with Jacksonian attacks on the left or paralyzed side. There is a sensory aura as if something were hitting him on the left



## SYMPTOMATOLOGY OF RIGHT TEMPORAL LOBE LESIONS

thumb. The head and eyes are turned to the left and over his left shoulder there is seen a steady glow like the setting of the sun during each paroxysm. Along with his hemiplegia he has a full homonymous hemianopsia. His auditory symptoms are notable. He believes his left ear is worse, for he involuntarily turns his right ear to his visitors. Tinnitus is present like a humming or squeaking but only in the right ear. Aerial conduction with the 256 tuning fork is poor in the left ear. The Weber test is referred to the right ear. Vibration over both mastoids is the same. Spatial orientation is poor in the left ear. A simple device for testing spatial auditory sense was applied. A stethoscope was placed in the ears with the bell pointed backward. (Fig. 1.) The results clearly demonstrated that the position of the source of sound, which is produced by a tongue blade rubbed on the instrument, is poorly appreciated in the left ear. The audiometer also reveals some absolute loss of auditory acuity in the left ear.

Of mental aberrations attributed to temporal lobe disease he displays none. He is generally cheerful, but not euphoric. His judgment is good in business; he insists that he is less sensitive, but perhaps more irritable. He has no wide swings in mood; denies any dream states or uncinat attacks; "déjà vu" experiences are not recalled. His only handicaps are his hemiplegia, the tinnitus and the frequent Jacksonian seizures accompanied by the visual auræ in the left semi-field.

TABLE I

SYMPTOMS FOUND IN AN IRRITATIVE, EXPANDING LESION OF THE  
RIGHT TEMPORAL LOBE CONTRASTED WITH THOSE DUE TO  
ABLATION OF THE SAME LOBE

	CASE 1 <i>Irritative, Ex- panding lesion</i>	CASE 2 <i>Surgical Ablation</i>
<b>VISUAL SYMPTOMS:</b>		
a) Contralateral Hemianopsia .....	Present	Present
b) Contralateral Visual Auræ .....	Present	Present
c) Contralateral Mydriasis .....	Present	Present
d) Macropsia or Micropsia .....	Absent	Absent
<b>OLFACTORY SYMPTOMS:</b>		
a) Uncinate fits .....	Present	Absent
<b>AUDITORY SYMPTOMS:</b>		
a) Contralateral Deafness .....	Present	Present
b) Contralateral Agnosia .....	Present	Present
c) Tinnitus .....	Both ears	Ipsilateral
d) Auditory Hallucinations .....	Absent	Absent
<b>COMPLEX PSYCHIC SYMPTOMS:</b>		
a) Dream States .....	Present	Absent
b) Déjà vu .....	?	Absent
c) Euphoria .....	Present	Absent

The comparison offered in the table above clearly emphasizes that psychic disturbances are almost entirely the product of a lesion which is infiltrating and expanding in nature. It is doubtful that high intracranial pressure is a prime factor, for both patients had this symptom.

## CONCLUSIONS

An expanding or irritative lesion beginning in the right temporal lobe provides a symptomatology replete with mental disturbances, all of which arise out of excitation of the three special sensory centers, namely, smell, hearing, and sight. These may be elaborated into a broad psychic panorama, resulting in dream states, tintured with auditory, visual, and olfactory auras which are generally referred to the contralateral side.

No such mental manifestations occur if the lesion begins in the parietal lobe. Neither are any of these singular mental experiences found on ablation of the temporal lobe and its adjacent brain tissues.

What symptoms remain as true ablation phenomena or signs of destruction? Varying degrees of homonymous hemianopsia are constant features. Visual auras may occur, but they are pure, unelaborated sensations of light and color without psychic concomitants. Contralateral mydriasis, as pointed out by Schlesinger, is present, probably when destruction or ablation is quite extensive. In the auditory field, it appears that there is some absolute blunting of hearing in the contralateral ear, some tinnitus in both ears. Tests for auditory agnosia tend to support Penfield's idea that such defect always occurs in the contralateral ear if the entire right temporal lobe is removed.

## REFERENCES

1. Rowe, S. N.: Verified tumor of the temporal lobe; a critical review of 52 cases, *Arch. Neur. & Psychiat.*, 30:824-842, (October) 1933.
2. Koutseff, A.: Quantitative perimetry and tumors of the temporal lobe, *Arch. Neur. & Psychiat.*, 24:1272, (December) 1930.
3. Janbon, M. and Viallefont, H.: Hallucinations in a visual semifield from spasm of the sylvian artery, *Arch. Neur. & Psychiat.*, 26:636, (September) 1931.
4. Stone, L.: Paradoxical symptoms in right temporal lobe tumors, *J. Nerv. & Ment. Dis.*, 79:1-13, (January) 1934.
5. Hauptmann, A.: Symptomatology of diseases of the right temporal lobe, Jubileum Edition in honor of Dr. Max Nonne's seventieth birthday, *Deutsch. Ztschr. f. Nervenk.*, 1931, Vols. 117-119.
6. Horrax, G.: Visual hallucinations in temporal lobe tumors, *Arch. Neur. & Psychiat.*, 10:532-547, (November) 1923.
7. Schlesinger, B.: Fibrillary astrocytomas of temporal lobe, *Arch. Neur. & Psychiat.*, 29:843-854, (April) 1933.
8. Kennedy, F.: Symptomatology of frontal and temporosphenoidal tumors, *J.A.M.A.*, 98:864-866, (March 12) 1932.
9. Ganner, H. and Stiefler, G.: The symptomatology of tumors of the temporal lobe, *Arch. f. Psychiat.*, 101:399-451, (December) 1933.
10. Lawson, L. J.: Spongioblastoma of left temporal lobe with impairment of hearing, *Arch. Otolaryng.*, 15:583, (April) 1932.
11. Penfield, W.: Personal Communication.
12. Keschnier, M. and Strauss, I.: Mental symptoms in cases of tumor of the frontal lobe, *Arch. Neur. & Psychiat.*, 35:986-1007, (May) 1935.
13. Hoffman, J. L.: Intracranial neoplasms: Their incidence and mental manifestations, *Psychiat. Quarterly*, 11:4, p. 561.
14. Kolodny, A.: The symptomatology of tumors of the temporal lobe, *Brain*, 51:385-417, (October) 1928.