

Radiology feature

Edward Buonocore, M.D.,
Section Editor

Radiologic detection of parathyroid adenoma

Edward Buonocore, M.D.
William Chilcote, M.D.

Department of Hospital Radiology

Caldwell B. Esselstyn, Jr., M.D.

Department of General Surgery

A 58-year-old white woman was seen at the Cleveland Clinic with bone pain and muscle cramps, polydipsia, and generalized weakness and malaise. She had a history of renal failure and urolithiasis. At another institution, she was found to have hypercalcemia and a lytic defect in the right iliac wing. Despite two surgical neck explorations in which three normal parathyroid glands were removed and no abnormalities were found, the symptoms persisted and she was referred to the Cleveland Clinic.

At another hospital, prior to admission to the Cleveland Clinic, collections of blood from veins draining the upper mediastinum and neck regions had been obtained by selective catheterization. Elevated levels of parathormone were detected in the serum from the veins draining the region of the right thymus.

On admission to the Cleveland Clinic, the blood urea nitrogen (BUN) level was 32 mg/dl; creatinine, 2.9 mg/dl; calcium, 12.6 mg/dl; phosphorus, 3.8 mg/dl; alkaline phosphatase, 2000 units/L; and hemoglobin, 10.5 g/dl. Because of the elevated parathormone levels in the veins from the region of the right thymus, the right thyroid lobe and right side of the thymus were excised. No parathyroid tissue or tumor was identified.

Questions

1. In the further care of this patient, what would you recommend? What region should be evaluated and by what method?

2. Has this patient had the most effective evaluation of her problem?

After consultation with the Department of Diagnostic Radiology, a high-resolution CT scan of the mediastinum was obtained. A mediastinal mass was identified just anterior to the ascending aorta, which increased in density after intravenous injection of contrast medium (*Fig. 1*). The following day, digital subtraction angiography (DSA) of the chest confirmed the presence of a mass

and delineated its relationship to the major vascular structures of the chest. No large arterial feeders to the mass were identified (*Fig. 2*).

A fourth surgical exploration via median sternotomy was performed and a parathyroid adenoma was identified and excised from the anterior mediastinum. A portion of the excised parathyroid gland was autotransplanted to the left rectus muscle. After surgery the patient did well. There was a progressive decrease in serum calcium levels and resolution of bone pain. Four months after surgery, the serum calcium level dropped to 9.6 mg/dl; phosphorus, 2.6 mg/dl; and alkaline phosphatase was reduced to 200 units/L.

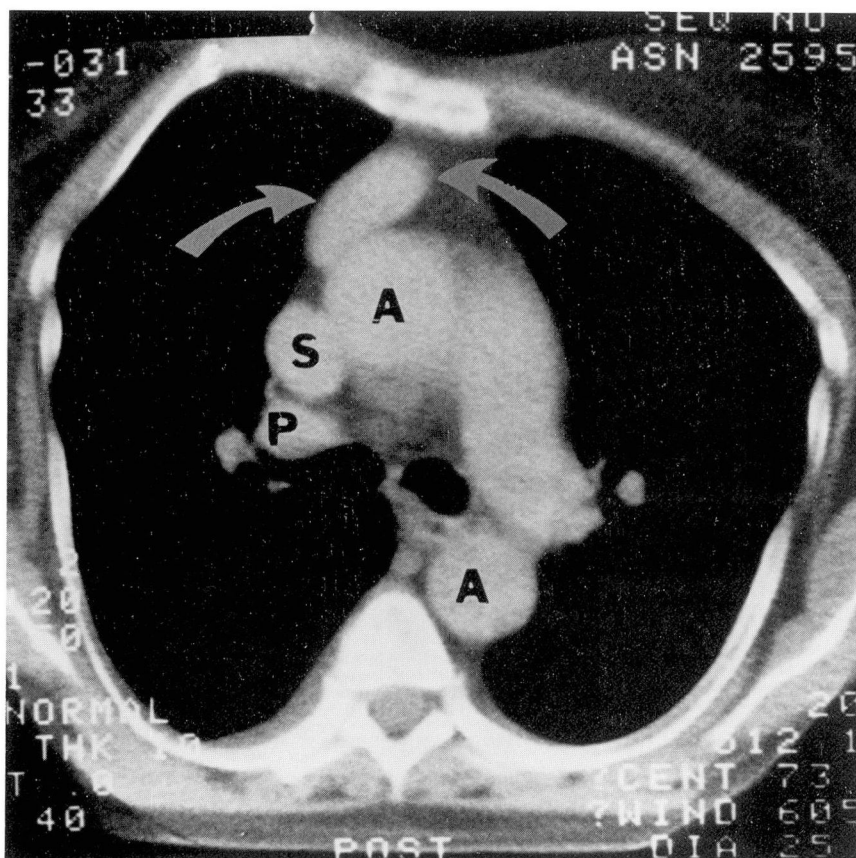


Fig. 1. CT scan of the upper mediastinum. A well-defined mass is identified in the anterior mediastinum (arrows), just anterior to the ascending aorta (A). S = superior vena cava; P = right pulmonary artery.

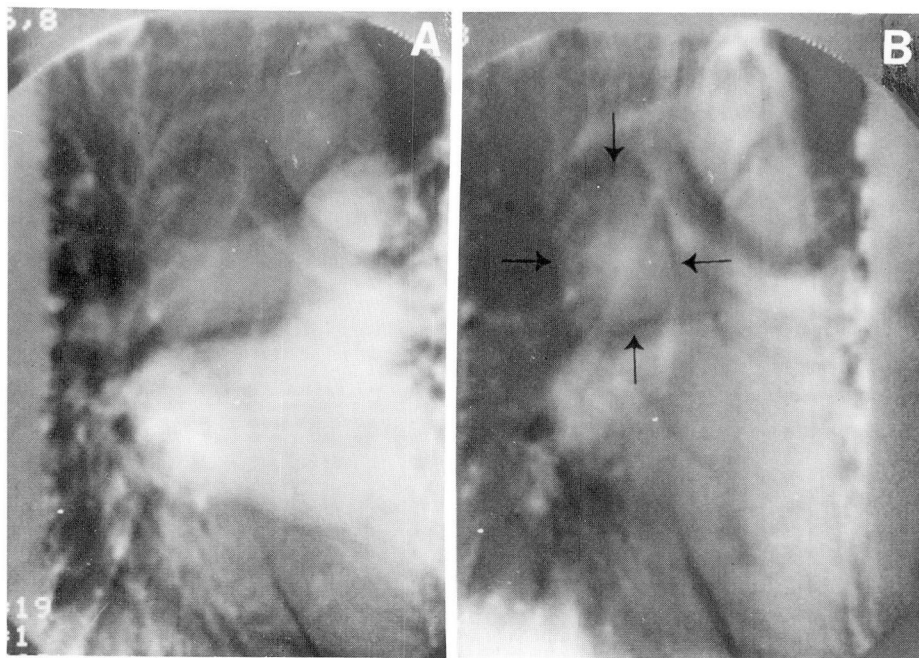


Fig. 2. Early (A) and late (B) phase of DSA of the chest after 40 ml 76% contrast medium to the basilic vein of the right arm. Retained contrast agent identifies a mass in the right side of the anterior mediastinum (arrows), in the same position as the mass identified on CT (Fig. 1).

Discussion

Computed tomography reconstructs anatomy by distinguishing the density differences of the tissues.¹ It is particularly effective for exploring areas containing fat and air because of the marked differences in their densities. Because of the abundance of surrounding fat, mediastinal tumors are easily detected on CT.

The astute clinician can easily diagnose hyperparathyroidism in patients similar to ours. In 90% of cases, the pathologic process will be found on surgical exploration of the neck.² If no abnormality is found, repeat surgical explorations become progressively more difficult and are not warranted without radiologic examination of the neck and mediastinum, and venous sampling for parathormone levels from the veins draining the neck and upper chest.

Ten percent of parathyroid tumors are either embedded in thymic tissue or descend into the chest and are not detected by surgical exploration of the neck. Their presence in the anterior mediastinum can usually be detected on CT. An additional property of parathyroid adenomas is their tendency to retain systemically injected contrast medium, which produces a characteristic "tumor stain."³ This has also permitted their detection on angiography and has become a standard means for identification and ablation of ectopic tumors.

Digital subtraction angiography is particularly sensitive in the detection of low-contrast objects,⁴ if good subtraction is achieved. It is also a means of detecting parathyroid adenomas in unusual positions (Fig. 3). Eisenberg⁵ identified five parathyroid adenomas in the neck and mediastinum on DSA by vis-

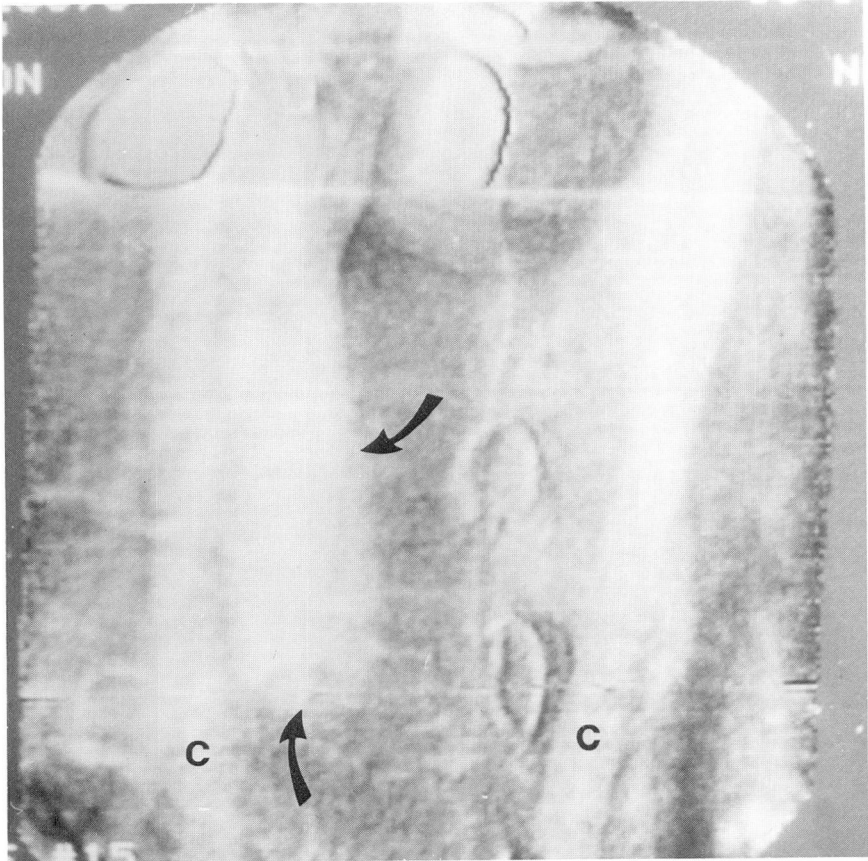


Fig. 3. DSA of the neck, frontal projection, of another patient with a 3 × 1-cm parathyroid adenoma embedded in the posterior portion of the right side of the thymus found on repeat surgery. Dense stain reveals adenoma (arrows). Previous surgical exploration of the neck was unrevealing (C = carotid arteries).

ualization of contrast medium within the tumors (*Fig. 3*).

Ectopic parathyroid adenomas are detectable by radiologic techniques, which eliminate the need for repeated nonproductive surgical explorations of the neck. We look forward to significant reductions in morbidity and medical costs in the management of this complex medical problem.

References

1. Hounsfield GN. Computed medical imaging. *Med Phys* 1980; **7**: 283-290.
2. Krudy AG, Doppman JL, Brennan MF, et al.

The detection of mediastinal parathyroid glands by computed tomography, selective arteriography and venous sampling; an analysis of 17 cases. *Radiology* 1981; **140**: 739-744.
3. Doppman JL. Parathyroid localization; arteriography and venous sampling. *Radiol Clin North Am* 1976; **14**: 163-188.
4. Buonocore E, Meaney TF, Borkowski GP, Pavlicek W, Gallagher J. Digital subtraction angiography of the abdominal aorta and renal arteries; comparison with conventional aortography. *Radiology* 1981; **139**: 281-286.
5. Eisenberg H. Digital subtraction angiography of the head and neck. Presented at the Society of Cardiovascular Radiology, 7th Annual Meeting, Palm Springs, California, February 15-18, 1982.