

# Pemphigus-like antibodies in a patient with cicatricial pemphigoid

Maryann Fitzmaurice, Ph.D.  
Rafael Valenzuela, M.D.

*Department of Immunopathology*

James S. Taylor, M.D.

*Department of Dermatology*

Laurence K. Groves, M.D.

*Department of Thoracic and Cardiovascular Surgery*

Sharad D. Deodhar, M.D.,  
Ph.D.

*Department of Immunopathology*

Immunofluorescent testing has become a valuable adjunct to histopathologic studies in the diagnosis of the bullous dermatoses.<sup>1-3</sup> In pemphigus, the acantholytic intraepithelial bullae in the stratified squamous epithelia of the skin and mucous membranes associated with deposits of anti-intercellular substances (ICS) antibodies are detectable by direct immunofluorescence (DIF).<sup>4</sup> In pemphigoid, including the bullous and cicatricial forms (benign mucous membrane pemphigoid), nonacantholytic subepithelial bullae in the stratified squamous epithelia of the skin and mucous membranes associated with deposits of antibasement membrane (BM) antibodies are detectable by DIF.<sup>5</sup>

Circulating anti-ICS antibodies in the serum of pemphigus patients can be detected by indirect immunofluorescence (IIF).<sup>4</sup> Like pemphigus, bullous pemphigoid is also characterized by circulating anti-BM antibodies detectable in the serum by IIF. However, circulating anti-BM antibodies are seen much less frequently in cicatricial pemphigoid.<sup>5</sup>

True pemphigus anti-ICS and true pemphigoid anti-BM antibodies are believed to be disease-specific. However, there have been increasing reports of pemphigus-like anti-ICS antibodies in patients with other clinical conditions, including severe thermal burns,<sup>6-9</sup> abnormally high isohemagglutinin

titors,<sup>10-12</sup> and certain bullous drug eruptions.<sup>13-18</sup> Pemphigus-like anti-ICS antibodies have been detected in patients with bullous dermatoses other than pemphigus<sup>19-21</sup> including three patients with cicatricial pemphigoid.

In this report, we present a patient with the clinical history and physical findings of cicatricial pemphigoid with a pemphigus-like anti-ICS antibody in the serum detected by IIF.

### Case report

A 78-year-old white man was referred to the Department of Thoracic and Cardiovascular Surgery at The Cleveland Clinic Foundation in September 1978 with a 10-year history of progressive dysphagia. At that time the dysphagia was total, resulting in frequent episodes of nocturnal aspiration, and requiring gastrostomy feeding over the last two years. Physical examination revealed ulcerations of the buccal mucosa and severe distortion of the oral pharynx that interfered with speech. There was no clinical history or physical findings of skin involvement.

A normal barium swallow was impossible, and injection of barium through the gastros-

tomy tube allowed only some back filling of the distal esophagus. Esophagoscopy revealed severe distortion of the lower pharynx well above the level of the larynx that prevented passage of the esophagoscope but not a small bougie into the esophagus. Esophagogastroduodenoscopy revealed an inflammatory fibrous stricture that prevented retrograde passage of the esophagogastroduodenoscope into the esophagus above the level of T<sub>7</sub> or T<sub>8</sub>.

The patient had been blind in the left eye for the past 15 years and there was marked ptosis of the left eyelid. Ophthalmologic examination revealed end-stage ocular pemphigoid in the left eye with symblepharon, shortening of the fornices, fixation of the eyelid, and parchment membrane destruction of the cornea (*Fig. 1*).

The Department of Dermatology was then consulted and histopathologic studies were done. A biopsy specimen of buccal mucosa submitted at that time for routine hematoxylin-eosin staining as paraffin sections was devoid of stratified squamous epithelium and showed only angioplasia and chronic inflammation in the remaining submucosal connective tissue when examined by light microscopy. A diagnosis of cicatricial pemphigoid was made on the basis of the history and classical physical findings.

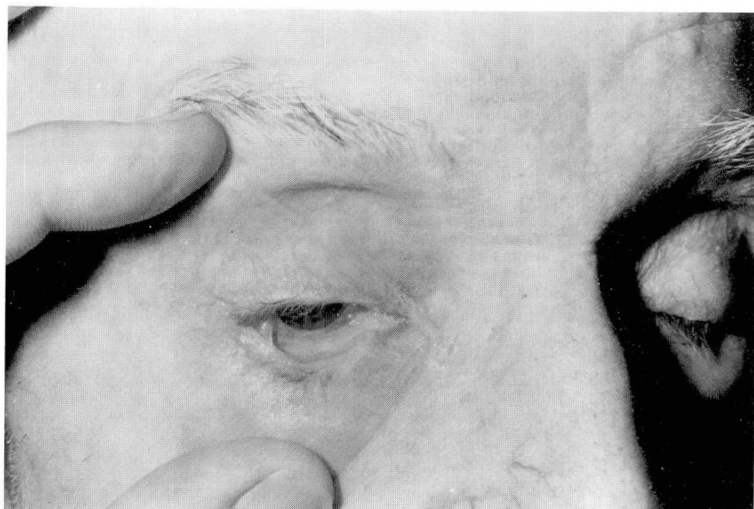

Fig. 1. Cicatricial pemphigoid changes in the left eye.

The patient showed no significant progression of his disease over the next two years and was reexamined by his family physician in November 1980. At that time biopsy specimens of both normal buccal mucosa and normal skin of the arm were obtained for further DIF studies.

## Methods

Skin and buccal mucosa specimens for DIF studies were obtained by punch biopsy, transported in Michel's medium,<sup>22</sup> quick-frozen in liquid nitrogen, and stored at  $-70^{\circ}\text{C}$  until cut into  $4\mu$  frozen sections with a Lipshaw cryostat. Direct immunofluorescence was performed on the frozen sections by standard techniques<sup>23</sup> with use of fluorescein isothiocyanate (FITC) conjugates of monovalent rabbit antisera to human IgG (Behring Diagnostics) (F/P = 2.5), IgM (Behring Diagnostics) (F/P = 2.5), IgA (Behring Diagnostics) (F/P = 2.5), C3 (Behring Diagnostics) (F/P = 2.5), and fibrinogen (Behring Diagnostics) (F/P = 2.5).

Sera for IIF studies were obtained by aspiration from whole peripheral blood that was collected by antecubital fossa venipuncture, allowed to clot at room temperature, and then centrifuged at 1500 rpm for 15 minutes at room temperature. The sera were then stored at  $4^{\circ}\text{C}$  until tested. African green monkey esophagus (Pelfreez Biologicals), human esophagus, and human skin were used as tissue substrates. Human skin specimens were obtained at hair transplant surgeries, and human esophagus specimens at autopsy. All three tissues were quick-frozen in liquid nitrogen and stored at  $-70^{\circ}\text{C}$  until cut into  $4\mu$  frozen sections with a Lipshaw cryostat. Indirect immunofluorescence was performed on the frozen sections by standard techniques<sup>23</sup> with use of FITC conjugates of a goat antiserum to human total gamma

globulin (Kallestaad) (F/P = 2.7–3.7) as well as the monovalent antisera described above. Sera diluted at 1:20 were absorbed with an equal volume of packed pooled type A or type B red blood cells from normal donors for one hour each at  $37^{\circ}\text{C}$ , room temperature, and  $4^{\circ}\text{C}$  and then retested by IIF. Both pemphigus vulgaris patient sera with true pemphigus antibodies and anti-A and anti-B blood group substance typing sera (American Hospital Supply) were used as controls for the absorption studies.

## Results

A biopsy specimen of buccal mucosa obtained at the time of initial diagnosis was devoid of stratified squamous epithelium and was negative for deposition of IgG, IgM, IgA, C3, and fibrinogen in the remaining submucosal connective tissue. A second biopsy specimen of normal buccal mucosa obtained at the time of reevaluation was intact, and was negative for deposition of IgG, IgM, IgA, C3, and fibrinogen. A normal skin biopsy specimen from the arm obtained at the time of reevaluation was also negative for deposition of IgG, IgM, IgA, C3, and fibrinogen in both the dermis and epidermis.

Sera taken both at the time of initial diagnosis and at reevaluation contained anti-ICS antibodies at a titer of 1:80 when studied by IIF with African green monkey esophagus as the tissue substrate (*Fig. 2*). These antibodies bound largely to the lower layers of the mucosal epithelium, exclusive of the basal cell layer. Anti-ICS antibodies present in the initial serum specimen bound to African green monkey esophagus but not to human esophagus or skin substrates when screened for tissue specificity. Anti-ICS antibodies present in the second serum specimen bound to both African green

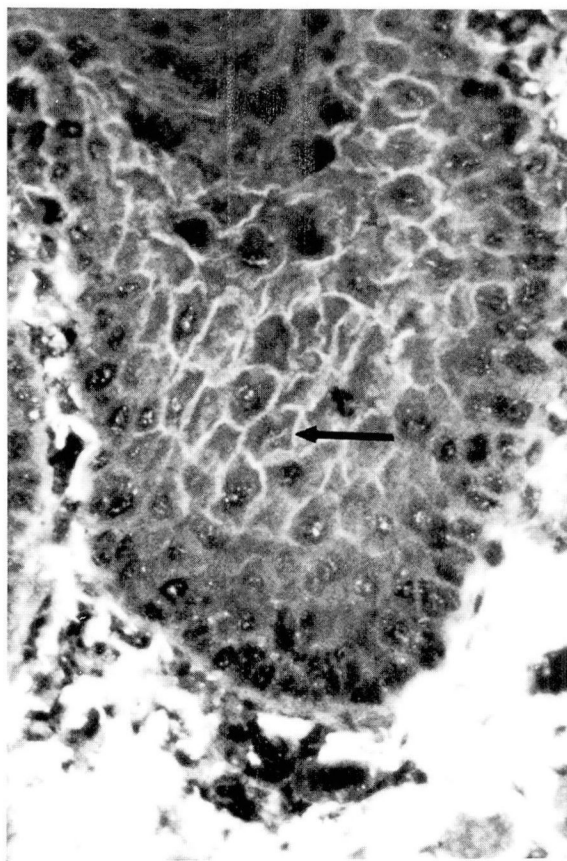
monkey and human esophagus but not to human skin substrates. Anti-ICS antibodies present in both serum specimens did not bind to the patient's own skin or buccal mucosa when these tissues were used as substrates.

The anti-ICS antibodies present in both serum specimens were found to be of the IgG class when screened by IIF with FITC conjugates of the monovalent antisera on the African green monkey esophagus tissue substrate. Neither the patient's anti-ICS antibodies nor anti-ICS antibodies in the sera of the patients with pemphigus vulgaris were removed by absorption with either type

A or B human red blood cells, as were anti-A and anti-B antibodies in the commercial typing sera used as controls.

### Discussion

The clinical history and physical findings of oral ulceration, severe esophageal stricture requiring gastrostomy feeding, and cicatricial ocular involvement resulting in blindness are strongly supportive of the diagnosis of cicatricial pemphigoid in this patient. Unfortunately, as may be characteristic in this disorder, the diagnosis could not be confirmed histopathologically or by DIF. In fact, vesicles or bullae are rarely present



**Fig. 2.** Indirect immunofluorescent staining for IgG (arrow) in the intercellular substance of African green monkey esophagus tissue substrate ( $\times 250$ ).



in cicatricial pemphigoid. The initial biopsy specimen of buccal mucosa was completely devoid of stratified squamous epithelium including the basal cell layer, which may have resulted from a subepithelial bullous disorder or artificial removal in processing. There were no significant histopathologic or DIF findings in the remaining submucosal connective tissue. Hence, neither the presence of subepithelial bullae nor BM zone antibody deposits characteristic of cicatricial pemphigoid could be documented in this patient. In addition, IIF revealed the presence of circulating anti-ICS rather than BM antibodies as might be expected in cicatricial pemphigoid. A conjunctival biopsy specimen for DIF, which might have shown immunoglobulin deposition in cicatricial pemphigoid, was not obtained in this patient.

It is possible, but not likely, that the correct diagnosis of this case is pemphigus vulgaris with esophageal and ocular involvement. Although pemphigus vulgaris usually does present in the buccal mucosa, it almost always progresses to the skin.<sup>4</sup> In addition, esophageal<sup>24</sup> and ocular<sup>25</sup> involvement are both rare in true pemphigus. In comparison, cicatricial pemphigoid is frequently restricted to the buccal or esophageal mucosa.<sup>5</sup> In fact, the combination of esophageal and ocular involvement is virtually pathognomonic of cicatricial pemphigoid. Neither the acantholysis nor the intraepithelial bullae characteristic of pemphigus could be documented histopathologically in this patient. The diffuse deposition of IgG or C3 in the ICS, which is characteristic of pemphigus vulgaris, was not detected in the biopsy specimens.

Pemphigus-like anti-ICS antibodies have been detected in 2 patients by Roenigk and Deodhar,<sup>19</sup> in 2 patients with cicatricial pemphigoid by Cram et

al,<sup>20</sup> and in one patient with bullous pemphigoid by Heine et al.<sup>21</sup> In these patients, the diagnoses were confirmed histopathologically and by DIF. The pemphigus-like anti-ICS antibodies in Heine's patient with bullous pemphigoid, like those in our patient, were of the IgG class and were not removed by absorption with ABO blood group substances. It is interesting that the pemphigus-like anti-ICS antibodies in our patient bound to mucosal but not to skin substrates in the IIF assay. What relation this has to the fact that bullae were seen in the mucosa but not in the skin is still unknown.

Pemphigus-like anti-ICS antibodies have also been reported in association with severe thermal burns,<sup>6-9</sup> abnormally high isohemagglutinin titers,<sup>10-12</sup> and adverse reactions to certain drugs including penicillin,<sup>13</sup> penicillamine,<sup>14-17</sup> and azathioprine.<sup>18</sup> These antibodies are frequently transient, of either the IgG or IgM class, and, in the case of the isohemagglutinins, are removed by absorption with the appropriate ABO blood group substances.

Pemphigus-like anti-ICS antibodies have been distinguished in general from true pemphigus antibodies by their apparent inability to bind *in vivo*.<sup>26</sup> This was demonstrated in our patient not only by our inability to detect anti-ICS antibodies prebound to the patient's own tissues by DIF, but also by our ability to detect anti-ICS antibody binding to the patient's own tissues when they were used as substrates for IIF.

The presence of pemphigus-like antibodies can be explained as a predictable immunologic response to epithelial antigens released during tissue injury in patients with severe thermal burns or adverse drug reactions. The pemphigus-like binding pattern of serum isohem-

agglutinins is also not unexpected, as the blood group substances are deposited in the ICS of the stratified squamous epithelia used as tissue substrates for IIF.<sup>27</sup>

The production of these antibodies in bullous dermatoses other than pemphigus is difficult to explain, and we may have to modify our interpretation of immunofluorescent results in these conditions.

### Acknowledgments

The authors gratefully acknowledge the cooperation of Ernest H. Winterhoff, M.D. in obtaining the biopsy specimens for this study, and the technical assistance of Marcia Yeip, MT(ASCP)I, Sharon Slaughter, MT(ASCP)I, Kathleen Pristas, MT(ASCP), and Laura Lunt, MT(ASCP)I.

### References

1. Beutner EH, Jordon RE. Demonstration of skin antibodies in sera of pemphigus vulgaris patients by indirect immunofluorescent staining. *Proc Soc Exp Biol Med* 1964; **117**: 505-510.
2. Beutner EH, Lever WF, Witebsky E, Jordon R, Certock B. Autoantibodies in pemphigus vulgaris. *JAMA* 1965; **192**: 682-688.
3. Jordon RE, Beutner EH, Witebsky E, Blumenthal G, Hale WL, Lever WF. Basement zone antibodies in bullous pemphigoid. *JAMA* 1967; **200**: 751-756.
4. Lever WF. Pemphigus and pemphigoid; a review of the advances made since 1964. *J Am Acad Dermatol* 1979; **1**: 2-31.
5. Person JR, Rogers RS III. Bullous and cicatricial pemphigoid; clinical, histopathologic, and immunopathologic correlations. *Mayo Clin Proc* 1977; **52**: 54-66.
6. Thivolet J, Beyvin AJ. Recherche par immunofluorescence d'autoanticorps sériques vis-à-vis des constituants de l'épiderme chez les brûlés. *Experientia* 1968; **24**: 945-946.
7. Quismorio FP, Bland SL, Friou GJ. Thermal burns; a model for study of autoimmunity in man (abst). *Arthritis Rheum* 1969; **12**: 691-692.
8. Quismorio FP, Bland SL, Friou GJ. Autoimmunity in thermal injury; occurrence of rheumatoid factors, antinuclear antibodies, and antiepitheial antibodies. *Clin Exp Immunol* 1971; **8**: 701-711.
9. Leguit P Jr, Feltkamp TEW, van Rossum AL, van Loghem E, Eijssvoogel VP. Immunological studies in burn patients. III. Autoimmune phenomena. *Int Arch Allergy* 1973; **45**: 392-404.
10. Grob PJ, Inderbitzin TM. Pemphigus antigen and blood group substances A and B. *J Invest Dermatol* 1967; **49**: 285-287.
11. Olson K, Biberfeld G, Fagraeus A. Blood group antibodies as a source of error in the diagnosis of pemphigus by indirect immunofluorescence. *Acta Dermatovenereol* 1972; **52**: 389-392.
12. Petzoldt D. Blutgruppen-Antikörper in der Immunfluoreszenz-Diagnostik des Pemphigus vulgaris. *Hautarzt* 1975; **26**: 444.
13. Fellner MJ, Fukuyama K, Moshell A, Klaus MV. Intercellular antibodies in blood and epidermis; a histochemical study of IgG immunoglobulins in patients with late reactions to penicillins and their comparison with similar antibodies in patients with pemphigus vulgaris. *Br J Dermatol* 1973; **89**: 115-126.
14. Hewitt J, Benveniste M, Lessana-Leibowitch M. Pemphigus induced by D-penicillamine (letter). *Br Med J* 1975; **3**: 371.
15. Marsden RA, Dawber RPR, Millard PR, Mowat AG. Herpetiform pemphigus induced by penicillamine. *Br J Dermatol* 1977; **97**: 451-452.
16. Kristensen JK, Wadskov S. Penicillamine-induced pemphigus foliaceus. *Acta Dermatovenereol* 1977; **57**: 69-71.
17. Sparrow GP. Penicillamine pemphigus and the nephrotic syndrome occurring simultaneously. *Br J Dermatol* 1978; **98**: 103-105.
18. Barker DJ, Cotterill JA. Azapropazone induced bullous drug eruptions. *Acta Dermatovenereol* 1977; **57**: 461-462.
19. Roenigk HH Jr, Deodhar S. Pemphigus treated with azathioprine. *Arch Dermatol* 1973; **107**: 353-357.
20. Cram DL, Griffith MR, Fukuyama K. Pemphigus-like antibodies in cicatricial pemphigoid. *Arch Dermatol* 1974; **109**: 235-238.
21. Heine KG, Kumar A, Jordon RE. Pemphigus-like antibodies in bullous pemphigoid. *Arch Dermatol* 1977; **113**: 1693-1695.
22. Michel B, Milner Y, David K. Preservation of tissue-fixed immunoglobulins in skin biopsies of patients with lupus erythematosus and bullous diseases; preliminary report. *J Invest Dermatol* 1973; **59**: 449-452.

23. Beutner EH, Chorzelski TP, Jordon RE. Appendix IV. Methods of immunofluorescent staining for pemphigus and bullous pemphigoid antibodies. [In] Beutner EH. *Autosensitization in Pemphigus and Pemphigoid*. Springfield; Thomas, 1970; 160-272.
24. Raque CJ, Stein KM, Samitz MH. Pemphigus vulgaris involving the esophagus. *Arch Dermatol* 1970; **102**: 371-373.
25. Bean SF, Holubar K, Gillett RB. Pemphigus involving the eyes. *Arch Dermatol* 1975; **111**: 1484-1486.
26. Chorzelski TP, Beutner EH, Jablonska S. The role and nature of autoimmunity in pemphigus. [In] Beutner EH, Chorzelski TP, Bean SF, eds. *Immunopathology of the Skin*. New York: John Wiley & Sons, 2nd ed, 1979: 206-207.
27. Szulman AE. The histological distribution of blood group substances A and B in man. *J Exp Med* 1960; **111**: 785-799.