

Electrophysiologically guided surgical treatment of recurrent sustained ventricular tachycardia: variables influencing the decision to intervene

Robert J. Eastway, D.O.
James D. Maloney, M.D.
John Yiannikas, M.D.

Department of Cardiology

Leonard A.R. Golding, M.D.

*Department of Thoracic and Cardiovascular
Surgery*

Recurrent sustained ventricular tachycardia (VT_{RS}) in the setting of ischemic heart disease but unrelated to an acute ischemic event is often a life-threatening complication refractory to both medical and surgical therapy.¹ It is most frequently seen in two groups of patients: 1) postmyocardial infarction patients with ventricular aneurysm formation; and 2) patients without discrete aneurysm formation but with scar tissue replacement of a large portion of the left ventricle. Patients with discrete ventricular aneurysm complicated by VT_{RS} have received more attention with respect to the surgical approach to management.

Standard ventricular aneurysmectomy with or without concomitant aortocoronary bypass grafting has been generally unsuccessful in controlling recurrent ventricular tachycardia.²⁻⁶ Intraoperative epicardial and endocardial mapping techniques have been utilized to guide more extensive surgical excision and ablation of the electrophysiologic site responsible for the VT_{RS}.⁷⁻⁹ Early experience with this electrophysiologically guided surgical approach has been encouraging.¹⁰⁻¹²

Many variables may bias selection of surgical candidates and subsequent results. Three patients with postinfarction VT_{RS} undergoing electrophysiologically guided ventricular resection are pre-

sented to illustrate some of the variables influencing patient selection as well as intraoperative electrophysiologic and surgical management.

Materials and methods

Three patients were selected from a larger group of 24 referred for electrophysiologic diagnosis and management of VT_{RS} during a recent three-month period ending in January 1982. All patients had previous angiographically documented myocardial infarction manifested as either a large akinetic scar or dyskinetic left ventricular aneurysm. All three patients had medically refractory ventricular tachycardia either alone or associated with angina pectoris or congestive heart failure and subsequently underwent surgical intervention directed totally or in part at control of ventricular tachycardia.

Preoperative electrophysiologic study

All patients had preoperative electrophysiologic studies as previously described.^{13,14} At least three multipolar electrode catheters were introduced percutaneously via the right femoral vein and positioned in the right atrium, the His bundle region, and the right ventricle for both stimulation and recording purposes. Programmed ventricular extrastimuli were introduced singly and in pairs at various coupling intervals during both sensed and paced modes in an attempt to induce ventricular tachycardia. Induced ventricular tachycardia was terminated in most instances either by programmed ventricular extrastimulation or overdrive ventricular pacing. Cardioversion was used when the ventricular extrastimulus technique failed or hemodynamic deterioration occurred. Serial drug testing was performed in all patients as previously described.¹ Recordings were obtained on

a Siemens-Elema Mingograph model 82 multichannel recorder and filtered at 50–550 Hz at paper speeds of 100 mm/sec. Pacing and stimulation were performed with a Medtronic 5325 programmable stimulator.

Intraoperative electrophysiologic studies and operative procedure

After cannulation for cardiopulmonary bypass, intraoperative electrophysiologic studies were performed as previously described.^{7,8} Intraoperatively, surface electrocardiographic leads I, II, and III were recorded. Epicardial electrodes were attached to the mid-right atrium and mid-right ventricle to record bipolar right atrial and right ventricular reference electrograms. A bipolar ring or probe electrode was utilized for epicardial and endocardial mapping. Epicardial mapping was performed during sinus rhythm at various predetermined sites according to an area-designated mapping diagram (*Fig. 1*). Epicardial mapping was then performed in clock-like fashion around the aneurysm or area of scar tissue replacement. With the programmed ventricular extrastimulus technique, ventricular tachycardia was induced and the foregoing procedure repeated. After initiation of normothermic cardiopulmonary bypass, a ventriculotomy incision was made, allowing circumferential endocardial mapping 1 and 2 cm from the edges of the aneurysm or scar, respectively (*Fig. 2*). The entire mapping procedure and data analysis required approximately 30 minutes. The area of earliest epicardial activation was compared with the area of earliest endocardial activation to determine the probable site of the anatomic-electrophysiologic substrate responsible for reentrant ventricular tachycardia. An endocardial excision¹⁰ was then performed either through a

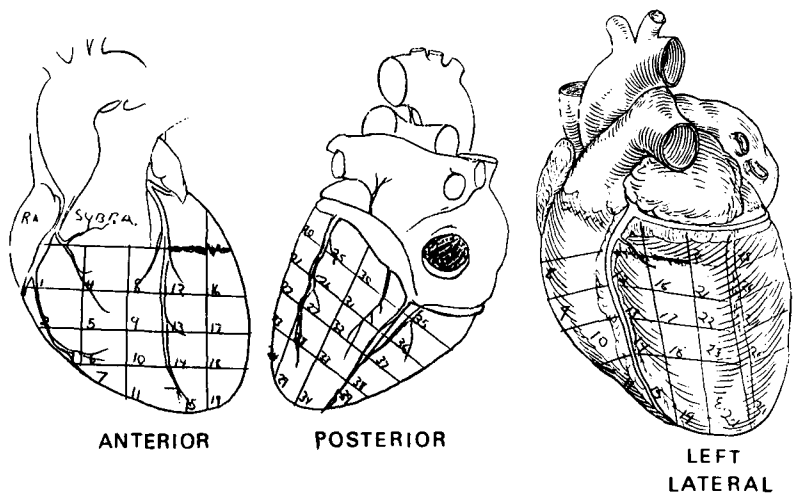


Fig. 1. Area-designated mapping diagram. Bipolar electrograms were recorded from each area during ventricular tachycardia and the area of earliest activation was determined.

ventriculotomy incision or in association with left ventricular aneurysmectomy in an attempt to eradicate the site of origin of the ventricular tachycardia.

At aneurysmectomy, enough full thickness scar was retained to permit effective closure. Endocardial excision involving an estimated 25%–40% of the circumference of the aneurysm extended as far from the edge as necessary to eradicate the previously determined site of origin of the ventricular tachycardia. When only a large patchy scar was present, the endocardial excision was extended as far from the edge of the ventriculotomy incision as necessary. If ventricular tachycardia could not be induced intraoperatively, preoperative electrophysiologic data were used to guide the resection. Aortocoronary bypass grafting was then carried out with the patient under cardioplegic arrest. After rewarming, return to sinus rhythm and termination of cardiopulmonary bypass, but before decannulation, programmed ventricular stimulation was repeated in an attempt to induce ventricular tachycardia. If ventricular

tachycardia could be induced, it was then decided whether to attempt further surgical intervention. The right atrial and right ventricular epicardial pacing wires were left in place for use during postoperative management and for further electrophysiologic testing prior to hospital discharge.

Postoperative evaluation

Electrocardiographic monitoring was continuous for several days and ambulatory Holter monitoring was performed prior to discharge. Repeat electrophysiologic studies were done via the right atrial and right ventricular epicardial pacing wires. Follow-up consisted of reexamination as well as personal communication with each patient’s local physician.

Case 1. A 61-year-old man experienced antero-septal infarction in July 1978. He was referred to The Cleveland Clinic Foundation in September 1981 for evaluation of recurrent episodes of wide QRS complex tachycardia associated with lightheadedness, dyspnea, and chest pain. Physical examination and chest radiograph showed no abnormal-

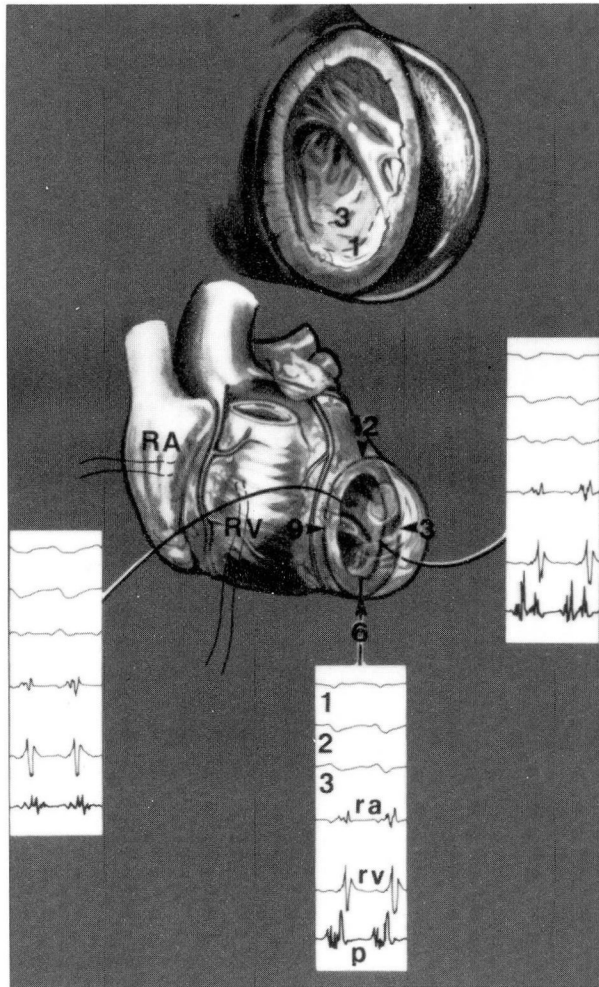


Fig. 2. Diagrammatic representation of intraoperative endocardial mapping. The anterior wall aneurysm has been partially resected. Representative recordings are shown from the 3, 6, and 10 o'clock positions 1 cm from the border zone between scar tissue and normal myocardium. Recordings from above down are surface ECG leads I, II and III, (1, 2, 3) bipolar reference electrograms from the right atrium (*ra*) and right ventricle (*rv*) and bipolar electrograms from the exploring electrode (*p*). Note earliest endocardial activation in the 3 to 6 o'clock position.

ities. The ECG demonstrated sinus rhythm, normal PR interval, right bundle branch block pattern, and signs of remote anteroseptal myocardial infarction.

At cardiac catheterization, the LVEDP was 20 mm Hg. Coronary arteriography showed 30% narrowing in the proximal third of the right coronary artery, total obstruction of the left anterior descending coronary artery proximally, and mild luminal irregularities of the circumflex coronary artery. Left

ventriculography revealed an anterolateral wall left ventricular aneurysm with a small filling defect at the apex, suggesting mural thrombus.

Since he was not a candidate for aneurysmectomy or aortocoronary bypass grafting by the usual criteria, the patient was discharged on an appropriate medical regimen. Five weeks later, sustained ventricular tachycardia necessitated readmission.

During electrophysiologic study, sus-

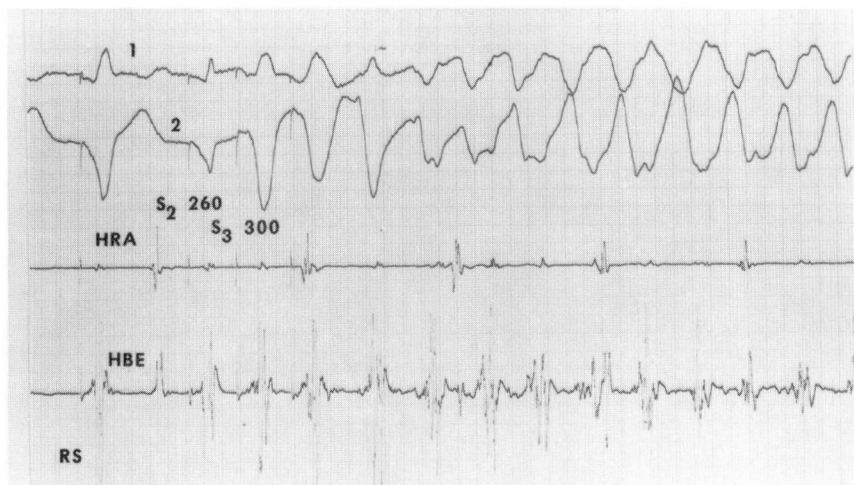


Fig. 3. Induced ventricular tachycardia in Case 1. Recordings from above down are surface ECG leads I and II (1 and 2), bipolar intracardiac electrograms from the high right atrium (HRA) and His bundle region (HBE). During right ventricular pacing at a basic cycle length of 600 msec, the introduction of two ventricular extrastimuli at coupling intervals of 260 and 300 msec, respectively, induced sustained ventricular tachycardia.

tained ventricular tachycardia was easily induced (*Fig. 3*). Serial electrophysiologic testing confirmed refractoriness to antiarrhythmic agents.

At surgery on 30 October 1982, intraoperative mapping during induced ventricular tachycardia showed earliest epicardial activation at areas 18 and 19, corresponding to the lateral wall of the aneurysm. Endocardially, earliest activation occurred at the 4 to 6 o'clock positions (*Fig. 4*). An endocardial excision was performed in this area and at the completion of surgery, sustained ventricular tachycardia could not be induced.

During the postoperative electrophysiologic study with use of the temporary epicardial, atrial and ventricular wires, no abnormal repetitive ventricular beating was identified. The patient was discharged on a regimen of Lanoxin and Lopressor and remains asymptomatic four months postoperatively.

Case 2. A 72-year-old man sustained inferior myocardial infarction on 5 September 1981. He was transferred to The Cleveland Clinic Foundation on the 11th postmyocardial infarction day for evaluation of intermittent wide QRS complex tachycardia.

Physical examination revealed an elevated jugular venous pressure, a laterally displaced, diffuse, sustained apical impulse, and a Grade II/VI holosystolic murmur of mitral regurgitation.

Chest radiograph demonstrated left ventricular prominence and accentuated pulmonary vascularity. Electrocardiogram displayed sinus rhythm, PR interval of 0.24 seconds, right bundle branch block pattern, and signs of recent inferior myocardial infarction. Review of previous electrocardiograms and rhythm strips suggested VT_{RS}.

In the hospital, he suffered an antero-septal myocardial infarction complicated by progressively worsening postinfarction angina, mitral regurgitation, and congestive heart failure. At cardiac catheterization, the LVEDP was 20 mm Hg. Coronary arteriography revealed 75% narrowing of the right coronary artery in its middle third, total obstruction of the left anterior descending in its middle third, and 60% narrowing of the circumflex coronary artery near its origin. Left ventriculography showed a large apical and septal ventricular aneurysm containing thrombus.

During electrophysiologic study, sustained pleomorphic ventricular tachycar-

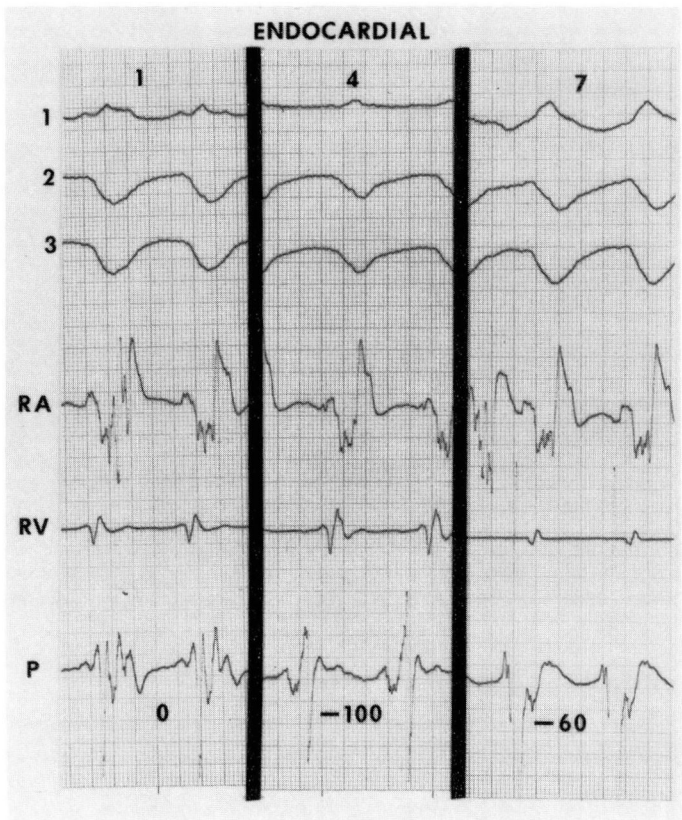


Fig. 4. Intraoperative endocardial mapping during ventricular tachycardia from Case 1. Representative recordings from the 1, 4 and 7 o'clock positions. Recordings from above down are surface ECG leads I, II and III, bipolar reference electrograms from the mid-right atrium (*RA*), mid-right ventricle (*RV*) and exploring probe (*P*). Note earliest endocardial activation at the 4 o'clock position (activity recorded with the probe 100 msec prior to onset of the surface ECG).

dia¹⁵ at 140–216 beats/min was easily induced. Ventricular tachycardia was not well controlled by antiarrhythmic agents, and during repeat electrophysiologic study before surgery, sustained ventricular tachycardia was again induced.

At surgery on 4 November 1981, ventricular tachycardia could not be induced, but a large anterior wall aneurysm was resected. With the preoperative electrophysiologic data as a guide, an extensive endocardial excision was performed encompassing a larger percentage of the circumference of the aneurysm than the usual 25%–40%. Bypass grafts were placed to the right coronary artery, diagonal branch of the left anterior

descending coronary artery and lateral branch of the circumflex coronary artery. Sustained ventricular tachycardia could not be induced postoperatively. The patient was discharged 12 days later with Pronestyl as the sole antiarrhythmic agent. He remains well four months after surgery with no recurrence of ventricular tachycardia.

Case 3. A 63-year-old man suffered an antero-septal myocardial infarction in 1973. Since 1978, he had had intermittent episodes of wide QRS complex tachycardia associated with lightheadedness and chest discomfort. Various conventional antiarrhythmic agents were unsuccessful and cardioversion

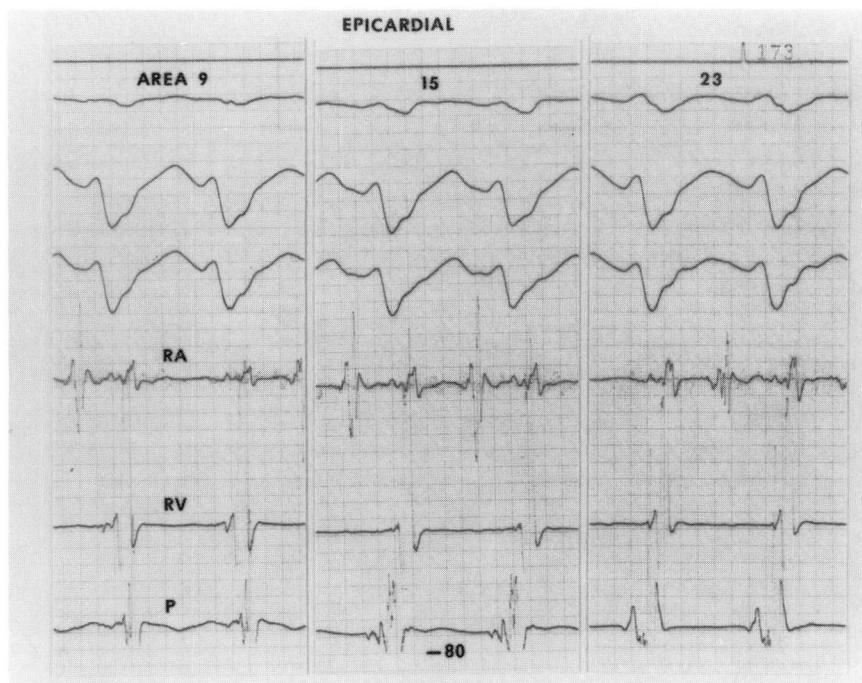


Fig. 5. Intraoperative epicardial mapping during ventricular tachycardia in Case 3. Representative recordings from areas 9, 15 and 23. Recordings from above down are surface ECG leads I, II and III, bipolar reference electrograms from the mid-right atrium (*RA*), mid-right ventricle (*RV*) and exploring electrode (*P*). Earliest activation is in area 15. Activity recorded with the probe occurs 80 msec prior to activity in the right ventricular reference electrode (20 msec prior to onset of the surface ECG).

was required on several occasions. Functional Class III angina pectoris was not well controlled medically. Physical examination and chest radiograph were unremarkable. Electrocardiogram displayed sinus rhythm with normal PR interval and signs of remote anterolateral myocardial infarction. A 24-hour Holter monitor revealed short runs of ventricular tachycardia.

At cardiac catheterization, the LVEDP was 12 mm Hg. Coronary arteriography demonstrated narrowing of 95% in the left anterior descending coronary artery proximally, 80% in the proximal third of a large lateral circumflex branch and 80% in the middle third of the right coronary artery. Left ventriculography showed extensive akinesia involving the anterior wall, inter-ventricular septum, and apex.

During medication-free electrophysiologic study, sustained ventricular tachycardia at

240 beats/min was easily induced. Serial drug testing confirmed refractoriness to medical therapy.

At surgery on 20 January 1982, ventricular tachycardia was easily induced, with earliest epicardial activation in area 15 corresponding to the inferolateral edge of the scar (*Fig. 5*). At ventriculotomy, with these data as a guide, the earliest endocardial activation was localized (*Fig. 6*) and an endocardial excision was performed 2-3 cm laterally. After closure of the ventriculotomy, programmed ventricular extrastimulation again induced ventricular tachycardia, and mapping studies again revealed the same sites of early activation. After further subendocardial resection, the ventriculotomy incision was closed and two bypass grafts were placed with the patient under cardioplegic arrest. Following surgery, multiple attempts were made to wean him from cardiopulmonary

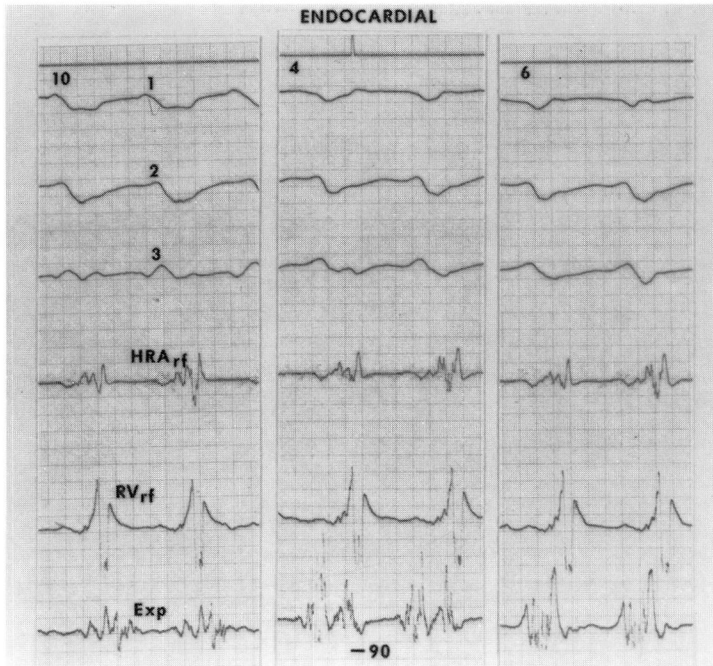


Fig. 6. Intraoperative endocardial mapping during ventricular tachycardia in Case 3. Representative recordings from the 10, 4, and 6 o'clock positions. Recordings from above down represent surface ECG leads I, II and III, bipolar reference electrograms from the mid-right atrium (*HRA_{rf}*), mid-right ventricle (*RV_{rf}*), and exploring probe (*EXP*). Endocardial activity in the 4 o'clock position occurs 90 msec before activity in the right ventricular reference lead and 30 msec before onset of the surface ECG.

bypass with cardiopulmonary medications, intra-aortic balloon pumping, and left ventricular assist device but the patient died.

At autopsy, a large subendocardial hematoma was found to involve the lower half of the left interventricular septum. The hematoma had no obvious connection to the ventriculotomy incision or site of subendocardial resection.

Discussion

Over the past two decades, sporadic reports have described surgical techniques for the management of life-threatening medically refractory ventricular arrhythmias. Many of the techniques, including autonomic modulation (sympathectomy), electrosurgical ablation, and various pacing modalities are described in a recent review by Harken et al.¹² During the early to mid

1970s, reports of standard aneurysmectomy with or without concomitant aortocoronary bypass grafting began to appear in the literature.^{2,3,5} With the exception of a few dramatically successful cases, these interventions were generally unsuccessful and mortality was high. Consequently, enthusiasm for these procedures waned as some investigators cast doubt on their use when the sole indication was control of ventricular arrhythmias.³

Standard aneurysmectomy involves resection of the mature, well-defined, dyskinetic or akinetic myocardium while retaining enough full-thickness scar to permit effective closure. Resection of a portion of the scarred interventricular septum, even if aneurysmal, is avoided. By design, when standard

aneurysmectomy is performed, the anatomic-electrophysiologic substrate in the subendocardial border zone responsible for the ventricular tachycardia is left behind, which probably explains some previously unsuccessful results. Scattered reports of successful cases may be related to improved blood supply associated with aortocoronary bypass grafting. Plication of normal or ischemic myocardium in the border zone may alter the electrophysiologic properties of the offending tissue, rendering induction and maintenance of ventricular tachycardia impossible. The production of small infarctions in the border zone by plication probably explains why most "successful" cases had persistence of VT_{RS} postoperatively followed by a gradual reduction of ventricular irritability over the ensuing weeks.

During the later 1970s, continued advances in laboratory and clinical electrophysiology helped define the mechanisms of ventricular tachycardia and locate its anatomic-electrophysiologic substrate. Because of such advances, enthusiasm for the surgical approach to management was rekindled. Patients with VT_{RS} associated with left ventricular aneurysm formation occurring as a postmyocardial infarction sequela represent one subset of patients in which the offending anatomic-electrophysiologic substrate has been localized.^{4, 9, 16, 17} The solution therefore seemed to involve elimination of the offending subendocardial anatomic-electrophysiologic substrate in the border zone between scar tissue and normal viable myocardium.

Based on these observations, new electrophysiologically guided surgical procedures were described, such as wide resection of the aneurysm extending back to nearly normal myocardium¹⁸ and subendocardial resection.¹⁰

The successful clinical application of various electrosurgical procedures depends on careful consideration of the many variables influencing patient selection, intraoperative electrophysiologic assessment, and surgical approach. All of our three patients had VT_{RS} associated with ischemic heart disease, but in various clinical settings.

The patient in Case 1 was essentially asymptomatic and at minimal risk from loss of additional jeopardized myocardium. There was no indication for surgery other than control of recurrent ventricular tachycardia.

In addition to large areas of jeopardized myocardium, the patient in Case 2 had significant postinfarction angina. The large anterior wall aneurysm had produced intractable congestive heart failure. Aortocoronary bypass grafting and left ventricular aneurysmectomy were necessary regardless of the presence or absence of recurrent ventricular tachycardia. Surgery seemed the reasonable course to eliminate the potential dangers of ventricular tachycardia.

The patient in Case 3 required aortocoronary bypass grafting because of medically refractory angina pectoris, with large areas of myocardium jeopardized by severe triple vessel coronary artery disease. Although discrete ventricular aneurysm formation was not present at the time of surgery, it seemed electrophysiologically sound to make an attempt to control the ventricular tachycardia by excising the offending anatomic-electrophysiologic substrate. Unfortunately, experience is limited in patients who do not have discrete ventricular aneurysm formation, but do have scar tissue replacement of a large portion of the left ventricle. The limitations, complications, and potential for misadventure with this type of surgery have not been well defined.

Certain patients with ischemic heart disease are more likely to develop VT_{RS} than others. The anatomic-electrophysiologic substrate responsible for VT_{RS} seems to be associated with either discrete left ventricular aneurysm formation or large scars. Size seems to be an important predisposing factor since all 24 of our initial patients had either large aneurysms or large scars. Theoretically, all patients with coronary heart disease developing an aneurysm or large scar as a sequela to myocardial infarction could harbor the same anatomic-electrophysiologic substrate capable of producing VT_{RS}. Why many patients are never troubled by recurrent ventricular arrhythmias is not clear.

We conclude that patients with either a history suggestive of VT_{RS} or documented VT_{RS} associated with either left ventricular aneurysm formation or large left ventricular scars should undergo electrophysiologic study to delineate the best approach to management. When cardiac surgery is anticipated in patients with either left ventricular aneurysm formation or large left ventricular scars, and VT_{RS} is neither suspected nor documented, the role of electrophysiologic testing and electrosurgical intervention is less clear.

Given the nature of ventricular tachycardia and the number of poorly defined variables influencing patient selection and electrosurgical results, controlled randomized studies will be difficult. In time, however, the cumulative experience with these procedures should define their effectiveness and application in the treatment of the ventricular tachycardias.

Acknowledgment

The authors would like to express their appreciation to Paula LaManna for techni-

cal assistance in preparation of this manuscript.

References

1. Horowitz LN, Josephson ME, Farshidi A, Spielman SR, Michelson EL, Greenspan AM. Recurrent sustained ventricular tachycardia. 3. Role of electrophysiologic study in selection of antiarrhythmic regimens. *Circulation* 1978; **58**: 986-987.
2. Thind GS, Blakemore WS, Zinsser HF. Ventricular aneurysmectomy for the treatment of recurrent ventricular tachyarrhythmia. *Am J Cardiol* 1971; **27**: 690-694.
3. Sami M, Chaitman BR, Bourassa MG, Charpin D, Chabot M. Long-term follow-up of aneurysmectomy for recurrent ventricular tachycardia or fibrillation. *Am Heart J* 1978; **96**: 303-308.
4. Gallagher JJ. Surgical treatment of arrhythmias. Current status and future directions. *Am J Cardiol* 1978; **41**: 1035-1044.
5. Seeley WC, Oldham HN. Surgical treatment of malignant ventricular arrhythmias by sympathectomy, coronary artery grafts and heart wall resection. [In] Kelly DT, ed. *Advances in the Management of Arrhythmias*. Lane Cove, Australia, Teletronics, 1978, pp 218-224.
6. Ricks WB, Winkle RA, Shumway NE, Harrison DC. Surgical management of life-threatening ventricular arrhythmias in patients with coronary artery disease. *Circulation* 1977; **56**: 38-42.
7. Horowitz LN, Josephson ME, Harken AH. Epicardial and endocardial activation during sustained ventricular tachycardia in man. *Circulation* 1980; **61**: 1227-1228.
8. Josephson ME, Horowitz LN, Farshidi A, Spear JF, Kastor JA, Moore EN. Recurrent sustained ventricular tachycardia. 2. Endocardial mapping. *Circulation* 1978; **57**: 440-447.
9. Josephson ME, Horowitz LN, Farshidi A, Spielman SR, Michelson EL, Greenspan AM. Sustained ventricular tachycardia: evidence for protected localized reentry. *Am J Cardiol* 1978; **42**: 416-424.
10. Josephson ME, Harken AH, Horowitz LN. Endocardial excision: a new surgical technique for the treatment of recurrent ventricular tachycardia. *Circulation* 1979; **60**: 1430-1439.
11. Horowitz LN, Harken AH, Kastor JA, Josephson ME. Ventricular resection guided by

- epicardial and endocardial mapping for treatment of recurrent ventricular tachycardia. *N Engl J Med* 1980; **302**: 589-593.
12. Harken AH, Horowitz LN, Josephson ME. The surgical treatment of ventricular tachycardia. *Ann Thorac Surg* 1980; **30**: 499-508.
 13. Hartzler GO, Maloney JD. Programmed ventricular stimulation in management of recurrent ventricular tachycardia. *Mayo Clin Proc* 1977; **52**: 731-741.
 14. Josephson ME, Horowitz LN, Farshidi A, Kastor JA. Recurrent sustained ventricular tachycardia. 1. Mechanisms. *Circulation* 1978; **57**: 431-440.
 15. Josephson ME, Horowitz LN, Farshidi A, Spielman SR, Michelson EL, Greenspan AM. Recurrent sustained ventricular tachycardia: 4. Pleomorphism. *Circulation* 1979; **59**: 459-468.
 16. Josephson ME, Horowitz LN, Farshidi A. Continuous local electrical activity. A mechanism of recurrent ventricular tachycardia. *Circulation* 1978; **57**: 659-665.
 17. Guiraudon G, Fontaine G, Frank R, Escande G, Etievent P, Cabrol C. Encircling endocardial ventriculotomy: a new surgical treatment for life-threatening ventricular tachycardias resistant to medical treatment following myocardial infarction. *Ann Thorac Surg* 1978; **26**: 438-444.
 18. Allen WB, Maloney JD, Hartzler GO, Holmes DR Jr, Puga FJ. Resection of ventricular aneurysm modified by electrophysiologic assessment in patients with intractable ventricular tachycardia and left ventricular aneurysm (abst). *Am J Cardiol* 1980; **45**: 417.