

Paradoxical thromboembolism associated with heparin therapy

A case report and review of the literature

Jeffrey W. Olin, D.O.
Victor G. deWolfe, M.D.

Department of Peripheral Vascular Disease

Deep venous thrombosis and pulmonary embolism are frequent complications in postoperative and chronically ill patients.¹ Immediate anticoagulation with intravenous heparin is the treatment of choice. However, heparin therapy is associated with a considerable degree of morbidity and mortality.² The major complication is bleeding.³ Other well-known but uncommon complications include allergy, alopecia, and osteoporosis.⁴ Heparin may also cause thrombocytopenia and, paradoxically, arterial and venous thromboembolic disease.⁵⁻²⁶

We recently treated a patient in whom heparin therapy caused thrombocytopenia and arterial emboli. Unless this uncommon, potentially adverse reaction is recognized early and heparin therapy discontinued promptly, the outcome may be disastrous.

Case report

A 73-year-old white woman was admitted to the Cleveland Clinic Hospital on March 21, 1979, because of failure of a right total hip prosthesis.

In 1972 she had had a left total hip replacement for severe osteoarthritis. Postoperatively, bilateral deep vein thrombosis of the lower extremities and pulmonary embolism developed. She was treated with intravenous heparin, 5000 units every 4 hours for 7 days, followed by warfarin sodium therapy. No platelet counts were re-

corded during this hospitalization. In 1974 she underwent a right total hip replacement because of osteoarthritis. She had no postoperative complications. In 1975 atrial fibrillation developed for which she was taking digoxin, 0.25 mg/day. She had a 17-year history of essential hypertension that was well controlled with a thiazide diuretic. The medical history was otherwise unremarkable.

On physical examination, blood pressure was 120/70 mm Hg; pulse, 72 beats/min and regular; respirations, 12/min; and temperature, 37 C by mouth. The lungs were clear to percussion and auscultation. There was a Grade II systolic ejection murmur at the lower left sternal border. There were no extra heart sounds. All peripheral pulses were full and equal bilaterally. There was severe restriction of motion of both hip joints, more on the right than on the left. The remainder of the physical examination was unremarkable.

On March 23, 1979, she underwent another right total hip replacement because of a fracture of the acetabular component of the hip prosthesis. Heparin, 5000 units subcutaneously every 12 hours, was begun immediately postoperatively.

Twelve days postoperatively a left popliteal vein thrombosis developed. She was started on a regimen of heparin, 5000 units every 4 hours, by continuous intravenous drip. The platelet count was 192,000/mm³. Three days later, she complained of pain in her left foot. The foot was cold and the posterior tibial and dorsalis pedis pulses were absent. The platelet count was 39,000/mm³. The following day, she had diminished femoral pulses and pulses were absent at all locations distal to them. A translumbar aortogram showed almost complete occlusion of the abdominal aorta at the level of the bifurcation (*Figure*). Distal aortic, bilateral femoral, and left popliteal embolectomies were performed along with anterior and posterior compartment fasciotomies on the left. Pathologic findings revealed emboli of the platelet-fibrin type with few red blood cells. On April 9, 1979, 2 days postoperatively, the platelet count was 44,000/mm³. The periph-

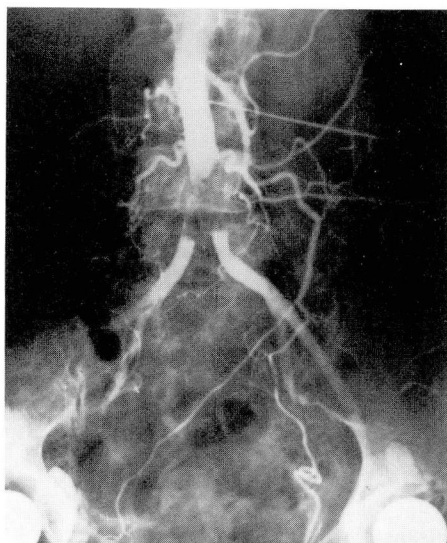


Figure. Translumbar aortogram. Nearly complete occlusion of the abdominal aorta at the level of the bifurcation.

eral smear was otherwise normal. The fibrinogen blood level was 490 mg/dl (normal, 200 to 400 mg/dl). The Thrombowellco test was weakly positive and the protamine paracoagulation test was negative. The prothrombin time was 14 seconds with a control of 12 seconds and the partial thromboplastin time was 25 seconds. Heparin was discontinued and warfarin sodium was begun. Two days later, the platelet count was 119,000/mm³. An echocardiogram failed to reveal mural thrombi.

The platelets aggregated abnormally in the presence of heparin but normally in the presence of adenosine diphosphate (ADP), epinephrine, and collagen.

The patient had irreversible ischemic changes in the left leg and underwent a below-knee amputation. Following this, she had an uneventful recovery and was discharged on a regimen of warfarin sodium therapy.

Discussion

In 1958, Weissmann and Tobin⁵ reported ten cases and in 1964, Roberts et al⁶ described 11 patients who had unex-

plained peripheral arterial emboli while taking subcutaneous or intramuscular heparin for occlusive venous or arterial disease. Pathologically, the emboli consisted of fibrin and platelets and were free of red blood cells and other cellular elements. The emboli were called conglutination thrombi and were believed to be associated with high velocity blood flow.²⁷ Platelet counts of the patients in these studies were not reported. Autopsy specimens of three cases showed that the platelet thrombi originated on a roughened area of the abdominal aorta.⁵ The authors had no definite explanation for this apparent paradoxical effect of heparin. It was speculated that heparin somehow caused distal embolization of these platelet-fibrin thrombi. Roberts et al⁶ suggested that the hypothesis of an antigen-antibody reaction, with the production of antiplatelet factors, warranted further study.

In the 1970s, many case reports im-

plicated heparin as the cause of thrombocytopenia, embolic or thrombotic complications.⁸⁻²⁵ Most reports concerned patients who had received full-dose, intravenous heparin therapy. However, Hrushesky^{13,18} and Galle et al¹⁶ reported several cases of thrombocytopenia in patients receiving low-dose subcutaneous heparin.

In many reports^{9-11, 13, 14, 16-21, 23, 25, 28-31} platelet aggregation studies were performed at the nadir of the platelet counts. It was demonstrated that when the patient's serum was added to normal, platelet-rich plasma, platelet aggregation occurred. Furthermore, if heparin was added to the patient's platelet-rich plasma *after* the thrombocytopenia resolved, the platelets would aggregate. However, this aggregating response was inhibited by adding protamine sulfate to the plasma immediately before the addition of heparin. The protamine sulfate did not inhibit ADP-induced plate-

Table. Incidence of heparin-induced thrombocytopenia

Author	No. of patients	Definition of thrombocytopenia mm ³	Incidence of thrombocytopenia resulting from heparin therapy %
Bell et al ³⁴	16/52	<100,000	30
Justus et al ³⁹	3/50	?	6
Nelson et al ³⁶	9/37	<150,000	24
Malcolm, Wigmore ³⁷	0/25	<100,000	0
Powers et al ³⁸	2/120	<150,000	1.6
Malcolm et al ³³	1/104	<100,000	0.96
Bell, Royall ³⁵		<100,000	
Bovine lung	13/50		26
Intestinal mucosa A	4/45		8.8
Intestinal mucosa O	4/54		7.4
Gallus et al ²⁶		<100,000	
Full dose	5/166		3
Low dose	0/51		0
Ansell et al ³²		<150,000	11.6
Bovine lung	4/21		19
Bovine mucosa	1/22		4.5
Olin, Graor ⁴⁰		<100,000	0.3
Full dose	1/200		0.5
Low dose	0/100		0

let aggregation. Our patient's platelets and serum had such positive responses.

The mechanism by which heparin causes thrombocytopenia is not clear. Many patients had normal bone marrow examinations^{9, 11, 13, 14, 16, 19, 20, 30} and shortened platelet survival time²⁰ suggestive of peripheral destruction of platelets as the mechanism of thrombocytopenia. Several investigators have suggested an immunologic mechanism^{10, 11, 14, 17, 19-22, 32} and have claimed a platelet aggregating factor was detected in the IgG,^{14, 19, 22, 23} IgM,^{14, 20, 22} or IgG/IgA²¹ immunoglobulin fractions. Cines et al²² reported three cases in which the patients had increased platelet IgG and C₃ levels. They concluded that heparin administration can be associated with complement-mediated platelet injury. Others have been unable to prove the existence of an immunologically mediated reaction.^{29, 31, 33.}

The incidence of heparin-induced thrombocytopenia has been reported to be between 0% and 30% (Table). In the first series of Bell et al,³⁴ 16 of 52 patients (30%) had platelet counts less than 100,000/mm³ while receiving beef lung heparin therapy. Ten of these 16 patients had an increase in fibrin degradation products in the serum and 5 of these 10 had hypofibrinogenemia. Recently, Bell and Royall³⁵ showed that heparin-associated thrombocytopenia occurred much less frequently in patients receiving intestinal mucosa heparin than bovine lung heparin. Nelson et al³⁶ detected mild transient thrombocytopenia (88,000 to 150,000 mm³) in 9 of 37 (24%) patients being treated with heparin in a coronary care unit. Other studies cited incidences of 0%,³⁷ 0.96%,³³ 1.6%,³⁸ 3%,²⁶ 6%,³⁹ and 11.6%.³² Our experience shows an incidence of 0.3%.⁴⁰ The incidence of thromboembolic phenomena appears to be even lower, but

no studies have been reported. However, all of the reported cases in which embolic events occurred while heparin was administered, also had low platelet counts when the platelets were measured. In all reported cases, the platelet counts returned to normal between 2 and 15 days after heparin therapy was discontinued.

We recommend periodic platelet counts on all patients receiving heparin therapy because there are no risk factors that predict in whom thrombocytopenia will develop. Because of the potential life-threatening complication of heparin therapy, heparin should be discontinued promptly upon the detection of decreasing platelet counts or in the presence of unexplained recurrent thromboembolic phenomena.

Summary

Thrombocytopenia and arterial embolic events are rare complications of heparin therapy. This patient became thrombocytopenic and had recurrent arterial emboli while receiving heparin therapy. Platelets aggregated abnormally in the presence of heparin, but normally in the presence of ADP, epinephrine, and collagen. The mechanism by which heparin causes thrombocytopenia is not clear, but it is thought to be immunologically mediated. Because serious sequelae may develop, we recommend periodic platelet counts on all patients receiving heparin therapy. The heparin must be discontinued promptly upon detection of decreasing platelet counts or in the presence of unexplained thromboembolic phenomena.

References

1. Salzman EW, Harris WH. Prevention of venous thromboembolism in orthopaedic patients. *J Bone Joint Surg* 1976; **58A**: 903-13.
2. Porter J, Jick H. Drug-related deaths among medical inpatients. *JAMA* 1977; **237**: 879-81.

3. Coon WW, Willis PW III. Hemorrhagic complications of anticoagulant therapy. *Arch Intern Med* 1974; **133**: 386-92.
4. Gervin AS. Complications of heparin therapy. *Surg Gynecol Obstet* 1975; **140**: 789-96.
5. Weissmann RE, Tobin RW. Arterial embolism occurring during systemic heparin therapy. *Arch Surg* 1958; **76**: 219-27.
6. Roberts B, Rosato FE, Rosato EF. Heparin—a cause of arterial emboli? *Surgery* 1964; **55**: 803-8.
7. Gollub S, Ulin AW. Heparin-induced thrombocytopenia in man. *J Lab Clin Med* 1962; **59**: 430-5.
8. Kaupp HA, Roberts B. Arterial embolization during subcutaneous heparin therapy; case report. *J Cardiovasc Surg* 1972; **13**: 210-2.
9. Rhodes GR, Dixon RH, Silver D. Heparin induced thrombocytopenia with thrombotic and hemorrhagic manifestations. *Surg Gynecol Obstet* 1973; **136**: 409-16.
10. Fratanoti JC, Pollet R, Gralnick HR. Heparin-induced thrombocytopenia; confirmation of diagnosis with in vitro methods. *Blood* 1975; **45**: 395-401.
11. Babcock RB, Dumper CW, Scharfman WB. Heparin-induced immune thrombocytopenia. *N Engl J Med* 1976; **295**: 237-41.
12. Baird RA, Convery FR. Arterial thromboembolism in patients receiving systemic heparin therapy; a complication associated with heparin-induced thrombocytopenia. *J Bone Joint Surg* 1977; **59A**: 1061-4.
13. Hrushesky W. Thrombocytopenia induced by low-dose subcutaneous heparin. *Lancet* 1977; **2**: 1286.
14. Rhodes GR, Dixon RH, Silver D. Heparin induced thrombocytopenia; eight cases with thrombotic-hemorrhagic complications. *Ann Surg* 1977; **186**: 752-8.
15. Searcy RA, Marple RN. Heparin and thrombocytopenia. *Ann Intern Med* 1977; **86**: 364.
16. Galle PC, Muss HB, McGrath KM, Stuart JJ, Homesley HD. Thrombocytopenia in two patients treated with low-dose heparin. *Obstet Gynecol* 1978; **52**(suppl): 9s-11s.
17. Green D, Harris K, Reynolds N, Roberts M, Patterson R. Heparin immune thrombocytopenia: evidence for a heparin-platelet complex as the antigenic determinant. *J Lab Clin Med* 1978; **91**: 167-75.
18. Hrushesky WJ. Subcutaneous heparin-induced thrombocytopenia. *Arch Intern Med* 1978; **138**: 1489-91.
19. Trowbridge AA, Caraveo J, Green JB III, Amaral B, Stone MJ. Heparin-related immune thrombocytopenia. Studies of antibody-heparin specificity. *Am J Med* 1978; **65**: 277-83.
20. Wahl TO, Lipschitz DA, Stechschulte DJ. Thrombocytopenia associated with antiheparin antibody. *JAMA* 1978; **240**: 2560-2.
21. Cimo PL, Moake JL, Weinger RS, Ben-Menachem Y, Khalil KG. Heparin-induced thrombocytopenia: association with a platelet aggregating factor and arterial thromboses. *Am J Hematol* 1979; **6**: 125-33.
22. Cines DB, Kaywin P, Bina M, Tomaski A, Schreiber AD. Heparin-associated thrombocytopenia. *N Engl J Med* 1980; **303**: 788-95.
23. Kapsch DN, Adelstein EH, Rhodes GR, Silver D. Heparin-induced thrombocytopenia, thrombosis, and hemorrhage. *Surgery* 1979; **86**: 148-55.
24. Kapsch DN, Silver D. Heparin induced thrombocytopenia. A life and limb threatening complication of heparin therapy. *Mo Med* 1979; **76**: 274-8.
25. Towne JB, Bernhard VM, Hussey C, Garancis JC. White clot syndrome. Peripheral vascular complications of heparin therapy. *Arch Surg* 1979; **114**: 372-7.
26. Gallus AS, Goodall KT, Beswick W, Chesterman CN. Heparin-associated thrombocytopenia: case report and prospective study. *Aust NZ J Med* 1980; **10**: 25-31.
27. Robbins SL. Pathologic basis of disease. 2nd ed. Philadelphia: WB Saunders, 1974: 325.
28. Fidler E, Jaques LB. The effect of commercial heparin on the platelet count. *J Lab Clin Med* 1948; **33**: 1410-23.
29. Hammerschmidt DE. Thrombocytopenia during heparin therapy. *N Engl J Med* 1976; **295**: 1200.
30. Natelson EA, Lynch EC, Alfrey CP Jr, Gross JB. Heparin-induced thrombocytopenia. An unexpected response to treatment of consumption coagulopathy. *Ann Intern Med* 1969; **71**: 1121-5.
31. Bell WR. Thrombocytopenia occurring during heparin therapy. *N Engl J Med* 1976; **295**: 276-7.
32. Ansell J, Slepchuk N, Kumar R, Lopez A, Southard L, Deykin D. Heparin induced thrombocytopenia: a prospective study. *Thromb Haemostas* 1980; **43**: 61-5.
33. Malcolm ID, Wigmore TA, Steinbrecher UP. Heparin-associated thrombocytopenia: low frequency in 104 patients treated with heparin of intestinal mucosal origin. *Can Med Assoc J* 1979; **120**: 1086-8.
34. Bell WR, Tomasulo PA, Alving BM, Duffy

- TP. Thrombocytopenia occurring during the administration of heparin. A prospective study in 52 patients. *Ann Intern Med* 1976; **85**: 155-60.
35. Bell WR, Royall RM. Heparin-associated thrombocytopenia: a comparison of three heparin preparations. *N Engl J Med* 1980; **303**: 902-7.
36. Nelson JC, Lerner RG, Goldstein R, Cagin NA. Heparin-induced thrombocytopenia. *Arch Intern Med* 1978; **138**: 548-52.
37. Malcolm ID, Wigmore TA. Thrombocytopenia induced by low-dose subcutaneous heparin. *Lancet* 1978; **1**: 444.
38. Powers PJ, Cuthbert D, Hirsh J. Thrombocytopenia found uncommonly during heparin therapy. *JAMA* 1979; **241**: 2396-7.
39. Justus PG, Juneja HS, Noyes WD. Heparin associated thrombocytopenia. (Abstr) *Clin Res* 1976; **24**: 17A.
40. Olin J, Graor R. Heparin-associated thrombocytopenia. *N Engl J Med* 1981; **304**: 609.