

Left ventricular assist device support

Twenty-one-month survival

Leonard R. Golding, M.D.
Floyd D. Loop, M.D.
Glenn W. Sandberg, M.D.

*Department of Thoracic and Cardiovascular
Surgery*

Gordon Jacobs, M.S.E.E.
Department of Artificial Organs

Royston C. Lewis, M.D.
Department of Cardiology

Inability to discontinue cardiopulmonary bypass has become an infrequent occurrence because of improved intraoperative myocardial protection with cardioplegia and the use of cardiotonics, peripheral dilators, and intraaortic balloon pumping (IABP). For the patient who cannot be removed from bypass despite these aids, the left ventricular assist device (LVAD) is the last resort. We report the successful use of the LVAD in a patient who could not be weaned from cardiopulmonary bypass after revascularization surgery despite all other modes of therapy.

Case report

A 68-year-old white man with NYHA class IV angina and a prior myocardial infarction was found at cardiac catheterization to have total obstruction of the right coronary artery, 95% left main trunk obstruction, total occlusion of the anterior descending coronary artery, and 90% stenosis of the circumflex. The ventricular function was severely and diffusely impaired with an end-diastolic pressure of 36 mm Hg and an ejection fraction of 30%. On the morning of surgery, immediately before the induction of anesthesia, the patient had chest pain with transient electrocardiographic changes. Anesthesia was induced and he was rapidly placed on cardiopulmonary bypass. Surgery was performed; mild systemic hypothermia (32 C), topical hypothermia, and cardioplegia were used. The anterior descending and distal right coronary

arteries were totally occluded and ungraftable. The diagonal branch, running parallel to the anterior descending artery, was 1.5 mm in diameter and of good quality. The lateral and posterolateral circumflex arteries were about 2.0 mm in diameter and of good quality. Aortocoronary saphenous vein bypass grafts were constructed to the diagonal, lateral circumflex, and posterolateral circumflex coronary arteries. The total aortic cross-clamp time was 31 minutes, and normothermia was achieved while the proximal ends of the grafts were anastomosed to the ascending aorta.

Attempts to discontinue cardiopulmonary bypass failed even with large doses of cardiotonic agents and the use of IABP support via the left femoral artery; left ventricular contractions were visibly feeble. Another period of pump oxygenator support was tried for 30 minutes, but adequate cardiac output could not be maintained when cardiopulmonary bypass flow was decreased to less than 2 to 3 L/min. A temporary partial left heart bypass circuit was instituted by inserting a single 36 F venous cannula through the apex of the left ventricle and then pumping through the standard cardiopulmonary bypass circuit directly back into the aorta. At flows of 3.0 to 3.5 L/min, right ventricular function remained adequate with low-dose isoproterenol; good systemic and low left atrial pressures were maintained. He was supported for approximately one hour, and then with the aid of large doses of cardiotonic agents, the pump support was stopped, but left-sided failure rapidly developed again.

The family was consulted and agreed to the use of our temporary left ventricular assist system.^{1,2} The system is composed of a Medtronic #1861 blood pump, an inflow and outflow cannula composed of wire-reinforced polyvinyl thromboresistant tubing, and a Doppler flow-measuring system, which is mounted on the return cannula. The pump has a single moving part, the impeller/rotor, which generates pressure in proportion to the speed of the impeller with flow being a function of the peripheral resistance. This system produces nonpulsatile blood flow, but simultaneous use of the IABP provided good pulsatility.

A 12-mm bioitized woven Dacron graft was anastomosed end-to-side to the right side of the ascending aorta and through this the return cannula of the assist system was inserted.³ The drainage cannula was positioned through the ventricular apical drainage site and held by tourniquets. Air was carefully removed from the system and the device activated. At 3 L/min flow the patient was easily weaned from cardiopulmonary bypass with a mean arterial pressure of 80 mm Hg and left atrial pressures of 10 to 15 mm Hg. After some time was spent in securing hemostasis, heparin was partially neutralized, appropriate monitoring lines were inserted, and the chest was closed.

The patient was transported to the intensive care unit with the use of a battery mode of the LVAD. When hemostasis was confirmed after an initial period of observation, heparin was continued intravenously to maintain thrombin times at two times normal, and this was continued until the device was removed. Throughout the use of LVAD, pump flow was monitored through the external Doppler flow probe and total systemic blood flow was measured by thermodilution techniques via a pulmonary artery thermister catheter that was inserted at the time of surgery. Pump flows were maintained to provide systemic flows of 4 to 5 L/min (*Table 1*). Initially, there was a complete lack of left ventricular ejection when LVAD flow was transiently discontinued, and the first evidence of returning left ventricular function was seen 12 hours postoperatively. The first attempt to wean the patient from LVAD support was at 42 hours after surgery when good cardiac outputs were measured by ther-

Table 1. Hemodynamic data

Time hr	Pump flow L/min	Cardiac output L/min	LAP mm Hg	Arterial pressure mm
0	3.5	...	5	80
12	3.8	4.5	11	77
24	4.5	4.5	14	80
36	3.4	4.2	14	76
48	4.5	4.5	16	80
60	1.4	4.6	14	80
72	...	3.7	12	90

LAP = left atrial pressure.

modulation despite lowered pump flow. The development of severe ventricular arrhythmias, however, necessitated return to full pump support. A second weaning attempt was begun 54 hours postoperatively, and this time good thermodilution cardiac outputs were maintained over the following 18 hours. At 72 hours after the initiation of LVAD support, he was returned to the operating room and the system was removed. The IABP, which had been functioning through the LVAD support was continued another 48 hours. In the initial hours following LVAD removal, there was a decline in cardiac output with mild elevation of left atrial pressures, which were easily managed with small doses of dobutamine. At no time did cardiac enzyme levels or electrocardiograms show evidence of intraoperative or postoperative myocardial damage. He was extubated on the tenth postoperative day.

Normal renal function remained constant throughout his course without any elevation of serum creatinine or blood urea nitrogen. Furosemide (Lasix) was used during the initial 7 days to help maintain fluid balance. Results of hematologic studies showed that the device was minimally hemolytic as has been shown previously (*Fig. 1*). Gated blood pool thallium ejection studies were performed at 6 and 21 days following operation. The initial value showed an ejection fraction of 0.37, which subsequently improved to 0.52

Table 2. Left ventricular function

Preoperative	
Angiography	
LVEDP	36
EF	30%
Postoperative	
Scan	
POD 6	
EF	37%
POD 21	
EF	52%
Angiography	
8 mo	
LVEDP	12
EF	50%

LVEDP = left ventricular end-diastolic pressure, EF = ejection fraction, POD = postoperative day.

(*Table 2*). His postoperative course was slow and was limited by a left hemiparesis, which became apparent in the immediate postoperative period. He regained complete function of the lower limb, and at the time of discharge there was mild residual impairment of the left upper limb.

Eight months after operation he was readmitted for another cardiac catheterization. He was asymptomatic and fully active. This study showed all grafts to be patent, and the ejection fraction was 50%. The end-systolic phases of the ventriculogram preoperatively and postoperatively are shown in *Figure 2A and B*. At the time of this report it is 24 months since the patient received LVAD support. He is working full time with no restrictions and has mild residual weakness of the left hand only.

Discussion

This case is our first successful result with the LVAD system. The apparatus used in this case differs in two respects from that which we have described previously. The cannulas were larger and had an internal diameter of 9.9 mm. In prior cases we have used a transaortic valve approach for the drainage cannula,⁴ but in this situation an apical drainage system was used because of the larger cannulas. Repeat cardiac catheterization has shown that this apical cannulation has resulted in only a small

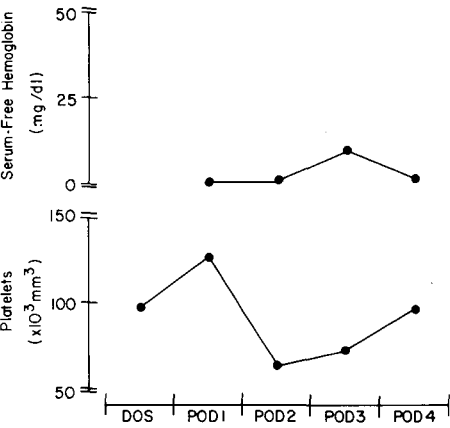


Fig. 1. Daily results of hematologic studies for the first four postoperative days.

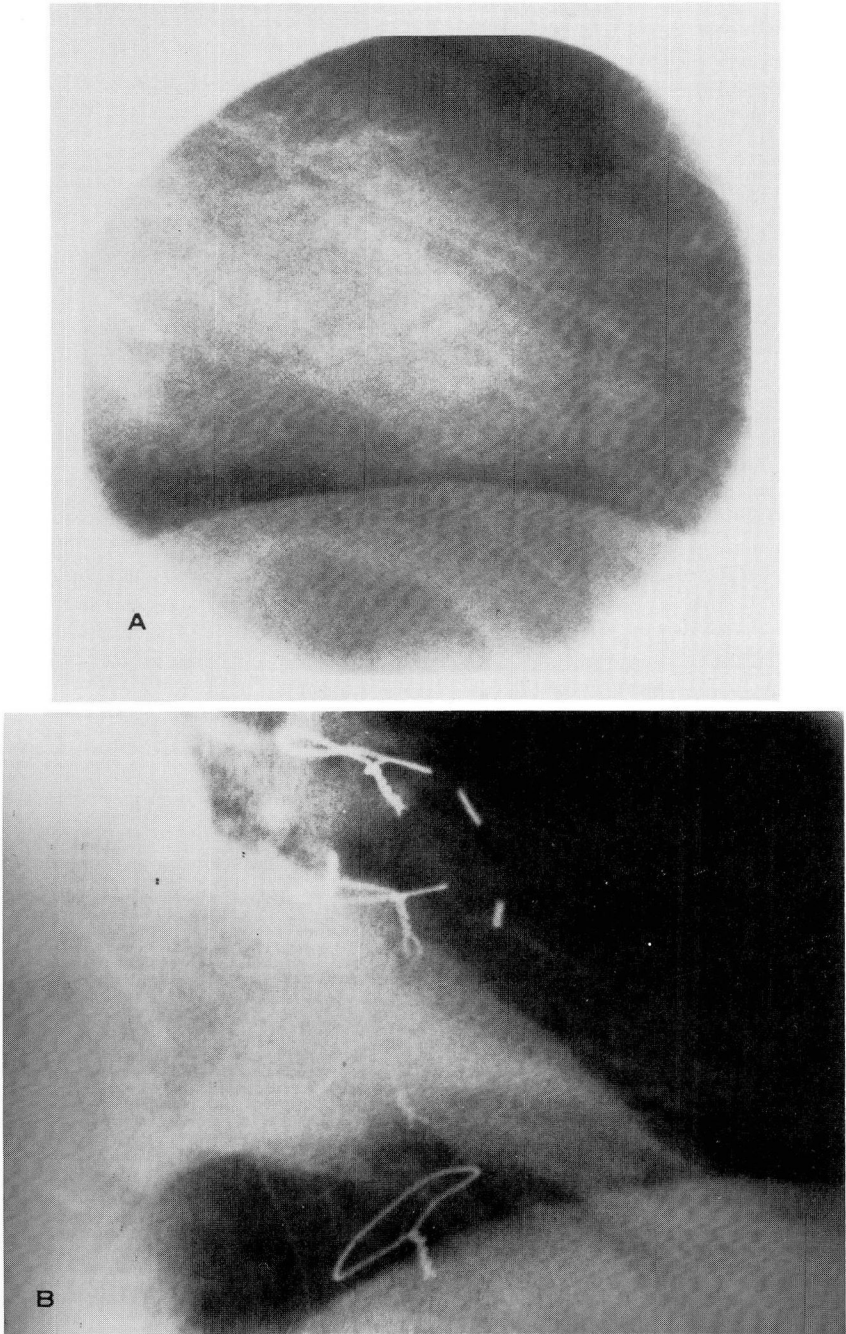


Fig. 2A. Preoperative end-systolic phase of the left ventriculogram. **2B.** Postoperative end-systolic phase of the left ventriculogram.

area of akinesis at the apex of the left ventricle.

This patient differs from previous patients in several aspects. He had minimal evidence of right ventricular failure; electrocardiograms and serum cardiac enzyme levels showed no evidence of new myocardial damage, and there was no problem with postoperative bleeding. He appears to have had a reversible left ventricular injury from which he completely recovered after an appropriate period of support. The occurrence of the left hemiparesis is not completely explained, since there was no thrombus formation found in either the cannulas or the pump. The cause could either be associated with the apical cannula or could be the result of air embolism associated with the procedure.

The long-term survival of this patient

following LVAD support and the documentation of improved ventricular function is encouraging and confirms the concept that LVAD support can be a life-saving device in a selected group of patients.

References

1. Golding LR, Harasaki H, Loop FD, Sukalac R, Reich S, Nosé Y. Use of a centrifugal pump for temporary left ventricular assist system. *Trans Am Soc Artif Intern Organs* 1978; **24**: 93-7.
2. Golding LR, Groves LK, Peter M, et al. Initial clinical experience with a new temporary left ventricular assist device. *Ann Thorac Surg* 1980; **29**: 66-9.
3. Bethea MD, Reemtsma K. Graft hemostasis; an alternative to preclotting. *Ann Thorac Surg* 1979; **27**: 374.
4. Golding L. A simplified blood access method for a temporary left ventricular assist system in humans. *Artif Organs* 1978; **2**: 317-8.