

Endosalpingiosis

Michael D. Holmes, M.D.
Howard S. Levin M.D.

Department of Pathology

Lester A. Ballard, Jr., M.D.

Department of Gynecology

Endosalpingiosis, a term referring to tuballike epithelium in aberrant sites has been reported infrequently.¹⁻⁷ When associated with endometriosis, endosalpingiosis has been regarded as a metaplastic process.⁶ These cases are said to be rare⁸ and are an uncommon cause for psammoma bodies in cul-de-sac fluid. In any patient with psammoma bodies in cul-de-sac fluid, a primary epithelial neoplasm must be excluded. This is a report of a case of endosalpingiosis and psammoma bodies in cul-de-sac fluid, its diagnosis, and possible pathogenesis.

Case report

A 40-year-old gravida I, para 0 white woman was admitted to the Cleveland Clinic Hospital for elective sterilization. Because of a history of endometriosis, premenstrual tension symptoms, and dysmenorrhea, total abdominal hysterectomy and salpingo-oophorectomy was performed. Medical history included remote use of oral contraceptives. Fourteen years earlier she had partial resections of both ovaries and right salpingectomy. Review of the microscopic sections revealed chronic active salpingo-oophoritis involving the right tube and both ovaries. Endometriosis involved both ovaries and the right ovary also contained a dermoid cyst.

Results of the initial physical examination revealed third-degree retroposition of the uterus. External genitalia, vagina, and cervix were unremarkable. No abnormal adnexal masses were palpated. A hysterectomy and

left salpingo-oophorectomy, partial right salpingectomy, and right oophorectomy were performed. In addition to implants of endometriosis, the surgeon described several small cystic lesions over the uterine serosa and pelvic peritoneum; cul-de-sac fluid was obtained for cytologic study at the time of surgery.

Pathologic findings

The specimen consisted of uterus, left fallopian tube, portion of right fallopian tube, and both ovaries. The uterus measured 10 cm from exocervix to fundus, 7 cm from cornu to cornu, and 5 cm in anteroposterior dimension. White to yellow focally translucent, cystic and nodular lesions averaging 0.2 cm in greatest dimension covered the serosa and imparted a coarsely granular quality to its surface. Several serosal lesions had a dark hemorrhagic appearance suggestive of endometriosis. The right ovary measured $4 \times 1.5 \times 2$ cm and had cystic

lesions on its surface similar to those on the uterine serosa. The left fallopian tube and ovary were unremarkable. The segment of the right fallopian tube appeared slightly dilated.

Sections obtained from the ovaries and serosal surface of the uterus were similar. Discrete epithelial foci consisted of acinar and occasional papillary structures. The epithelium resembled that of the fallopian tube containing ciliated, nonciliated, and intercalary cells. The epithelial foci were limited to the surface of the ovaries and uterus (*Fig. 1*). In the cervix, however, a cystic structure lined by tuballike epithelium lay adjacent to mucinous endocervical glands. A fibrous stroma surrounded some of the epithelial areas. None of the epithelial areas had borderline or malignant histologic characteristics such as cytologic atypia, mitoses, or cribriform architecture. Endometriosis was seen in sections near the

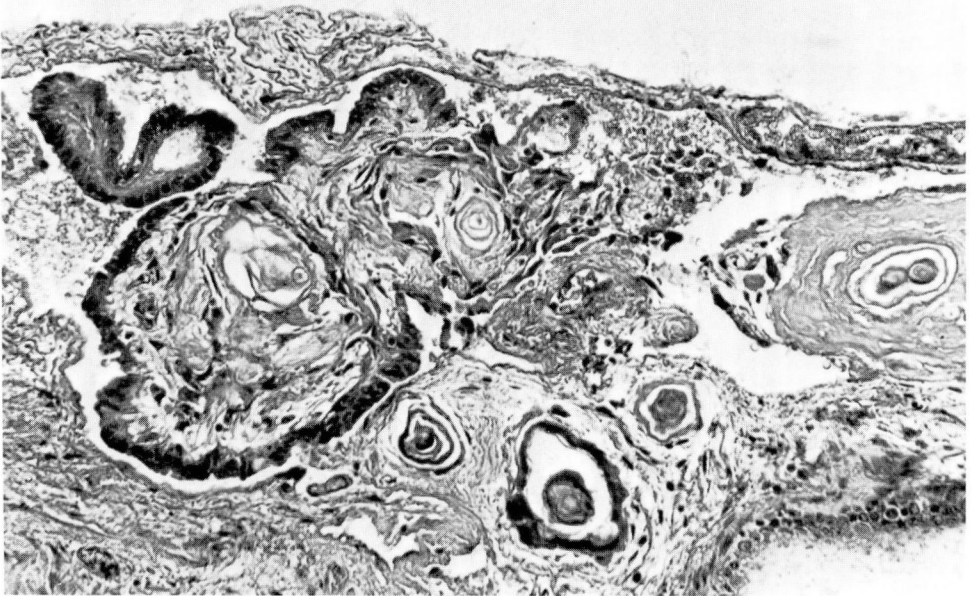

Fig. 1. A section from the serosal surface of the uterus demonstrating papillae, fibrous stroma, and psammoma bodies (hematoxylin and eosin stain, $\times 160$).

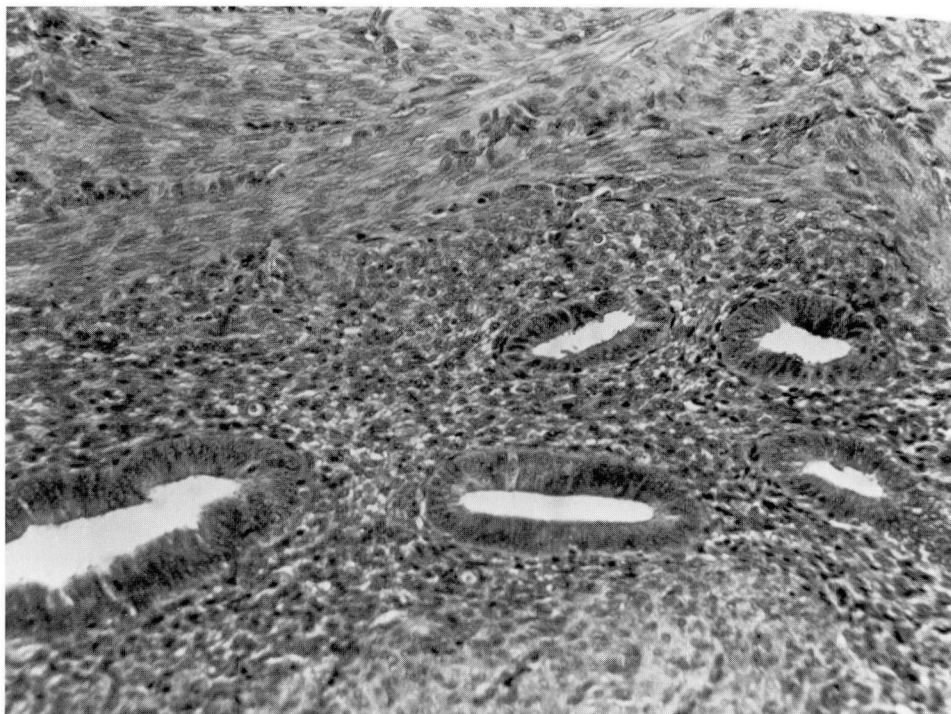

Fig. 2. A section near the serosal surface of the uterus showing endometriosis (hematoxylin and eosin stain, $\times 400$).

serosal surface of the uterus (*Fig. 2*). Cytologically benign cells occasionally in a papillary configuration were seen in smears of the cul-de-sac fluid (*Fig. 3*). Psammoma bodies were present in isolation (*Fig. 4*) and as part of papillary cell groupings.

Discussion

This case was initially presented to the cytopathologist as having numerous psammoma bodies and benign-appearing epithelial cells in a cul-de-sac fluid. It has been emphasized that psammoma bodies obtained from this site are of limited diagnostic value. Psammoma bodies may occur on the surface of the ovary and fallopian tube in the absence of cancer.⁹ The differential diagnosis, however, does include malignant lesions such as serous carcinomas, borderline

tumors, and endometrioid carcinomas. A primary ovarian epithelial neoplasm was suspected because of the presence of epithelial cell groups and psammoma bodies. Examination of the present surgical specimen and subsequent review of the previous partial resections of both ovaries and the right fallopian tube failed to reveal a primary ovarian epithelial neoplasm. Recognition of the implants as having tubal-type epithelium led to a diagnosis of endosalpingiosis.

Normal fallopian tube epithelium consists predominantly of three cell types: ciliated cells, secretory cells, and intercalary cells.¹⁰ The ciliated cells have a lightly staining cytoplasm with the nucleus more apical in location than the nucleus of the secretory cells. The nucleus is often perpendicular to the long axis of the cell. Secretory cells are

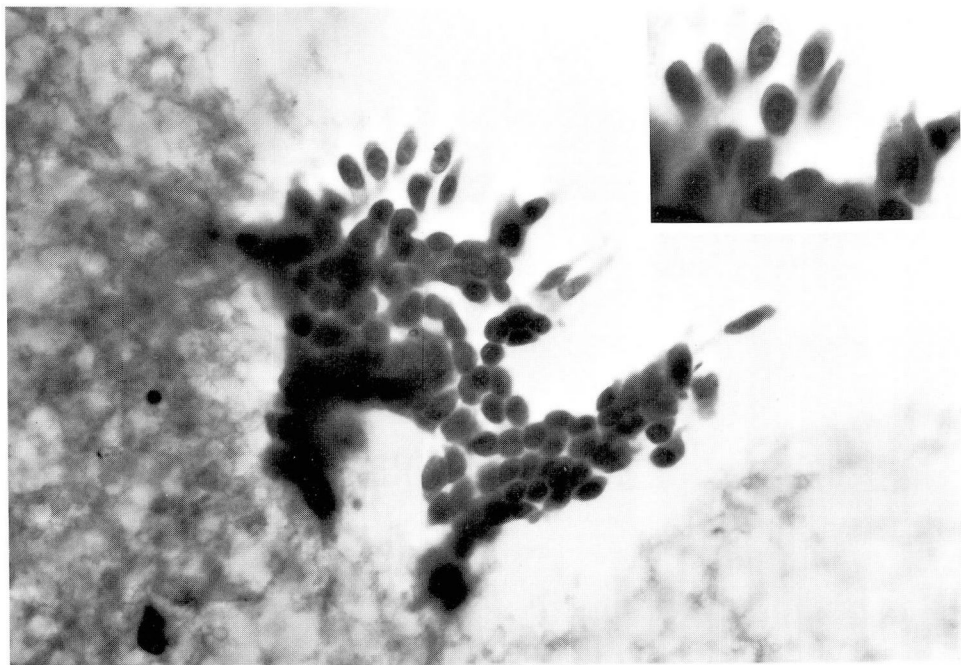


Fig. 3. Cytology of cul-de-sac fluid with a group of cytologically benign epithelial cells ($\times 400$, insert $\times 640$).

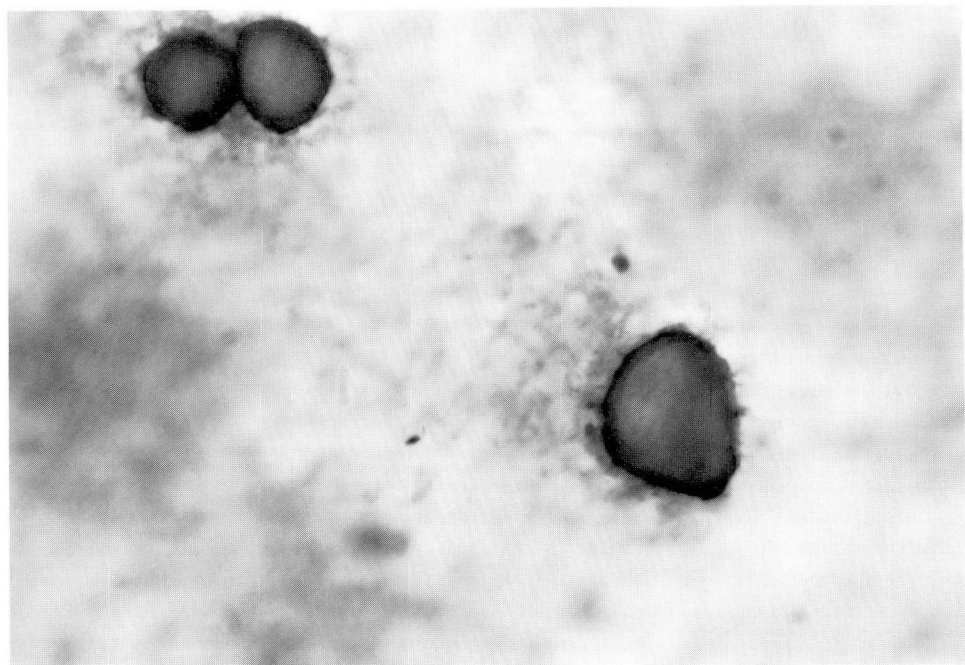


Fig. 4. Psammoma bodies in cul-de-sac fluid ($\times 400$).

nonciliated and have a darker, more uniform cytoplasm than the ciliated cells. The nucleus is more basally located with its axis parallel to the long axis of the cell (*Fig. 5*). The intercalary or peg cells are slender, rodlike cells (*Fig. 6*).

A variety of pathogenetic mechanisms and disease processes have been associated with the histologic finding of tuballike epithelium in aberrant sites. The term endosalpingiosis was used by Sampson³ in 1930 to describe misplaced tubal epithelium in tubal stumps following salpingectomy. Similar ectopic foci of epithelium were found in adjacent structures such as ovary and intestinal wall in some cases. In 1945 he reported ectopic tubal and endometrial epithe-

lium in laparotomy scars following salpingectomies.⁵ He theorized that tubal epithelium has an unusual proliferative potential as a response to the previous tubal injury.

In 1943 Goodall⁴ described several cases of endosalpingiosis and suggested that the process was related to an underlying salpingitis. Some form of tubal injury, such as salpingectomy or inflammation seemed to be a shared feature of these early descriptions of endosalpingiosis.

The finding of tubal epithelium in ectopic sites has also been interpreted as representing a metaplastic process. Benign glandular inclusions in pelvic lymph nodes of women are a well-recognized finding. Such inclusions often

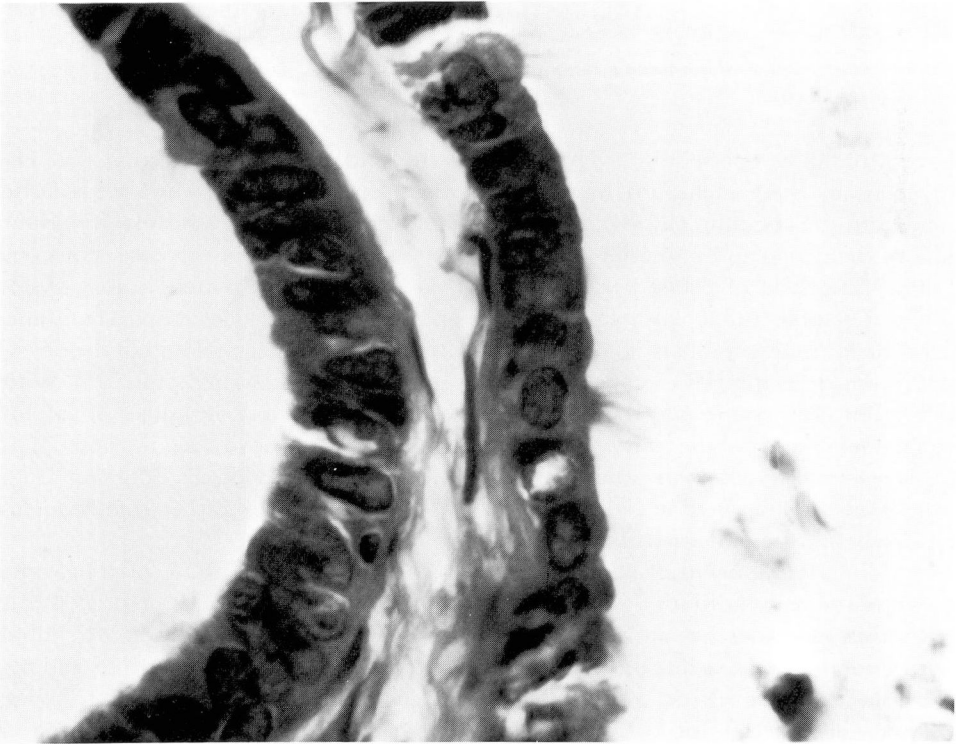


Fig. 5. A serosal implant showing ciliated cells and nonciliated secretory cells (hematoxylin and eosin stain, $\times 640$).

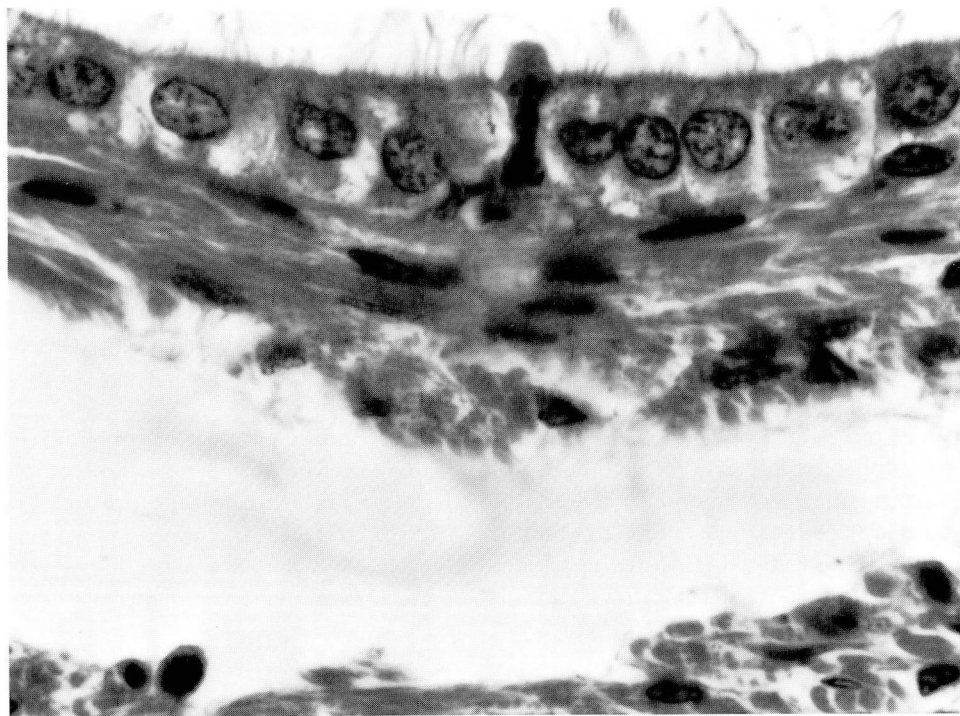


Fig. 6. Serosal implant demonstrating intercalary or "peg" cell amidst many ciliated cells (hematoxylin and eosin stain, $\times 640$).

have a tuballike epithelium.¹¹ The histogenesis of these inclusions has been related to the common embryologic origin of the pelvic and müllerian epithelium. Metaplasia of pelvic peritoneum might resemble tubal epithelium and account for such glandular inclusions.¹¹

Presumed metaplastic capacity of müllerian epithelium may be seen in tubal metaplasia of the endometrium. Cells resembling fallopian tube epithelium have been reported in proliferative and hyperplastic endometrium as well as a cellular component of adenocarcinoma of the endometrium.¹²

In this case there is an association with endometriosis, a disease in which metaplasia has also been considered a pathogenetic mechanism.¹³ One of the two cases of endosalpingiosis reported by Burmeister et al⁶ was also associated

with endometriosis suggesting that endosalpingiosis may also be a metaplastic process representing a histologic variant of endometriosis. In this case, however, the patient had a remote history of salpingitis and salpingectomy, conditions that have also been related to the development of endosalpingiosis.^{4,5,7} With regard to previous instances of salpingitis, implants have been interpreted as being related to direct adhesion from the fallopian tube rather than a metaplastic process.⁷

The histologic finding of tubal-type epithelium in a variety of processes is unquestioned. In addition to tubal metaplasia of the endometrium and benign inclusions in pelvic lymph nodes, tubal-type epithelium has been seen in epithelial foci accompanying cystadenocarcinoma of the ovary.⁶ The identi-

fication of endosalpingiosis as a distinct entity, however, presents a difficult diagnostic problem, especially in interpreting a single biopsy specimen of a peritoneal lesion. The finding of histologically benign tuballike epithelium in such a biopsy specimen does not allow diagnosis of a benign condition with absolute confidence. Several factors might lead to confusion with an implant from a primary ovarian neoplasm such as a serous cystadenoma of borderline malignancy: (1) benign fallopian tube epithelium may be pseudostratified, a histologic finding also seen in borderline tumors¹⁰; (2) ovarian serous neoplasms may include epithelium resembling fallopian tube; (3) borderline histologic changes may be present only focally in a neoplasm that appears histologically benign elsewhere.¹⁴

For these reasons the statement by Scully¹⁵ that, "There are . . . no reliable guidelines by which the pathologist can distinguish true implants of ovarian borderline tumors from atypical foci of endosalpingiosis" seems appropriate especially when evaluating an isolated peritoneal biopsy.

This case report presents endosalpingiosis as a benign entity, perhaps a metaplastic process and variant of endometriosis as suggested by Burmeister et al⁶ or as a result of previous salpingitis.^{4,7} This case also appears to represent one of the rare examples of histologically benign principally peritoneal tuballike epithelial implants without a primary ovarian tumor.⁸ This diagnosis seems secure since both ovaries, prior ovarian biopsies, and fallopian tube specimens were examined and excluded a primary ovarian or fallopian tube epithelial neoplasm. Definite criteria are needed, however, to separate this entity from serous neoplasms. Minimum criteria include careful gross and micro-

scopic examination of both ovaries. In this regard it has been suggested that any serous lesion more than 1 cm in diameter be regarded as a neoplasm.⁸ A history of salpingitis, salpingectomy, or concomitant endometriosis might be considered supportive evidence of endosalpingiosis.

This report emphasizes two points of practical significance: (1) a diagnosis of endosalpingiosis should not be made before a primary ovarian epithelial neoplasm is excluded, since this histologic change may accompany adenocarcinoma of the ovary⁶; and (2) psammoma bodies in cul-de-sac fluid may be present in a histologically benign process. Endosalpingiosis should be considered in the differential diagnosis of psammoma bodies in smears of cul-de-sac fluid.

Summary

The origin of psammoma bodies in cul-de-sac fluid must always be explained. Multiple, histologically benign, predominantly peritoneal foci of tuballike epithelium are described in a woman with endometriosis and psammoma bodies in the cul-de-sac fluid. Because no primary ovarian neoplasm was present, the diagnosis of endosalpingiosis was made. The pathogenesis and significance of endosalpingiosis are discussed.

References

1. Sinykin MB. Endosalpingiosis. *Minn Med* 1960; **43**: 759-61.
2. Powers EG, Hooker ON. Salpingioses (endosalpingiosis); case report. *Texas State J Med* 1948; **44**: 457-9.
3. Sampson JA. Postsalpingectomy endometriosis (endosalpingiosis). *Am J Obstet Gynecol* 1930; **20**: 443-80.
4. Goodall JR. Extrauterine endometriosis. In: *A Study in Endometriosis, Endosalpingiosis, Endocervicosis, and Peritoneo-ovarian Sclerosis*. Philadelphia: Lippincott, 1943: 79-88.
5. Sampson JA. Pathogenesis of postsalpingec-

- tomy endometriosis in laparotomy scars. *Am J Obstet Gynecol* 1945; **50**: 597-620.
6. Burmeister RE, Fechner RE, Franklin RR. Endosalpingiosis of the peritoneum. *Obstet Gynecol* 1969; **34**: 310-8.
 7. Hertig AT, Gore H. Tumors of the female sex organs. Part 3. Tumors of the ovary and fallopian tube. In: *Atlas of Tumor Pathology*. Series 1, fasc. 33, Washington, D.C., Armed Forces Institute of Pathology, 1961: 84-5.
 8. Scully RE. Tumors of the ovary and mal-developed gonads. In: *Atlas of Tumor Pathology*. Series 2, fasc. 16. Washington, D.C. Armed Forces Institute of Pathology, 1979: 55-74.
 9. Koss LG. Tumors of the ovary and fallopian tube. In: *Diagnostic Cytology and Its Histopathologic Basis*. Philadelphia: Lippincott, 1979: 477-91.
 10. Novak ER, Woodruff JD. Histology of fallopian tubes. In: *Gynecologic and Obstetric Pathology*. Philadelphia: W. B. Saunders, 1979: 306-18.
 11. Kempson RL. Consultation case. *Am J Surg Pathol* 1978; **2**: 321-5.
 12. Fruin AH, Tighe JR. Tubal metaplasia of the endometrium. *J Obstet Gynaecol* 1967; **74**: 93-7.
 13. Blaustein A. Pelvic endometriosis. In: *Pathology of the Female Genital Tract*. New York: Springer Verlag 1977; 404-19.
 14. Taylor HC Jr, Alsop WE. Spontaneous regression of peritoneal implantations from ovarian papillary cystadenoma. *Am J Cancer* 1932; **16**: 1305-25.
 15. Scully RE. Ovarian tumors. *Am J Pathol* 1977; **87**: 686-720.