

Prolonged survival of a patient with Richter's syndrome

Report of a 10-year follow-up

Ronald M. Bukowski, M.D.

Department of Hematology and Medical Oncology

Richard A. Savage, M.D.
George C. Hoffman, M.B.,
B.Chir., F.R.C.Path.

Department of Laboratory Hematology and Blood Banking

The development of a diffuse histiocytic (large cell) lymphoma as a "second" neoplasm complicates the course of chronic lymphocytic leukemia in less than 5% of cases.¹⁻⁶ This condition has been termed Richter's syndrome.⁷ Most patients die in a short time without achieving remissions.^{1,2,6} With improvement in chemotherapeutic regimens, an increasing number of patients with diffuse histiocytic lymphoma have achieved long-term, disease-free survivals.^{8,9} We describe a patient who survived 10 years without evidence of disease following the treatment of Richter's syndrome with chemotherapy and radiotherapy.

Case report

A 72-year-old white woman was found to have chronic lymphocytic leukemia at the age of 48. Laboratory studies at another hospital disclosed the following values: white blood count (WBC), $50 \times 10^9/L$; hemoglobin, 10 g/dl; and normal platelet count. Her initial treatment at the other institution included radiation therapy to sites of lymphadenopathy and to the spleen. She was first studied at the Cleveland Clinic when she was 50 years old. Bone marrow aspiration at that time showed an overall hypercellularity with 86% mature lymphocytes. No residual erythroid precursors were noted at that time. A cervical lymph node biopsy specimen was interpreted as lymphosarcoma. She was again treated with splenic irradiation, intermittent infusions of normal plasma, and eventually

with chlorambucil and prednisone, the latter being continued for approximately 4 years. During this time she was symptom free and her blood count gradually became normal; hemoglobin, 12 g/dl; WBC, $6.7 \times 10^9/\text{L}$ with a normal differential and normal platelet count. She remained generally well without treatment for the next 10 years, although periodically lymphadenopathy developed in various lymph node groups. These nodes were treated by local irradiation. In 1970 fever, cough, and malaise developed and she was hospitalized. She had no lymphadenopathy or splenomegaly at that time, but a 6-cm nodular mass developed that was palpable on the liver edge. The liver did not appear to be enlarged on percussion. A liver scan showed a 6×10 -cm mass in the right lobe corresponding to the palpable nodule and a second mass 5 cm in diameter in the left lobe. The bone marrow at this time showed no evidence of lymphocytic leuke-

mia. A liver biopsy was performed, revealing diffuse histiocytic lymphoma. No normal liver tissue was seen on biopsy. She was treated with combination chemotherapy that included cyclophosphamide, 1000 mg, intravenously; vincristine, 2 mg, intravenously; prednisone, 1.5 mg, intravenously every 3 weeks; and cyclophosphamide, 50 mg, orally every day. The liver masses at first regressed but recurred in 6 months. She was given cobalt irradiation to the right upper quadrant over the next 2 months with resolution of the hepatic masses. She has remained in complete remission since that time, with her last examination 10 years since the development of the diffuse histiocytic lymphoma.

Pathology

Diffuse replacement of the entire needle biopsy of the liver by pleo-

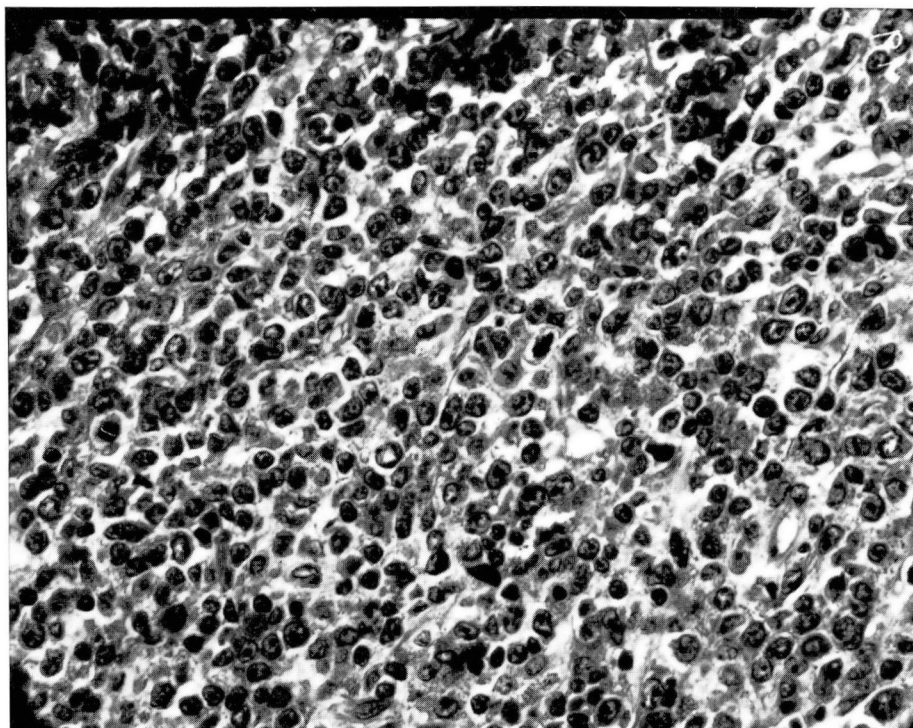


Figure. Liver biopsy showing replacement of the entire specimen by pleomorphic cells with prominent chromocenters fixed to the nuclear membrane, variably sized nucleoli, and moderate amounts of cytoplasm (hematoxylin and eosin stain, $\times 400$).

morphic cells with folded nuclei, prominent irregular basophilic chromocenters fixed to the nuclear membrane, and variably sized basophilic nucleoli were observed (*Figure*). Larger immunoblastic cells with moderate amounts of slightly granular cytoplasm and an occasional cell that appeared to have plasmacytoid differentiation were also observed. No component resembling well-differentiated lymphocytic lymphoma could be identified in this biopsy specimen. The morphology most closely resembled the large cleaved center cell variant of diffuse histiocytic lymphoma.¹⁰

Discussion

Richter's syndrome appears to represent a dedifferentiation of the B-cell neoplasm, chronic lymphocytic leukemia.¹⁻⁶ Immunologic evaluation involving detection and subtyping of surface immunoglobulins has supported the B-cell origin of the diffuse histiocytic lymphoma in Richter's syndrome. In at least one case, subtyping has indicated that the clone of B-cells giving rise to the histiocytic lymphoma is different from that giving rise to the chronic lymphocytic leukemia,⁴ but most patients,² when subtyped with immunofluorescent or immunoperoxidase methods, appear to have the same light and heavy chains present in the histiocytic lymphoma cells as were found on lymphocytes in the original chronic lymphocytic leukemia. The histologic findings vary but all variants include large immunoblastic cells with clumped basophilic chromocenters and variably sized nucleoli as well as giant cell variants mimicking Reed-Sternberg cells.^{2,6} Plasmacytic differentiation and eosinophilic infiltration reminiscent of Hodgkin's disease are not present,⁵ but some cases show a mixture of malignant histiocytes and

well-differentiated lymphocytes in the same anatomic site^{4,6} suggesting evolution of the original malignant lymphoma clone.

The survival of patients with Richter's syndrome has been poor, reflecting the previously poor prognosis of stages III and IV diffuse histiocytic lymphoma. In two previous series^{1,2} the longest survival was 18 months, with a median interval to death of 2.5 months.² Chemotherapy with regimens that have included cyclophosphamide, adriamycin, vincristine, bleomycin, and prednisone^{8,9} have resulted in 40% to 50% of patients achieving prolonged complete remissions and apparent cure with diffuse histiocytic lymphoma. The regimens the patient received are comparable to those reported, and the favorable response indicates that patients with diffuse histiocytic lymphoma and such variants as Richter's syndrome should be treated aggressively with combination chemotherapy. The prolonged response in our patient is consistent with that in previously untreated patients with diffuse histiocytic lymphoma, rather than that in patients who relapse or those in whom a second malignancy develops as a result of previous therapy, such as acute nonlymphocytic leukemia occurring in patients treated with alkylating agents.¹¹ The previous dismal prognosis reported for patients with Richter's syndrome does not reflect the response that can be expected with modern treatment regimens.

References

1. Armitage JO, Dick FR, Corder MP. Diffuse histiocytic lymphoma complicating chronic lymphocytic leukemia. *Cancer* 1978; **41**: 422-7.
2. Foucar K, Rydell RE. Richter's syndrome in chronic lymphocytic leukemia. *Cancer* 1980; **46**: 118-34.
3. Goldstein J, Baden J. Richter's syndrome. *South Med J* 1977; **70**: 1381-2.

4. Splinter TAW, Noorloos ABV, Van Heerde P. CLL and diffuse histiocytic lymphoma in one patient; clonal proliferation of two different B cells. *Scand J Haematol* 1978; **20**: 29-36.
5. Givler RL. Lymphocytic leukemia with coexistent localized reticulum cell sarcoma. *Cancer* 1968; **21**: 1184-92.
6. Long JC, Aisenberg AC. Richter's syndrome; a terminal complication of chronic lymphocytic leukemia with distinct clinicopathologic features. *Am J Clin Pathol* 1975; **63**: 786-95.
7. Richter MN. Generalized reticular cell sarcoma of the lymph nodes associated with lymphatic leukemia. *Am J Pathol* 1928; **4**: 285-92.
8. Miller TP, Jones SE. Chemotherapy of localised histiocytic lymphoma. *Lancet* 1979; **1**: 358-60.
9. Schein PS, DeVita VT Jr, Hubbard S, et al. Bleomycin, adriamycin, cyclophosphamide, vincristine, and prednisone (BACOP) combination chemotherapy in the treatment of advanced diffuse histiocytic lymphoma. *Ann Intern Med* 1976; **85**: 417-22.
10. Strauchen JA, Young RC, DeVita VT Jr, Anderson T, Fantone JC, Berard CW. Clinical relevance of the histopathological subclassification of diffuse "histiocytic" lymphoma. *N Engl J Med* 1978; **299**: 1382-7.
11. Sheibani K, Bukowski RM, Tubbs RR, Savage RA, Sebek BA, Hoffman GC. Acute non-lymphocytic leukemia in patients receiving chemotherapy for nonmalignant diseases. *Human Pathol* 1980; **11**: 175-9.