

An extraordinarily long survival of a patient with inoperable cancer of the breast

George Crile, Jr., M.D.

*Resident Emeritus Consultant;
Department of General Surgery*

Antonio Rodriguez-Antunez,
M.D.

*Chairman, Department of
Radiation Therapy*

This is the report of a woman who has had cancer of the breast for 32 years and is still alive and well. She had the cancer, untreated, for 8 years before it was diagnosed, pronounced inoperable, and treated by radiation. Despite eight posttreatment local recurrences in the next 20 years, the tumor, which histologically is a typical duct-cell carcinoma, has never metastasized either distantly or to regional nodes. At the present time, 24 years after the first treatment and 3 years after a radical plastic procedure that was designed more to bury than to eradicate the cancer, the patient is well and shows no evidence of disease.

Case report

When first examined in 1957, the patient, a 59-year-old woman, had a 2.5-cm cancer of the breast involving the skin and subcutaneous tissue of the central part of the chest, just at the level of cleavage. Surrounding this and scattered through the skin of the upper part of both breasts and the chest wall were six smaller areas of metastases, 0.7 to 1.5 cm in diameter. All of the tumors were hard, flat, pink, and raised (*Fig. 1*). The patient said the central mass of the tumor had appeared 8 years before, and that the satellite nodules had appeared in the last 8 months.

Examination revealed no masses in the breasts, other than the central one at the level of cleavage, and even this seemed to involve the chest wall more than the

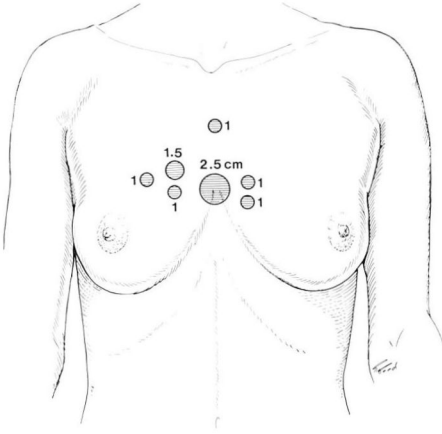


Fig. 1. Distribution of the cancer when patient was first seen.

breasts. It was decided to treat the patient with 250 kV radiation.

A total of 3150 rads was given in 12 treatments to the anterior chest wall in the area in which the metastases had appeared. There was good regression of all but one nodule, which was located at the periphery of the treatment zone, and this was then treated by an additional 2600 rads in nine treatments. Following this the metastases appeared to be completely controlled, but 2 years later three more nodules were treated by 2400 rads in 17 treatments.

The patient had no further trouble for 2 years, but then another nodule appeared in the skin over the lateral part of the left breast. This was treated by contact therapy with a 250 kV machine in a single treatment of 3000 rads. Three months later another nodule was treated by 2000 rads given in five treatments.

The patient remained well until 1967, which was 10 years after the first treatment and 18 years since the cancer had first appeared. At that time a new nodule in the skin above the right breast was treated by a single dose of 1750 rads. Again the patient was free of detectable cancer for 3 years, at which time it was noted that she had scaling of the skin in the center of the telangiectasis caused by the first treatment and that there was a recurrent nodule on the periphery of

the field. This was treated by 2400 rads in 8 days. It did not disappear, but stopped growing, and its growth remained arrested for 7 years. In the meantime the patient was found to have hypertension with blood pressure of 230/118 mm Hg, pulmonary edema, and pleural effusion. Stilbestrol was given, 10 mg daily, because it was suspected that the pulmonary lesions were the result of metastasis. The hypertension also was treated, and the blood pressure fell to 162/

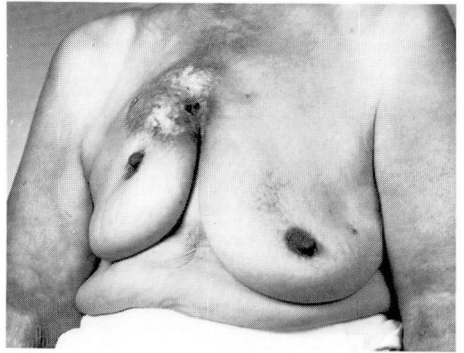

Fig. 2. Ulcerating recurrence of the cancer 20 years after the initial radiation.

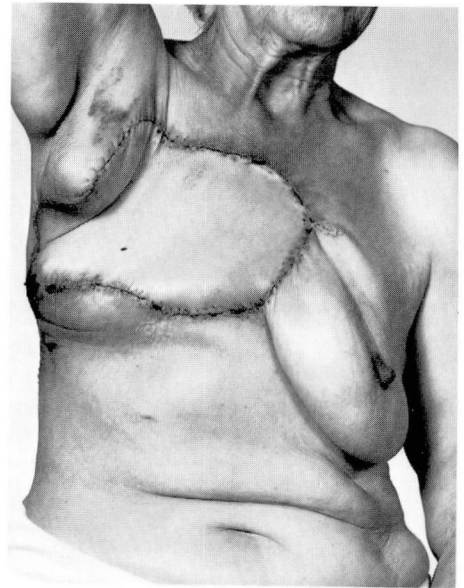


Fig. 3. Patient after the removal of recurrence and plastic reconstruction.

90 mm Hg. It was decided that hypertension and congestive failure, not metastasis, caused the pulmonary lesions. Twenty-nine years had now elapsed since the cancer appeared.

In 1978 the central area of the treated field broke down into a large ulcer, obviously malignant (*Fig. 2*). In consultation with the Department of Plastic Surgery it was decided that Dr. Melvyn Dinner would remove the recurrence and bury the scar under a musculocutaneous flap. Although the patient was 80 years old, she went through the major operation with no difficulty. All gross tumor was widely resected and the latissimus dorsi with attached skin was swung across to cover the defect. An anteromedial flap was swung into the defect left by the latissimus flap and the closure was complete except for two Penrose drains (*Fig. 3*). Convalescence was uneventful and the wound healed primarily. Two weeks later I made a note in the chart "This is a surgical triumph."

Discussion

It is now 2½ years since the operation. The patient is well with no detectable sign of cancer. The pathologist reported that the tumor was an infiltrating ductal carcinoma. Two axillary nodes were free of neoplasm. There were marked radiation changes and also an intraductal papillomatosis as well as an organizing abscess with a sinus tract. In two samples of the cancer the estrogen receptor

concentrations were reported to be less than 3.0. It is now 32 years since the cancer first appeared. The question is, Why did this locally aggressive and locally metastasizing ductal carcinoma fail to spread to nodes or elsewhere despite the fact that it was inoperable from the first and was estrogen-receptor negative?

There is no way to answer the question of why this patient has survived. There is nothing unusual about the microscopic appearance of the cancer. It did not resemble the so-called sweat gland cancers of the skin. It is strange, however, that the largest plaque of cancer in the skin at the time of the initial examination occupied the area of cleavage between the two breasts and did not appear to involve the breast tissue of one any more than the other.

If there is any lesson to be learned from study of this case, it is that radiation therapy is effective in the control of local recurrences in the skin and that there is also a place as well for radical surgery. One cannot help but wonder what would have happened if the radical operation had been done when the patient first was seen. Would the tumor have been disseminated or would it have been eradicated? There is no way to tell.