

Verrucous squamous cell carcinoma of the vagina Case report

Report of a case and review of the literature

Miles J. Jones, M.D.

Howard S. Levin, M.D.

Department of Pathology

Lester A. Ballard, Jr., M.D.

Department of Gynecology

Primary carcinoma of the vagina is an infrequent malignancy of the female genital tract. The overall incidence is between 1% and 2% of all carcinomas of the female genital tract.¹

Verrucous carcinoma was classified by Ackerman² as a distinct variety of squamous cell carcinoma with unique characteristics. The tumor has been recognized in various organs. According to Ramzy et al,³ it was first described by Martens and Tilesius in 1804, and later by Ricord and Traite in 1851. Dawson et al⁴ stated that Buschke reported large condylomatous penile lesions in 1896. This tumor later became known as giant condyloma acuminatum of Buschke-Loewenstein.^{5, 6}

Verrucous carcinoma has been called massive condylomata acuminata, premalignant condylomata acuminata, carcinoma associated with condylomata acuminata, and well-differentiated squamous cell carcinoma.^{4, 7} The various diagnoses have contributed to the impression that this variant of squamous cell carcinoma only rarely involves the female genital tract. To date, approximately 40 cases of verrucous carcinoma involving the female genital tract and only 16 neoplasms involving the vagina have been reported.^{3, 8-14} A case of verrucous carcinoma of the vagina is reported here and the pathology, clinical behavior, and treatment of this unusual neoplasm are discussed.

Case report

A 69-year-old Caucasian woman, gravida 2, para 2, was referred to the Cleveland Clinic for surgical extirpation of a well-differentiated, fungating squamous cell carcinoma of the vagina thought to be verrucous carcinoma. The tumor was discovered 2 months earlier at another hospital. The patient had uterine prolapse for which she had used a pessary for approximately 10 years. Menopause had occurred at age 45. She complained of a thin, foul vaginal discharge for about 2 years prior to admission and used douches frequently. There was no history of vaginal bleeding, bloody discharge, urinary frequency, dysuria, hematuria, stress incontinence, or dribbling.

On pelvic examination, the external genitalia were normal, except for a relaxed vaginal outlet. A second-degree rectocele was evident in the lower vagina. The vagina contained a large fungating tumor of the right posterior wall occupying the upper half of the vagina. The cervix was obscured by the vaginal tumor. The uterus was of normal size. The cul-de-sac and adnexa were free of masses. There was slight thickening of the right paravaginal area. The diagnosis was stage II carcinoma of the vagina.

A vaginal cytologic examination was interpreted as moderate dysplasia with a hemorrhagic background. A vaginal biopsy specimen showed well-differentiated squamous epithelium, pearl formation, dyskeratosis, and dysplasia, but with normal maturation of surface epithelium. The maturation index was in excess of the normal for the patient's age. She was examined under anesthesia; cytoscopy and sigmoidoscopy showed that the lesion was confined to the right posterior vaginal wall (*Fig. 1*). The chest roentgenogram, intravenous pyelogram, and barium-enema roentgenogram were normal. The diagnosis of primary verrucous carcinoma of the vagina was made on biopsy material.

A total vaginectomy, vaginal hysterectomy, bilateral salpingo-oophorectomy, and complete colpectomy were done. Collateral exploration of the periaortic and pelvic wall lymph nodes disclosed no palpable abnormality. The surgical specimen showed the peripheral and deep vaginal margins of re-

section to be free of neoplasm. Shortly after the operation, cardiac arrest developed and despite resuscitative procedures she died. A postmortem examination was not performed.

Pathology

Six vaginal biopsies were submitted for pathologic examination from the first procedure and consisted of slightly verrucous tissue fragments, the largest of which measured up to $1.2 \times 1.0 \times 0.3$ cm. The specimen from the second procedure consisted of vaginal tissue measuring $2.5 \times 7.5 \times 4.5$ cm. Approximately 4.5 cm from the inferior line of resection an elevated firm tan-brown verrucous tumor protruded into the vaginal lumen. The tumor measured $3.5 \times 5.5 \times 4.0$ cm. Cross sections revealed a verrucous, fibrous, tan-yellow trabeculated tissue. The proximal, distal, and lateral lines of resection appeared grossly uninvolved. No abnormalities were present in the cervix or body of the uterus, fallopian tubes, or ovaries.

Microscopically the neoplasm was extremely acanthotic. The rete ridges were rounded and many extended deeply into the underlying connective tissue (*Figs. 2 and 3*). Focal areas of slightly more severe dysplasia, stromal invasion, and a single focus of vascular microinvasion were seen at the base of the lesion (*Fig. 4*). The neoplasm contained few keratin pearls (*Fig. 5*). Neoplastic cells were generally uniform and polygonal with abundant eosinophilic cytoplasm. They contained generally round to slightly irregular nuclei with inconspicuous nucleoli and few mitotic figures. The stroma surrounding the neoplasm was composed of fibrous connective tissue with a mild to moderate plasmacytic infiltrate.

Discussion

Carcinoma of the vagina occurs in women of all ages. In most series the age

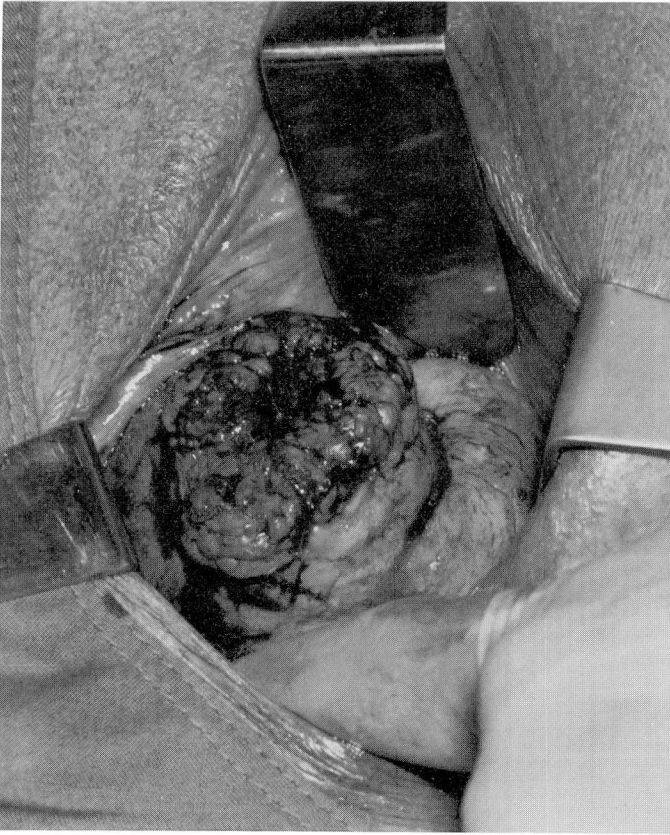

Fig. 1. Verrucous carcinoma of the right posterior vaginal wall measuring approximately 6 to 7 cm. The tumor extends to the right fornix.

range is 45 to 80 years with a median age in the 6th decade.¹⁵⁻¹⁸ Vaginal carcinoma is considered to occur most commonly on the posterior vaginal wall, but it has been found in all locations.¹⁹⁻²³ Numerous reports have appeared associating vaginal carcinoma with long-term use of a pessary.^{24, 25} Based on a series of reviews of carcinoma of the vagina and known reported cases of verrucous carcinoma,^{3, 11-14} we estimate that the incidence of verrucous carcinoma is less than 1% of all vaginal carcinoma.

Verrucous carcinoma of the oral cavity has been linked to the use of tobacco in various forms.^{2, 11} Verrucous carcinoma of the penis has been related to poor hygiene, preexisting condylomata acuminata, and the presence of a prepuce.^{2, 11} No specific cause has been proposed for verrucous carcinoma of the female genital tract.

Clinically the presenting symptoms of verrucous carcinoma of the vagina are secondary to a slowly growing, papillary, fungating, ulcerated mass usually extending over a large area and en-

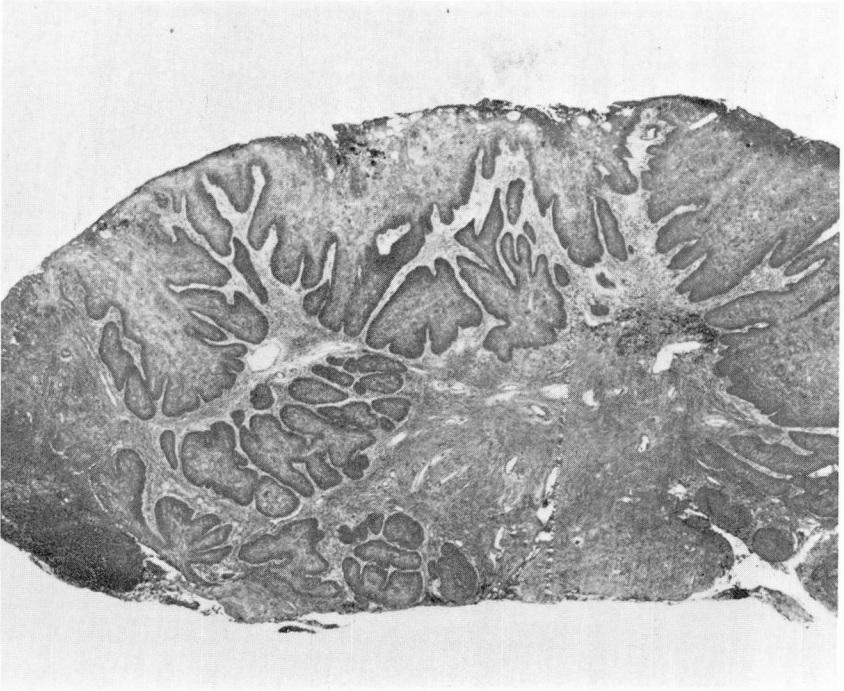


Fig. 2. Low-power illustration of the neoplasm showing marked thickening of epithelium with downward prolongation of epithelium into underlying tissue (hematoxylin and eosin stain, $\times 16$).

croaching on contiguous structures. Infection is frequent and often results in a discharge or an inflammatory response in regional lymph nodes or both. The tumor pushes deeply into underlying tissue, leading to clinical overestimation of the stage of malignancy. Several biopsy specimens may be needed, because the pathologist may not be able to establish the malignancy of the neoplasm due to an insufficient amount of tissue. As is the case with verrucous carcinoma in other areas, the pathologist often may find it necessary to examine the lesion in situ before recognizing its malignant nature.

On gross examination, verrucous carcinoma of the vagina is a fungating or cauliflowerlike, usually tan-brown to

pink, sharply circumscribed, firm tumor.

Histologically the tumor is papillary with superficial maturation, with or without keratinization, and has deep epithelial prongs that are composed of highly differentiated, occasionally vacuolated squamous epithelial cells with minimal nuclear anaplasia and scattered mitotic figures. The basement membrane is mostly intact and the adjacent stroma contains a mixture of inflammatory cells.

For accurate pathologic diagnosis the biopsy specimen must include not only the surface, but the base of the neoplasm as well. If the latter is not included it may be impossible to distinguish verrucous carcinoma from pseudoepithelio-

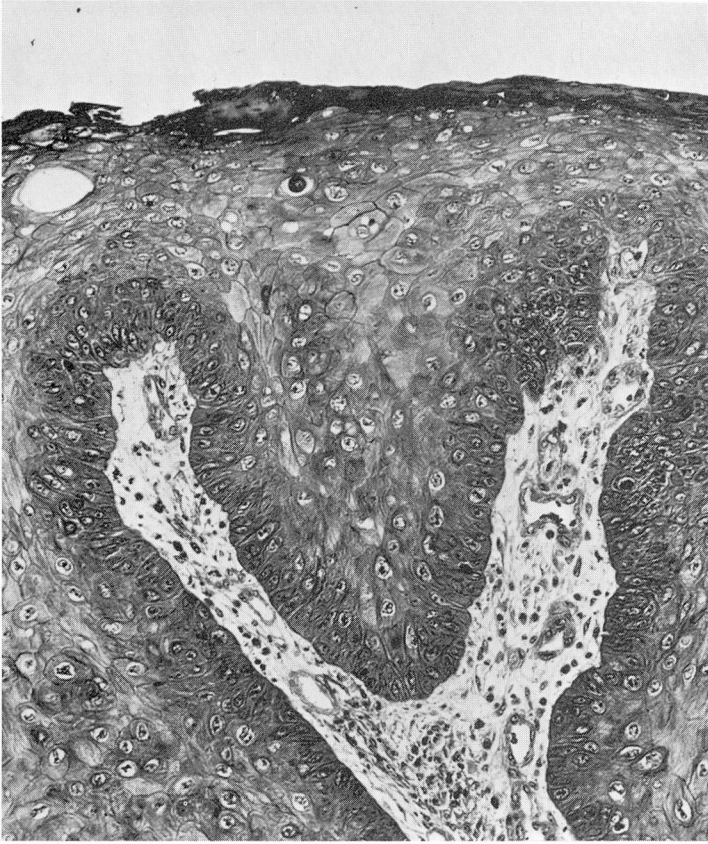


Fig. 3. Luminal surface of verrucous carcinoma showing slight hyperkeratosis with underlying uniform well-differentiated squamous cells containing round nuclei and eosinophilic cytoplasm (hematoxylin and eosin stain, $\times 160$).

matous hyperplasia or a nonverrucous invasive squamous cell carcinoma with maturation of surface epithelium. The latter appears similar superficially, but has more anaplasia of deep layers with more irregular infiltration. Verrucous carcinoma is differentiated from condyloma acuminatum by the absence of discrete central connective tissue cores, infrequent to absent cytoplasmic vacuolation of neoplastic squamous cells, and the presence of invasion. The finding of microfocal invasion of an endo-

thelial-lined space in this case is not typical of this tumor (*Fig. 4*).

Therapy

Many therapeutic approaches have been used for verrucous carcinoma. Clearly podophyllin is contraindicated.²⁶ Chemotherapy has been tried for carcinoma of the vagina, but at present there is no compound specifically effective against this lesion.²⁷ Electrocautery has been proposed,²⁸ but has been abandoned, because it is difficult

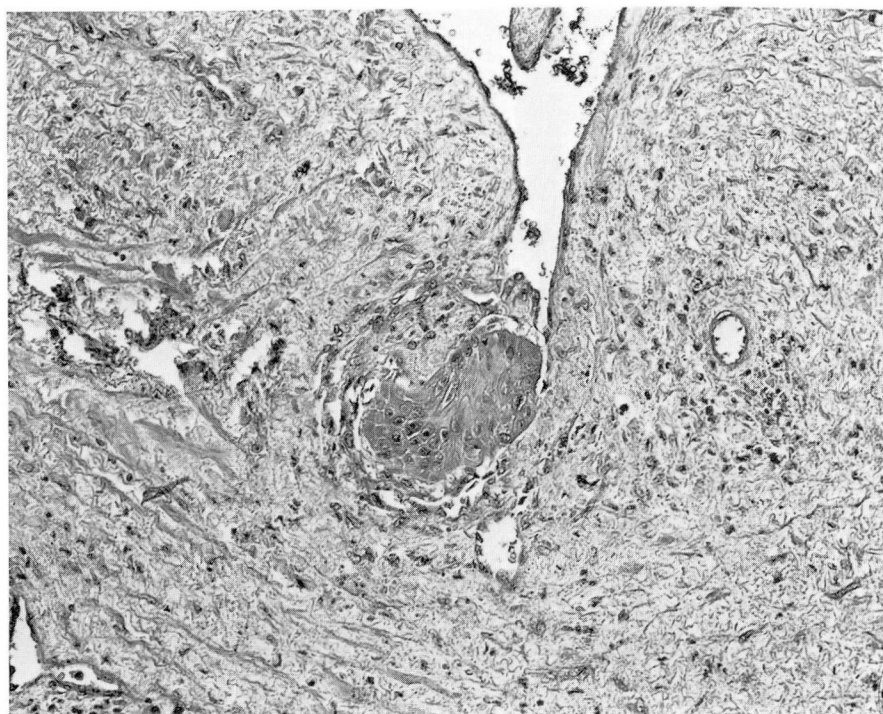


Fig. 4. Section from the depth of the neoplasm with a nest of carcinoma invading beneath the endothelial lining of a vascular space (hematoxylin and eosin stain, $\times 160$).

to ascertain an adequate margin and no specimen is preserved for pathologic evaluation. Simple or local excision yields a high rate of recurrence, since the excision margin usually does not extend sufficiently beyond the periphery of the neoplasm.^{12, 26}

Radiotherapy does not appear to be appropriate treatment for verrucous carcinoma. Ackerman² found a 50% recurrence rate 3 to 7 years following radiotherapy for verrucous carcinoma of the oral cavity. Goethals et al²⁸ and Kraus and Perez-Mesa¹¹ were unsuccessful in curing any of their 14 patients treated by radiotherapy. Radiotherapy should not be used because verrucous carcinoma has a propensity to recur as a more anaplastic carcinoma after such treatment.^{11, 26}

Wide excision seems to yield the best

results in verrucous carcinoma.²⁷ It is unclear at this time whether lymph node dissection is indicated in some cases. Although lymph node involvement is only rarely reported, Gallousis⁷ found 11 of 120 cases of extragenital verrucous carcinoma with lymph node metastasis. We doubt that all of those cases were truly verrucous carcinoma.

Including the case reported here, only 17 cases of verrucous carcinoma involving the vagina have been reported.^{3, 8-14} Of these, nine involved the vagina alone,^{3, 8-12} seven involved both cervix and vagina,^{3, 8, 10, 12-14} and one tumor involved an artificial vagina made of skin.⁹ The average age of the patients was 65 years at the time of diagnosis. Thirteen patients were treated by surgery alone, three were treated by a combination of radiation and surgery, and

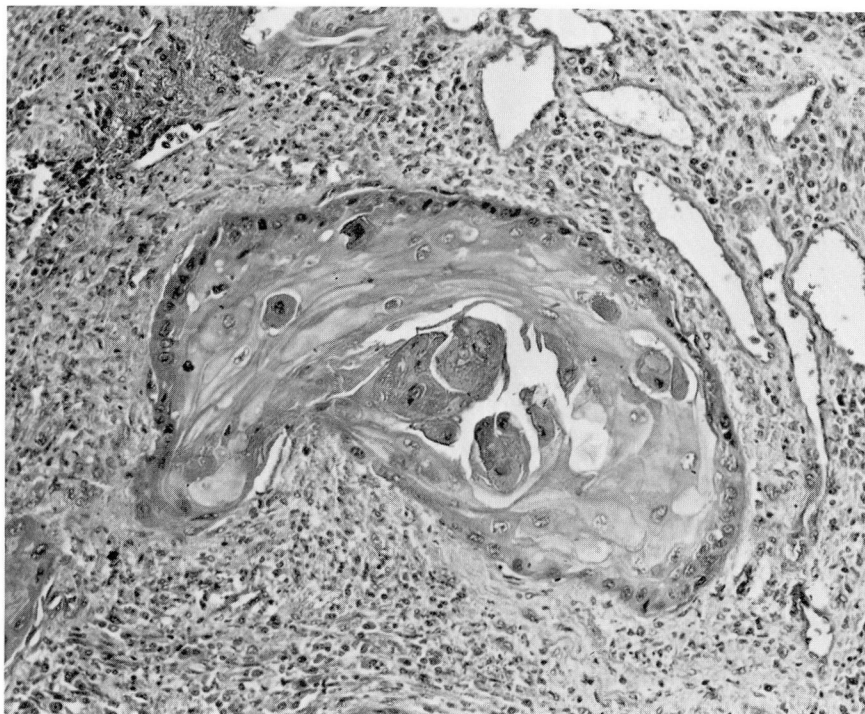


Fig. 5. Section from the depth of the tumor with a peg of well-differentiated, keratinizing verrucous carcinoma invading stroma. A moderate inflammatory reaction is present adjacent to neoplastic cells (hematoxylin and eosin stain, $\times 160$).

one was treated by a combination of radiation and surgery, and one was treated by radiation alone. Three patients died postoperatively, including the case reported and the patient who died of recurrence after surgery. Six of 15 determinate cases had recurrence of neoplasm.^{8, 9, 12-14} Nine patients without recurrence of tumor were alive an average of 23 months after surgery. Of those patients with recurrence, one was alive with tumor 84 months after surgery,¹² and two were alive 14 months¹² and 2 years¹⁵ following the last recurrence. In all four cases not primarily irradiated and in which the tumor recurred, the initial vaginal surgery was partial vaginectomy. This suggests that adequate surgical margins may be difficult to ascertain in such an extremely well-differ-

entiated tumor. All four of these patients had verrucous carcinoma of the cervix and vagina. No surgically treated patient with verrucous carcinoma of the vagina alone has had a recurrence. One of the tumors primarily treated with radiotherapy recurred and the patient eventually died of peritonitis secondary to necrosis of bowel.⁸ A patient with an artificial vagina was treated with irradiation on two occasions for vaginal warts. This patient lived for 19 years and died shortly after surgery of recurrent verrucous carcinoma with focal areas of anaplastic change.⁹ It is impossible to ascertain whether this lesion was a verrucous carcinoma from its inception or was transformed by irradiation. Two patients treated by irradiation and surgery are alive and well 11 and 60

months after radiotherapy.^{10, 11} It would appear that radiotherapy is suboptimal initial therapy if the patient can withstand surgery.

Verrucous carcinoma is a rare neoplasm of the vagina that may be underdiagnosed as condyloma acuminatum or overdiagnosed as exophytic well-differentiated squamous cell carcinoma. Further study of additional cases of verrucous carcinoma of the vagina is needed to define more clearly the biologic behavior of the neoplasm and to determine an optimal treatment regimen. Therapy should be undertaken only after the nature of the lesion has been determined. Presently it seems advisable to excise widely all small lesions or perform radical surgery for larger or recurrent verrucous carcinomas if the patient can withstand the surgery. Two postoperative deaths following initial surgery in 17 patients¹² including the reported case reemphasizes the operative risk in this group of elderly women. Although the number of cases is small, it appears that verrucous carcinoma involving both cervix and vagina has a greater tendency to recur than verrucous carcinoma of the vagina alone. The poor response of verrucous carcinoma in other parts of the body to radiotherapy and its propensity to become more anaplastic after such treatment suggests that recurrences should be treated surgically if possible.¹¹

Summary

A case of verrucous carcinoma of the vagina is reported. Methods of diagnosis and treatment of this neoplasm are discussed, and the English literature concerning verrucous carcinoma of the vagina is reviewed.

Sixteen previous cases of verrucous squamous cell carcinoma involving the vagina have been reported. The neo-

plasm occurs in women at an average age of 63 years. Nine of 15 determinate cases had no recurrence of tumor 5 to 60 months after therapy. Four of six tumors that recurred initially involved both vagina and cervix and were treated by partial vaginectomy. Although documentation and careful follow-up of additional cases are warranted, wide local excision or total vaginectomy together with hysterectomy when the tumor involves the cervix appear to offer the best chance of cure.

References

1. Cramer DW, Cutler SJ. Incidence and histopathology of malignancies of the female genital organs in the United States. *Am J Obstet Gynecol* 1974; **118**: 443-60.
2. Ackerman LV. Verrucous carcinoma of the oral cavity. *Surgery* 1948; **23**: 670-8.
3. Ramzy I, Smout MS, Collins JA. Verrucous carcinoma of the vagina. *Am J Clin Pathol* 1976; **65**: 644-53.
4. Dawson DF, Duckworth JK, Bernhardt H, Young JM. Giant condyloma and verrucous carcinoma of the genital area. *Arch Pathol* 1965; **79**: 225-31.
5. Buschke A, Loewenstein L. Uber carcinomähnliche Condylomata acuminata des Penis. *Klin Wschr* 1925; **4**: 1726-8.
6. Dreyfuss W, Neville WE. Buschke-Loewenstein tumors (giant condylomata acuminata). *Am J Surg* 1955; **90**: 146-50.
7. Gallousis S. Verrucous carcinoma; report of three vulvar cases and review of the literature. *Obstet Gynecol* 1972; **40**: 502-7.
8. Wood WG, Giustini FG, Sohn S, Aranda RR. Verrucous carcinoma of the vagina. *South Med J* 1978; **71**: 368-71.
9. Abrenio JK, Chung HI, Pomante R. Verrucous carcinoma arising from an artificial vagina. *Obstet Gynecol* 1977; **50**: (suppl): 18S-21S.
10. Powell JL, Franklin EW III, Nickerson JF, Burrell MO. Verrucous carcinoma of the female genital tract. *Gynecol Oncol* 1978; **6**: 565-73.
11. Kraus FT, Perez-Mesa C. Verrucous carcinoma; clinical and pathologic study of 105 cases involving oral cavity, larynx and genitalia. *Cancer* 1966; **19**: 26-38.
12. Isaacs JH. Verrucous carcinoma of the female genital tract. *Gynecol Oncol* 1976; **4**: 259-69.

13. Jennings RH, Barclay DL. Verrucous carcinoma of the cervix. *Cancer* 1972; **30**: 430-4.
14. Rorat E, Benjamin F, Richart R. Verrucous carcinoma of the cervix; a problem in diagnosis and management. *Am J Obstet Gynecol* 1978; **130**: 851-3.
15. Arronet GH, Latour JPA, Tremblay PC. Primary carcinoma of the vagina. *Am J Obstet Gynecol* 1960; **79**: 455-60.
16. Bivens MD. Primary carcinoma of the vagina; a report of forty-six cases. *Am J Obstet Gynecol* 1953; **65**: 390-9.
17. Ledward RS. Primary carcinoma of the vagina; a review of 21 cases treated at the Samaritan Hospital for Women 1947-70. *Proc R Soc Med* 1972; **65**: 95-7.
18. Way S. Primary carcinoma of the vagina. (William Blair Bell Memorial Lecture.) *J Obstet Gynaecol Br Emp* 1948; **55**: 739-55.
19. Marcus SL. Primary carcinoma of the vagina. *Obstet Gynecol* 1960; **15**: 673-89.
20. Masterson BJ, Sala JM, Spratt JS Jr. Epidermoid carcinoma of the vagina. *Mo Med* 1962; **59**: 1182-4.
21. Merrill JA, Bender WT. Primary carcinoma of the vagina. *Obstet Gynecol* 1958; **11**: 3-11.
22. Smith FR. Primary carcinoma of the vagina. *Am J Obstet Gynecol* 1955; **69**: 525-37.
23. Underwood PB Jr, Smith RT. Carcinoma of the vagina. *JAMA* 1971; **217**: 46-52.
24. Daw E. Primary carcinoma of the vagina. *J Obstet Gynaecol Br Common* 1971; **78**: 853-6.
25. Kaiser IH. Primary carcinoma of the vagina. *Cancer* 1952; **5**: 1146-60.
26. Lucas WE, Benirschke K, Lebherz TB. Verrucous carcinoma of the female genital tract. *Am J Obstet Gynecol* 1974; **119**: 435-40.
27. Malkasian GD Jr, Decker DG, Mussey E, Johnson CE. Chemotherapy of squamous cell carcinoma of the cervix, vagina, and vulva. *Clin Obstet Gynecol* 1968; **11**: 367-81.
28. Goethals PL, Harrison EG Jr, Devine KD. Verrucous squamous carcinoma of the oral cavity. *Am J Surg* 1963; **106**: 845-51.