

Successful treatment of bleomycin lung

Loren D. Brown, D.O.
Ronald R. Reimer, M.D.

*Department of Hematology and Medical
Oncology*

Muzaffar Ahmad, M.D.

Department of Pulmonary Diseases

James S. Hewlett, M.D.

*Department of Hematology and Medical
Oncology*

Bleomycin sulfate is an antitumor antibiotic with clinical activity against Hodgkin's and non-Hodgkin's lymphoma; squamous cell carcinoma of the head and neck, esophagus, cervix, penis, and skin; and carcinoma of the testis.¹

The major dose-limiting toxicity of bleomycin is pulmonary fibrosis.¹ Factors influencing development of this serious side effect include age, cumulative dose,¹ and prior radiation therapy to the chest.² Although pulmonary fibrosis will develop in less than 10% of patients receiving bleomycin,^{1, 3} treatment of this complication is generally unsuccessful. Some authors have pointed out that early diagnosis and subsequent withdrawal of the drug may prevent progression to fibrosis,^{4, 5} but in most series the irreversible nature of symptomatic bleomycin pulmonary toxicity has been emphasized.^{1, 2} Corticosteroid therapy in particular has been disappointing, with only anecdotal mention of responding patients. We have studied two patients with severe bleomycin pulmonary toxicity who recovered after steroid therapy.

Case reports

Case 1. A 52-year-old white man with stage III choriocarcinoma of the testis with involvement of the supraclavicular, mediastinal, and retroperitoneal nodes was treated with cis-platinum, vinblastine sulfate, and bleo-

mycin chemotherapy. He received 360 mg of bleomycin (180 mg/m^2) for 8 weeks. When the bleomycin was withdrawn, the chest roentgenogram revealed new linear infiltrates in both lung fields. He was asymptomatic and no rales were heard on auscultation. Fourteen weeks later severe dyspnea at rest developed requiring supplemental oxygen therapy. He was afebrile and all cultures were negative.

Open lung biopsy revealed interstitial pneumonitis with fibrosis and focal desquamation. Stain for *Pneumocystis carinii* was negative. Pulmonary function studies were consistent with advanced pulmonary fibrosis, showing a marked restrictive defect with vital capacity (VC) of 1.40 L, forced expiratory volume in one second (FEV_1) of 1.30 L, and pO_2 of 57 mm Hg.

He was treated with prednisone, 80 mg/day, with gradual improvement during the ensuing 3 months. He now has no dyspnea, even with moderate exertion. Pulmonary function studies have greatly improved with VC of 2.73 L, FEV_1 of 2.19 L, and pO_2 of 81 mm Hg. Chest roentgenogram has shown marked clearing (*Fig. 1*).

Case 2. A 32-year-old white man with stage III mixed embryonal teratocarcinoma of the testis metastatic to the left lung, perihilar and periaortic nodes received cis-platinum, vinblastine, and bleomycin chemotherapy. Bleomycin was stopped at a dose of 360 mg (200 mg/m^2).

Four weeks after the bleomycin was withdrawn, severe dyspnea and pleuritic chest pain developed. He was afebrile and physical examination revealed a resting tachycardia and bilateral basilar rales. Chest roentgenogram showed diffuse interstitial and alveolar infiltrates in both lung fields compatible with pulmonary fibrosis. Multiple sputum cultures were negative for bacterial, fungal, and acid-fast organisms. Pulmonary function studies showed a severe restrictive defect with VC of 1.39 L and FEV_1 of 1.20 L. Diffusing capacity for carbon monoxide single breath D_LCO ($\text{ml CO}/(\text{min torr SPTD})$) was 10.2 as compared to 25.7 before treatment. Lung biopsy was not performed.

He was treated with prednisone, 30 mg/

day. In the following 5 months he showed gradual improvement with resolution of symptoms and improved pulmonary functions: VC, 2.48 L; FEV_1 , 2.21 L; and D_LCO , 16.5. Chest roentgenogram has shown complete clearing of both lung fields (*Fig. 2*).

Comment

Bleomycin pulmonary fibrosis was first reported by Ichikawa et al.⁶ Subsequent clinical studies have shown that most patients have the classic picture of interstitial fibrosis, usually similar pathologically to other types of drug-induced fibrosis.⁷

Previous reports of bleomycin lung toxicity have documented its severe nature. Among patients treated with bleomycin to the maximum recommended dose (400 mg), pulmonary dysfunction will develop in up to 10% of patients and 1% to 2% will die of pulmonary fibrosis. With higher doses of bleomycin ($>500 \text{ mg}$), the mortality rate increases from 3% to 5%.² In a review of bleomycin pulmonary fibrosis by Sostman et al.,³ corticosteroids were not considered to be of benefit. Samuels et al.⁸ emphasized the dismal prognosis in patients with the advanced presentation of dyspnea and hypoxemia at rest. Although successful treatment with steroids has been reported,^{1, 2, 4} most responses have been in patients with minimal evidence of pulmonary toxicity or in patients who have received a relatively low cumulative dose of bleomycin. In addition, some of these patients may have had bleomycin hypersensitivity pneumonitis, which responds well to steroids.⁹ Neither of the patients we treated had peripheral blood eosinophilia or other stigmata of hypersensitivity pneumonitis.

In our experience, advanced bleomycin pulmonary fibrosis has not been uniformly fatal. Although the responses after steroid therapy in these two pa-

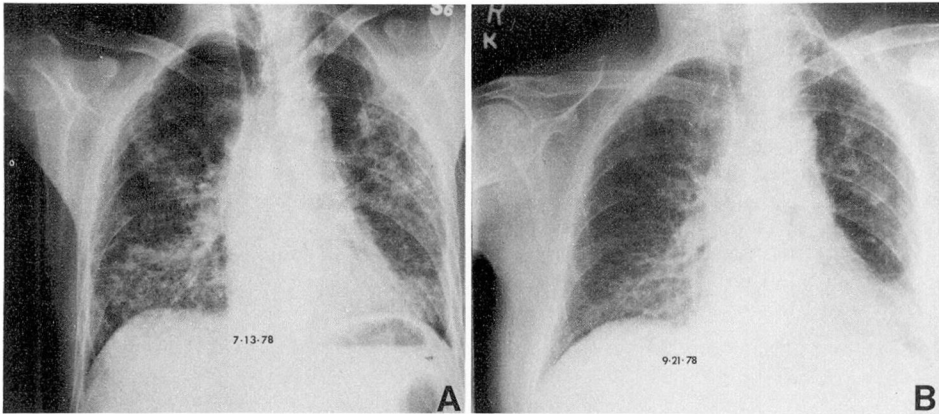


Fig. 1. A, Posteroanterior chest roentgenograms showing bilateral interstitial infiltrates at start of treatment. B, Marked clearing after therapy.

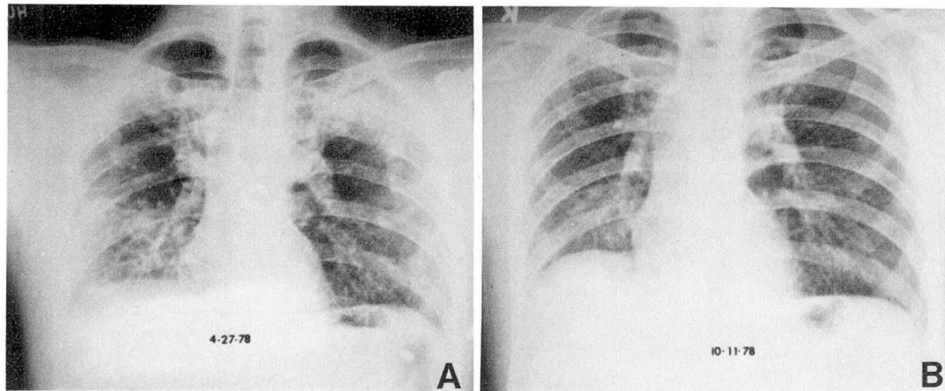


Fig. 2. A, Posteroanterior chest roentgenograms showing bilateral interstitial and alveolar infiltrates at start of treatment. B, Complete clearing after therapy.

tients are gratifying, early recognition and prevention of pulmonary toxicity are essential.

Patients receiving bleomycin should be monitored carefully for the development of pulmonary symptoms. Regular measurement of the lung diffusion capacity and forced vital capacity appear to be the most sensitive studies for detecting early interstitial disease.¹⁰ Differentiation from bleomycin hypersensitivity pneumonitis and other causes of pulmonary infiltrates may provide valuable therapeutic and prognostic information. Finally, prompt withdrawal of bleomy-

cin and early treatment with steroids may prevent progression to an otherwise fatal process.

References

1. Yagoda A, Mukherji B, Young C, et al: Bleomycin, an antitumor antibiotic; clinical experience in 274 patients. *Ann Intern Med* **77**: 861-870, 1972.
2. Samuels ML, Johnson DE, Holoye PY, et al: Large-dose bleomycin therapy and pulmonary toxicity; a possible role of prior radiotherapy. *JAMA* **235**: 1117-1120, 1976.
3. Sostman HD, Matthay RA, Putman CE: Cytotoxic drug-induced lung disease. *Am J Med* **62**: 608-615, 1977.

4. O'Neill TJ, Kardinal CG, Tierney LM: Reversible interstitial pneumonitis associated with low dose bleomycin. *Chest* **68**: 265-267, 1975.
5. Perez-Guerra F, Harkleroad LE, Walsh RE, et al: Acute bleomycin lung. *Am Rev Respir Dis* **106**: 909-913, 1972.
6. Ichikawa T, Nakano I, Hirokawa I: Bleomycin treatment of the tumors of penis and scrotum. *J Urol* **102**: 699-707, 1969.
7. Friedman MA, Carter SB: Serious toxicities associated with chemotherapy. *Semin Oncol* **5**: 193-202, 1978.
8. Samuels ML, Holoye PY, Johnson DE: Bleomycin combination chemotherapy in the management of testicular neoplasia. *Cancer* **36**: 318-326, 1975.
9. Holoye PY, Luna MA, MacKay B, et al: Bleomycin hypersensitivity pneumonitis. *Ann Intern Med* **88**: 47-49, 1978.
10. Pascual RS, Mosher MB, Sikand RS, et al: Effects of bleomycin on pulmonary function in man. *Am Rev Respir Dis* **108**: 211-217, 1973.