

Accuracy of carotid compression tonography in the diagnosis of carotid artery stenosis

Correlation with arteriography in 300 patients

Norman R. Hertzner, M.D.

Department of Vascular Surgery

Thomas G. Santoscoy, M.D.

Department of General Surgery

Roger H. S. Langston, M.D.

Department of Ophthalmology

Considering the success of carotid endarterectomy in the prevention of strokes caused by symptomatic arteriosclerotic lesions of the carotid bifurcation, carotid arteriography is clearly indicated for patients who have had previous hemispheric transient ischemic attacks (TIA) or mild completed strokes. Because of the inconvenience, expense, and slight but measurable risk associated with carotid arteriography, however, noninvasive carotid testing is appropriate for patients who have asymptomatic carotid bruits or nonhemispheric neurologic symptoms (vertebrobasilar syndrome). Provided the incidence of false-negative and false-positive examinations does not exceed acceptable standards, carotid arteriography may ideally be restricted to patients with evidence of substantial carotid artery stenosis.

In 1975, Cohen et al¹ reported the results of noninvasive carotid testing at The Cleveland Clinic Foundation using carotid compression tonography (CCT) in a series of 122 patients who had both CCT and carotid arteriography between April 1972 and March 1974. Of 82 patients who were found by arteriography to have greater than 50% stenosis of the internal carotid or the common carotid arteries, substantial stenosis was correctly predicted by abnormal CCT results in 76 patients (92%) with

an 8% incidence of false-negative results. Ten of the 40 patients who had less than 50% stenosis of the carotid arteries also had abnormal CCT findings for a 25% incidence of false-positive results. Although CCT has continued to be the principal method for noninvasive carotid testing at this institution, several recent reports²⁻¹⁰ have described the accuracy of other noninvasive methods that do not require carotid compression, such as periorbital Doppler examination, oculoplethysmography (OPG), carotid phonoangiography (CPA), and oculopneumoplethysmography (OPPG). The purpose of this report is to correlate the accuracy of CCT testing with carotid arteriography in a series of patients who have been studied since 1974 and to compare these results with those reported for other noninvasive methods.

Materials and methods

This study comprises 300 patients who had CCT and carotid arteriography between April 1974 and October 1977. The 201 men and 99 women in the study group ranged in age from 29 to 86 years (mean, 60 years). Carotid bruits were present in 210 patients and were asymptomatic in 92. A total of 164 patients had experienced previous neurologic symptoms consistent with hemispheric (carotid) TIA in 130 and with nonhemispheric (vertebrobasilar) TIA in 34. Forty-four patients had sustained completed strokes that were hemispheric in 41 and nonhemispheric in three. Eighty of the 300 patients had been scheduled for cardiac, peripheral vascular, or other major surgical procedures and underwent preoperative CCT and carotid arteriography because of previous neurologic symptoms or the presence of asymptomatic carotid bruits.

The technique of CCT has been described.¹ All measurements were made with an electronic recording tonometer (Mueller) on standard recording paper. Compression was applied to the proximal common carotid artery well below the usual location of the carotid bifurcation in order to avoid dislodgement of atheromatous emboli or stimulation of the carotid sinus. A normal CCT result is demonstrated in *Figure 1*. Normal ocular pulsations are symmetrical bilaterally. Compression of the right common carotid artery produces an immediate reduction of intraocular pressure within the right eye, which promptly returns to baseline when compression is released. Since the right internal carotid artery is the source of blood flow to the right ophthalmic artery under normal circumstances, compression of the left common carotid artery produces no pressure response within the right eye. The response to sequential compression of the left and the right common carotid arteries while recording intraocular

CAROTID COMPRESSION TONOGRAPHY NORMAL

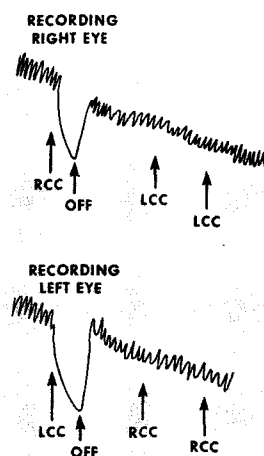


Fig. 1. Recording from a normal CCT test. RCC = right carotid compression, LCC = left carotid compression.

pressure within the left eye is also normal.

Figure 2 demonstrates an abnormal CCT test result in a patient whose left internal carotid artery is occluded. Ocular pulsations are normal on the right, but are reduced in amplitude on the left. Compression of the right common carotid artery while recording the intraocular pressure in the right eye produces an immediate reduction of intraocular pressure, which promptly returns to baseline when compression is released. No change in intraocular pressure within the right eye occurs during left carotid compression. However, left carotid compression produces only slight reduction of intraocular pressure within the left eye because the occluded left internal carotid artery is no longer the principal source of blood flow to the left ophthalmic artery. In this case, considerable blood flow to the left ophthalmic artery is provided by the right internal carotid artery via crossover collateral

flow through the anterior communicating artery. Consequently, right carotid compression produces a measurable reduction of intraocular pressure within the left eye. Although occlusion of the internal carotid artery has been used as an example, similar changes in ocular pulsations and responses to compression are expected to occur in the presence of substantial stenosis of the internal carotid or the common carotid artery, the magnitude of these changes depending upon the severity of the stenosis.

A CCT result was considered to be normal in this study if ocular pulsations were symmetrical and of adequate amplitude, if ipsilateral carotid compression produced a prompt reduction of intraocular pressure and release of compression was associated with brisk recovery, and if no pressure response occurred during contralateral carotid compression. Conversely, reproducible variance of any of these parameters was considered to be abnormal with reduction of intraocular pressure during contralateral carotid compression representing the most objective finding. Precise interpretation of minimal or bilaterally symmetrical changes in ocular pulsations or responses to ipsilateral carotid compression may be difficult in the absence of a measurable response to contralateral carotid compression. Such changes may be caused by technically inadequate ipsilateral carotid compression as well as by occlusive arterial disease and offer no reliable information concerning the status of the carotid arteries. These responses were customarily termed "marginal" by those interpreting CCT result during the study period. For the calculations used in this report, marginal findings were considered as abnormal since they must logically be resolved by arteriography.

All CCT tests and carotid arterio-

**CAROTID COMPRESSION TONOGRAPHY
OCCLUSION OF LEFT CAROTID ARTERY**

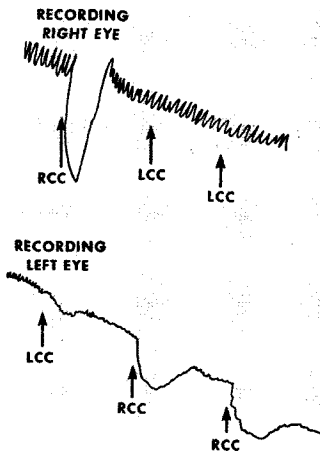


Fig. 2. Recording from a CCT test in a patient who had occlusion of the left internal carotid artery. RCC = right carotid compression, LCC = left carotid compression.

grams for the 300 patients in this study were independently reviewed to confirm the reliability of the original interpretations. The percentage of carotid stenosis was determined using a millimeter scale by dividing the diameter of the remaining lumen at the point of maximum stenosis in the internal carotid artery by the diameter of the normal internal carotid artery distal to the atheroma, or in the event that the stenotic lesion was within the distal common carotid artery, by the diameter of the common carotid artery proximal to the atheroma. Although such a measurement does not absolutely reflect the overall reduction in cross-sectional lumen area, it is the only feasible method to evaluate the extent of occlusive arterial disease demonstrated by biplanar arteriography.

Results

The results of carotid arteriography are classified according to indications for investigation in *Table 1*. Of 92 patients who had asymptomatic carotid bruits, 32 (35%) had less than 50% ste-

nosis of the extracranial internal carotid or common carotid arteries. The remaining 60 patients (65%) had at least one focal extracranial stenosis of 50% or greater, and 28 patients (30%) had greater than 90% stenosis or occlusion of at least one internal carotid artery.

Forty (23%) of 171 patients who had previous hemispheric TIA or mild completed strokes had normal extracranial carotid arteriograms. An additional 108 patients (63%) had focal extracranial stenosis of 50% or greater, and 76 patients (44%) had greater than 90% stenosis or occlusion of at least one internal carotid artery. In comparison, 11 (30%) of the 37 patients who had nonhemispheric neurologic symptoms had normal extracranial carotid arteriograms, and focal extracranial carotid stenosis of 50% or greater was found in 16 (43%).

Correlation of the results of carotid arteriography and CCT is given in *Table 2*. Of the 300 CCT tests included in this study, 103 were interpreted as definitely normal, 160 as definitely abnormal, and 37 as marginal. Eighty-one (78%) of normal CCT examinations were associated with arteriographically normal carotid arteries or less than 50% carotid stenosis. Therefore, if 50% stenosis of the internal carotid or common carotid artery is designated as the critical value at which noninvasive testing should become positive, the overall false-negative rate was 22%. Eight (8%) of the 103 normal CCT results were associated with greater than 90% stenosis or occlusion of at least one internal carotid artery.

Of 160 patients who had abnormal CCT results, 145 (91%) had at least one extracranial carotid stenosis of 50% or greater. Therefore, the false-positive rate was 9% for the total of 263 CCT tests for which definite interpretations were possible. Since 22 patients who had less than 50% stenosis underwent carotid ar-

Table 1. Results of carotid arteriography classified according to indications for investigation in 300 patients

Maximum arteriographic stenosis	Indications for investigation				
	Asymptomatic carotid bruit	Previous neurologic symptoms			
		Hemispheric		Nonhemispheric	
		TIA	Stroke	TIA	Stroke
Normal	10	30	10	11	0
<50%	22	16	7	9	1
50%-75%	18	10	4	3	0
75%-90%	14	15	3	2	0
>90%	13	32	6	4	2
Occlusion	15	27	11	5	0
Total	92	130	41	34	3

teriography on the basis of marginal CCT results, however, these examinations must also be considered as false-positive for a total rate of 19% (37/197).

It is generally conceded that occlusive arterial lesions do not interfere with blood flow until they attain a minimum of 70% stenosis as measured by biplanar arteriography. For this reason, any method of noninvasive carotid testing should be especially dependable for detection of higher grades of stenosis. Considering 118 patients who were found by arteriography to have normal extracranial carotid arteries or less than 50% carotid stenosis, 81 (69%) had normal CCT results. Of a total of 37 marginal CCT results, 22 (60%) occurred in patients who had less than 50% carotid stenosis. The false-negative rate for 182 patients who had at least 50% carotid

stenosis on arteriography was 22%, but this figure was reduced to 13% with 75% stenosis, to 8% with 90% stenosis, and to only 2% in the presence of internal carotid artery occlusion.

Reduction of intraocular pressure during compression of the contralateral common carotid artery is the CCT parameter that is least susceptible to technical artifact. The influence of crossover blood flow on the predictive accuracy of CCT is given in Table 3. Of the 124 patients who were considered to have measurable reductions in intraocular pressure during contralateral carotid compression, 116 (94%) had greater than 50% extracranial carotid stenosis, 108 (87%) had at least 75% stenosis, 88 (71%) had at least 90% stenosis, and 47 (38%) had internal carotid artery occlusion.

Table 2. Correlation of the results of carotid arteriography with CCT interpretation in 300 patients

Maximum arteriographic stenosis	CCT interpretation					
	Normal		Abnormal		Marginal	
	Patients	Percent	Patients	Percent	Patients	Percent
<50% (118)	81	78	15	9	22	60
50%–75% (32)	9	9	14	9	9	25
75%–90% (34)	5	5	27	17	2	5
>90% (59)	6	6	51	32	2	5
Occlusion (57)	2	2	53	33	2	5
Total	103	100	160	100	37	100

Table 3. Influence of crossover blood flow on the predictive accuracy of CCT in 300 patients

Contralateral crossover blood flow	CCT interpretation	Maximum arteriographic stenosis				
		50%	50%–70%	75%–90%	90%	Occlusion
Present, 124 patients	Patients (No.)					
	Normal
	Abnormal (117)	4	7	19	41	46
Absent, 176 patients	Marginal (7)	4	1	1	...	1
	Normal (103)	81	9	5	6	2
	Abnormal (43)	11	7	8	10	7
Total	Marginal (30)	18	8	1	2	1
		118	32	34	59	57

When crossover response to contralateral carotid compression was absent, interpretation of CCT results was limited to less specific parameters, such as the amplitude of ocular pulsations and the slope of the intraocular pressure responses to ipsilateral carotid compression and release. Under such circumstances, 22 (21%) of 103 CCT results that were considered normal were associated with over 50% carotid stenosis on arteriography. Conversely, 11 (26%) of 43 patients who were considered to have abnormal CCT results were found to have less than 50% carotid stenosis on arteriography. In addition, 30 of 37 marginal CCT results did not have crossover flow. Eighteen (60%) of these 30 had less than 50% stenosis on arteriography, and 26 (87%) had less than 75% stenosis.

The accuracy of noninvasive carotid testing recently has been expressed in terms of *sensitivity* and *selectivity*. By definition, a highly sensitive noninvasive method detects the presence of significant carotid stenosis with a low incidence of false-negative results, and a highly selective method excludes hemodynamically insignificant lesions with a low incidence of false-positive results. These terms are mathematically expressed as:

$$\text{Sensitivity} = \frac{\text{number of abnormal noninvasive examinations}}{\text{total number with significant stenosis on arteriography}} \times 100\%$$

$$\text{Selectivity} = \frac{\text{number of normal noninvasive examinations}}{\text{total number without significant stenosis on arteriography}} \times 100\%$$

If 50% carotid stenosis is designated as the critical value at which noninvasive carotid testing should become positive, the sensitivity of CCT in the 300 patients in this study was 88% (160/182), and the selectivity was 69% (81/118). Considering 75% carotid stenosis as the critical value, the sensitivity of

CCT was 91% (136/149), and the selectivity was 60% (90/150).

Discussion

Although false-positive results of noninvasive carotid testing obligate some patients with normal or nearly normal carotid arteries to unnecessary carotid arteriography, the consequences of false-negative studies are even more critical since arteriography may not be considered for other patients who do have significant extracranial occlusive disease. Therefore, sensitivity assumes greater clinical importance than selectivity, especially for detection of higher grades of carotid stenosis. False-positive results of CCT may be attributed to technically inadequate ipsilateral carotid compression or to undetected arteriographic occlusive lesions within the petrosal segment of the internal carotid artery, the intracranial carotid siphon, or the ophthalmic artery. False-negative results commonly are caused by substantial collateral blood flow entering the orbit from the ipsilateral external carotid artery or by the presence of bilaterally symmetrical carotid occlusive disease, both of which may preclude any crossover response to contralateral carotid compression even in the presence

of substantial internal carotid artery stenosis. In this study, 13 patients with normal CCT results had internal carotid stenosis of 75% or greater demonstrated by arteriography. Ten of these patients had patent ipsilateral external carotid arteries and several had collateral intra-

cranial flow through the orbit. Only two patients had unexplained false-negative CCT results.

The data presented in *Table 4* indicate that the accuracy of CCT compares favorably with that previously reported²⁻⁸ for periorbital Doppler examination, OPG, CPA, and OPPG, irrespective of the severity of carotid artery stenosis designated as the critical value at which noninvasive carotid testing should become positive. Considering lesions measuring greater than 50% stenosis on arteriography, a total of 59 patients in the present study had either false-positive (19%) or false-negative (22%) CCT results for an overall accuracy of 80%, a sensitivity of 88%, and a selectivity of 69%. Most importantly, the false-negative rate is only 13% for 75% carotid stenosis, 8% for 90% carotid stenosis, and 2% for internal carotid occlusion.

Kartchner and McRae⁹ and Gross et al.⁴ have reported that the accuracy of noninvasive carotid diagnosis is enhanced by the use of both OPG and CPA as complementary studies. Similarly, we believe that the accuracy of

CCT testing may be improved in selected patients by the addition of periorbital Doppler examination to reduce the incidence of false-negative results. Since some false-negative results are caused by substantial collateral blood flow from the external carotid artery in the presence of substantial ipsilateral internal carotid stenosis or occlusion, periorbital Doppler examinations in such patients would demonstrate reversal of flow in the supraorbital artery and should be considered for patients who have normal CCT results despite impressive asymptomatic carotid bruits or nonhemispheric neurologic symptoms.

Since hemispheric symptoms commonly are caused by cerebral microembolization from ulcerated extracranial arteriosclerotic lesions unassociated with any measurable degree of carotid artery stenosis, noninvasive carotid assessment alone is inappropriate for patients who have had TIA or mild, completed strokes manifested by unilateral extremity paresis or anesthesia, aphasia, or monocular visual loss. Such patients require complete carotid arteriography, but it is obvious from the number of

Table 4. Comparison of accuracy of CCT with other methods of noninvasive carotid testing

Noninvasive method	Carotid stenosis, %	Overall accuracy, %	False-positive, %	False-negative, %
CCT	50	80	19	22
	75	76	30	13
Doppler	60 ⁶⁻⁸	51-74	0-6	36-49
	75 ⁴	59	31	41
OPG	50 ^{2,3}	90 ³	8-19	12-48
	60 ⁷	86	15	12
	75 ⁴	85
CPA	50 ²	...	7	66
	75 ⁴	68
OPG/CPA	50 ⁵	44	65	42
	75 ⁴	89	3	8
OPPG	50 ⁵	62	40	33
	60 ^{6,7}	85-97	0	6-15
	75 ⁴	31	19	50

patients with distinct hemispheric symptoms included in our own study that this axiom deserves emphasis. Noninvasive carotid testing, however, is indicated and may be invaluable for the following patients.

1. Patients with asymptomatic carotid bruits. In our opinion, patients who have asymptomatic carotid bruits and abnormal CCT results should have carotid arteriography and should undergo elective surgical correction of documented extracranial carotid stenosis to reduce the incidence of subsequent strokes. Supportive evidence concerning the risk of asymptomatic carotid bruits has been reported by Kartchner and McRae⁹ who found that strokes occurred within a mean interval of 24 months following discovery of asymptomatic bruits in 12% of patients with abnormal noninvasive carotid test results compared to 2% of those with normal noninvasive studies.

2. Patients with nonhemispheric neurologic symptoms (vertebrobasilar syndrome). Neurologic symptoms referable to the posterior circulation, which are associated with carotid artery stenosis may be improved by carotid endarterectomy. Since carotid lesions must be hemodynamically significant to produce nonhemispheric symptoms, it has been suggested that patients who have vertebrobasilar syndrome and normal noninvasive carotid testing rarely improve following carotid reconstruction.³

3. Patients studied annually after carotid endarterectomy. Although recurrent carotid stenosis is unusual following carotid endarterectomy, such patients might be expected to have a higher prevalence of eventual contralateral carotid occlusive disease than a normal population.

4. Patients who have had carotid arteriograms that are difficult to inter-

pret. Even biplanar carotid arteriography occasionally demonstrates extracranial carotid lesions of marginal severity and questionable hemodynamic importance. Noninvasive carotid assessment may be used to clarify such a situation.

Complications from carotid compression have been reported⁴ but are usually caused by direct stimulation of the carotid sinus. In our experience, gentle compression low in the neck is safe. Compression of each proximal common carotid artery for a period of 4 to 8 seconds produced no temporary or permanent neurologic deficit in the 300 patients described in this report. One of us (R.H.S.L.) has personally performed more than 900 CCT tests during which only one patient had neurologic symptoms, and this patient recovered within a few days. Similarly, Bone et al¹⁰ have employed brief compression of the proximal common carotid arteries in more than 1000 complete periorbital Doppler cerebrovascular examinations with only one temporary neurologic deficit. Since carotid arteriography is associated with a neurologic complication rate of approximately 0.5% and might be expected to produce at least one neurologic deficit in every 200 patients who are studied, the extremely low incidence of neurologic deficits during CCT testing appears to be completely acceptable.

Summary

Correlation of CCT results and carotid arteriograms in 300 patients suggest that the accuracy of CCT is comparable to that of other methods of noninvasive carotid testing and that CCT is associated with an especially low incidence of false-negative results for lesions measuring greater than 75% stenosis on arteriography. Considering patients who have at least 50% carotid stenosis,

the overall accuracy of CCT is 80% with a false-positive rate of 19%, a false-negative rate of 22%, a sensitivity of 88%, and a selectivity of 69%. Among those with at least 75% carotid stenosis, the overall accuracy of CCT is 76% with a false-positive rate of 30%, a false-negative rate of 13%, a sensitivity of 91%, and a selectivity of 60%. Whereas no hemodynamic method of noninvasive carotid testing is appropriate for patients with hemispheric neurologic symptoms, CCT is a valuable adjunct in the management of patients with asymptomatic carotid bruits, nonhemispheric neurologic symptoms, previous carotid operations, or questionable arteriographic findings.

Acknowledgment

We thank Patricia Santilli, R.N. for assistance with data collection for this study.

References

1. Cohen DN, Wangelin R, Trotta C, et al: Carotid compression tonography; correlation with bilateral carotid arteriography in the diagnosis of extracranial carotid occlusive disease. *Stroke* **6**: 257-262, 1975.
2. Blackshear WM Jr, Thiele BL, Harley JD, et al: A prospective evaluation of oculoplethysmography and carotid phonoangiography. *Surg Gynecol Obstet* **148**: 201-205, 1979.
3. Kartchner MM, McRae LP, Crain V, et al: Oculoplethysmography; an adjunct to arteriography in the diagnosis of extracranial carotid occlusive disease. *Am J Surg* **132**: 728-732, 1976.
4. Gross WS, Verta MJ Jr, van Bellen B, et al: Comparison of noninvasive diagnostic techniques in carotid artery occlusive disease. *Surgery* **82**: 271-278, 1977.
5. Herrmann JB, Korgaonkar M, Cutler BS: Limitations of noninvasive evaluation of carotid occlusive disease. *Arch Surg* **114**: 1049-1051, 1979.
6. Machleder HI, Barker WF: Noninvasive methods for evaluation of extracranial cerebrovascular disease; a comparison. *Arch Surg* **112**: 944-946, 1977.
7. McDonald PT, Rich NM, Collins GJ, et al: Doppler cerebrovascular examination, oculoplethysmography, and ocular pneumoplethysmography; use in detection of carotid disease; a prospective clinical study. *Arch Surg* **113**: 1341-1349, 1978.
8. Towne JB, Salles-Cunha S, Bernhard VM: Periorbital ultrasound findings; hemodynamics in patients with cerebral vascular disease. *Arch Surg* **114**: 158-160, 1979.
9. Kartchner MM, McRae LP: Noninvasive evaluation and management of the "asymptomatic" carotid bruit. *Surgery* **82**: 840-879, 1977.
10. Bone GE, Slaymaker EE, Barnes RW: Noninvasive assessment of collateral blood flow of the cerebral hemisphere by Doppler ultrasound. *Surg Gynecol Obstet* **145**: 873-876, 1977.