

The diagnosis and management of chronic obstructive lung disease

Thomas A. Neff, M.D.*

One of the more commonly misdiagnosed diseases referred to our pulmonary specialty clinic is chronic obstructive pulmonary disease (COPD). COPD is often inaccurately overdiagnosed and used as a catchall category for patients with cough or dyspnea or both. Many times the patients do not have COPD, but more frequently have mild COPD and an additional cardiopulmonary disease that had not been diagnosed, but caused most of the more severe symptoms. To avoid such diagnostic pitfalls it is important to differentiate between the specific types of COPD and their respective mechanisms, namely emphysema, bronchitis, and asthma. A review of the typical and atypical symptoms, physical findings, and laboratory data of a patient with pure COPD and a brief review of current therapy will be discussed.

Diagnosis

COPD is one disease or any combination of three separate diseases: pulmonary emphysema, chronic bronchitis, and chronic asthma. Most patients tend to have a combination of these diseases rather than one pure form. For most patients cigarette smoking is the single most important causative factor of both emphysema and chronic bronchitis; it probably plays a minimal role in chronic asthma. Smoking is

* Chief, Pulmonary Service, Denver General Hospital; Associate Professor of Medicine, University of Colorado School of Medicine.

such an important factor that the validity of a diagnosis of emphysema or chronic bronchitis or both should be questioned when a patient has a history of little or no smoking. However, it is a mistake to think that everyone who smokes heavily has COPD. Of the roughly 50 million people currently smoking in the United States, 45 to 48 million have little or no apparent COPD. Smoking is a risk factor just as obesity is a risk factor for diseases such as diabetes or arteriosclerotic heart disease. The actual diagnosis of these diseases must be made specifically by the appropriate history and physical and laboratory examinations. Obstruction documented by simple spirometry is the critical objective laboratory test. The obstruction must not be totally or mostly reversible immediately after inhalation of a broncholytic drug or even subacutely reversible with therapy over a period of a few weeks or months. If the obstruction is reversed in a short time, the disease is not chronic by definition. Also many lung diseases such as tuberculosis, interstitial pulmonary fibrosis, bronchiectasis, and heart disease, e.g., mitral stenosis or left ventricular dysfunction or both, may have some obstruction and occasionally even a predominant pattern of obstruction on spirometry. These diseases should not be considered as COPD.

Young patients in their 20s and 30s will rarely have accumulated enough years of smoking exposure to have severe COPD. If these patients have presenting symptoms of severe dyspnea and much coughing and expectoration, one should consider cystic fibrosis and congenital and early acquired bronchiectasis. Such patients usually have clubbing, which essentially does not occur with COPD. Young patients who do not smoke may

also be hidden asthmatics with no wheezing and primarily with dyspneic or tussive symptoms.¹ A careful history for allergic and nonallergic inhaled environmental irritants should not be overlooked. If the young patient has a clinical picture of severe emphysema, especially with a family history of the same, alpha-one antitrypsin deficiency should be suspected. Finally, many primary interstitial lung processes will also have small airway involvement, (bronchitis or bronchiolitis or both). Symptoms from this aspect of the disease may lead the unwary physician away from the true diagnosis, such as desquamative interstitial pneumonia, a collagen vascular disease, and sarcoidosis. A checklist to help confirm or rule out the diagnosis of COPD is presented in *Table 1*.

After COPD has been diagnosed the physician should correlate quantitatively the various symptoms and laboratory data to see if they agree. A patient who complains of severe disabling dyspnea and has only mild obstruction on spirometric testing is likely to have another unidentified problem. This problem may be as simple and straightforward as malingering or cryptic left ventricular failure. *Table 2* outlines these clinical laboratory correlations. Two cases are reported.

Case reports

Case 1. A 57-year-old black woman was referred in 1976 to the pulmonary clinic for help in treating progressive, severe, disabling COPD. The patient had a history of smoking one-half pack of cigarettes a day for 20 years and none in the last 10 years, a minimal dry cough, but profound exertional dyspnea. Walking one-half block was the patient's maximum performance. Physical examination revealed moderately decreased breath sounds and signs of mild pulmonary hyper-

Table 1. COPD diagnostic checklist

	Typical	Comment	Atypical	Comment
Symptoms or history	Heavy smoking	Usual (see text)	Paroxysmal dyspnea	Usually means left heart disease; occasionally (a) accumulation of secretion in bronchitis, (b) bedroom allergy, (c) cryptic aspiration
	Productive cough	Caused by bronchitis	Orthopnea	Consider atypical coronary artery disease, primary pulmonary hypertension, or diseases that affect pleura or chest wall
	Dyspnea equal to obstruction	Non-specific symptom (Table 2)	Chest pain	Local laryngeal disease, consider laryngoscopy and/or flow-volume loop ²
Physical findings	Decreased breath sounds	Can be graded by auscultation ³	Chronic hoarseness or dysphonia	Large airway obstruction, i.e., carcinoma, foreign body
	Rhonchi and distal wheeze	Occur secondary to secretion and small airways dynamic collapse	Persistent wheeze	Does not occur in COPD; consider pulmonary fibrosis, bronchiectasis, cancer
	Occasional fine rales may be present	Prominent coarse rales mean pulmonary fibrosis or left ventricular failure	Clubbing	Pulmonary and tricuspid valve insufficiency murmurs rare and then only with severe cor pulmonale
			Heart murmur	
Laboratory findings	Obstructive spirometric pattern	May be present with other lung disease (see text)	Restrictive spirometric pattern	Usually means non-COPD rare exception ⁴
	Little to mild reversibility	Reference 5	Marked reversibility	Reference 6
Chest x-ray film	No infiltrate, hyperinflation, no adenopathy	May have increased markings; ⁷ adenopathy may be difficult to distinguish from enlarged hilar vessels	Infiltrates, decreased lung volume, hilar adenopathy	Usually means some form of intestinal lung disease. Consider granuloma or lymphoma with adenopathy

Table 1—Continued

	Typical	Comment	Atypical	Comment
Laboratory findings (continued) ECG	Normal or	With mild to moderate disease	Left atrial and/or ventricle enlargement	Means additional significant left heart disease; consider echocardiography, heart catheterization, and consultation
	Right atrial and ventricle enlargement	Only with moderately severe to severe disease		
CBC	WBC normal	Occasionally transiently elevated with infection	Eosinophilia	If present, consider atopic asthma, bronchopulmonary aspergillosis, collagen vascular disease, etc.
	RBC, hematocrit hemoglobin-normal	If elevated, means hypoxemia		
	Platelets normal	If elevated, consider primary blood dyscrasia		

tension; a chest roentgenogram revealed normal to diminished lung volumes, no discernible infiltrates, prominent pulmonary hilar shadows suggestive of pulmonary hypertension (*Fig. 1*). The patient's first spirogram (none had been done despite severe disease of 10 years) revealed a forced expiratory volume (FEV₁) of 1.26 L with a forced vital capacity (FVC) of 1.56 L giving a FEV₁ to

FVC ratio of 0.81. The overall clinical impression was restrictive lung disease rather than COPD. Mediastinoscopy revealed numerous small, but definitely enlarged lymph nodes, which contained noncaseating granuloma. Full-dose prednisone therapy was initiated with considerable clinical improvement. In 10 months the patient's FEV₁, and FVC had improved to 1.99 L and 2.42 L,

Table 2. Clinical/laboratory correlation in "pure" COPD

Parameter	Mild	Moderate	Severe	Very severe
Dyspnea	Only with maximum exercise	With fast walking	With average pace walking	With any exertion; one-half block slow walking maximum
FEV ₁ *	2.0 to 1.5 L	1.5 to 1.0 L	1.0 to 0.5 L	0.5 L
FEV ₁ /FVC	.6	.5	.4	<0.3
Hypoxemia	Absent	↓ 0 to 10 torr	↓ 10 to 20 torr	↓ 10 to 40 torr
Cor pulmonale	Absent	Absent to mild	Mild to moderate	Moderate to severe
Disability	Little or none	Heavy physical labor limited	Sedentary work and activities only	House, chair, bed bound

* Average size adult male; adjust slightly upward for large patient, downward for smaller, older or female patient.

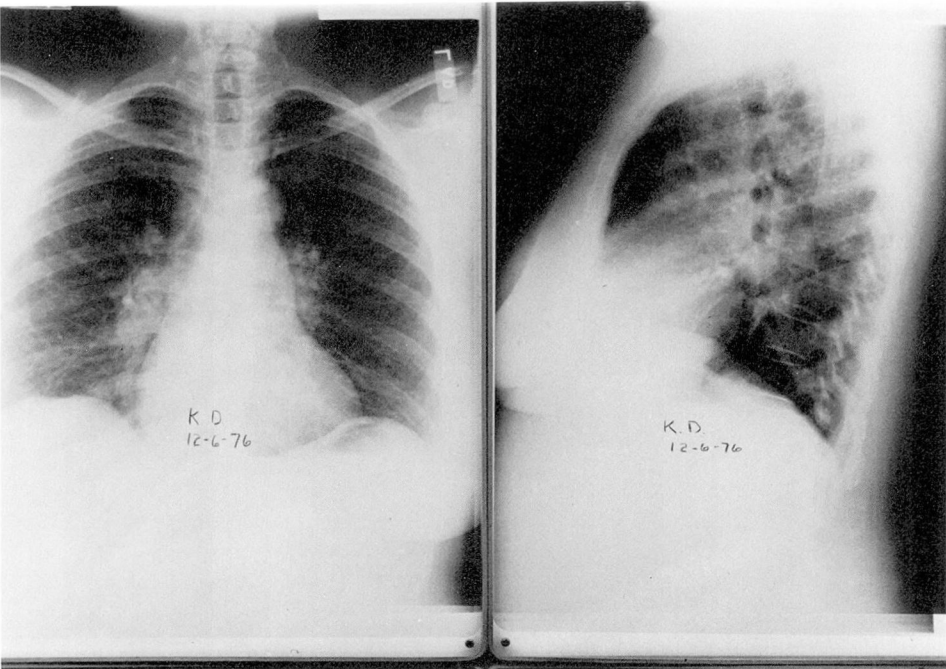


Fig. 1. Posteroanterior and lateral chest roentgenograms of patient with misdiagnosed COPD. Note normal to small lung volume, best appreciated on lateral view and prominent hilar shadows, which were both enlarged pulmonary arteries and noncaseating hilar lymphadenopathy, i.e., sarcoidosis.

respectively. This patient with "irreversible end-stage COPD" was no longer disabled.

Correctly interpreted simple spirometry and the small rather than large lung volumes on chest roentgenogram were the major clues to this severe, progressive, chronic, nonobstructive, partially reversible lung disease, i.e., sarcoidosis.

Case 2. A 52-year-old white man was followed up for severe COPD in the pulmonary clinic by various members of the staff. History, physical examination, chest roentgenogram (Figs. 2, and 3), and spirometry ($FEV_1 = 0.59$ L, $FVC = 1.26$ L; ratio = 0.47) were compatible and seemed to fit the diagnosis. However, a medical student timidly reported a diastolic heart murmur and possibly an opening snap. One week later cardiac catheterization confirmed tight mitral stenosis with a mean pulmonary artery wedge pressure of 25 torr at rest increasing to 55 torr with minimal exercise. Three months after mitral valve replacement there

was considerable improvement of exertional dyspnea, and spirometry improved to FEV_1 0.90 L and FVC to 2.22 L.

A patient can have two concomitant diseases, and there is no substitute for a careful medical history and physical examination.

Treatment

When planning a therapeutic regimen for patients with accurately diagnosed COPD, the possible reversibility of the disease should be considered in terms of acute and chronic, not in a temporal sense, but as the neurologist defines acute and chronic brain syndromes: acute means reversible or potentially reversible, and chronic means essentially irreversible. Many reversible diseases have biphasic temporal response. A rapid, small, reversible component of obstruction in COPD may represent true bronchospasm that is im-

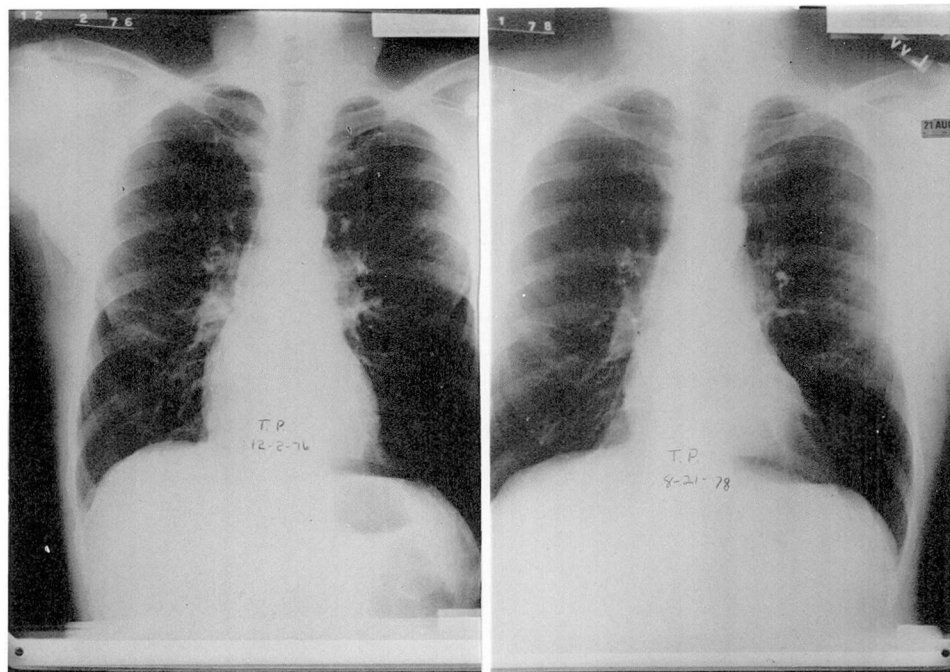


Fig. 2. Posteroanterior chest roentgenograms of patient with obvious, severe COPD and cryptic tight mitral stenosis. Hyperinflation and prominent central pulmonary arteries are two major findings before mitral valve surgery, December 2, 1976. After surgery, August 21, 1978, hyperinflation remains, but pulmonary arteries are less prominent.

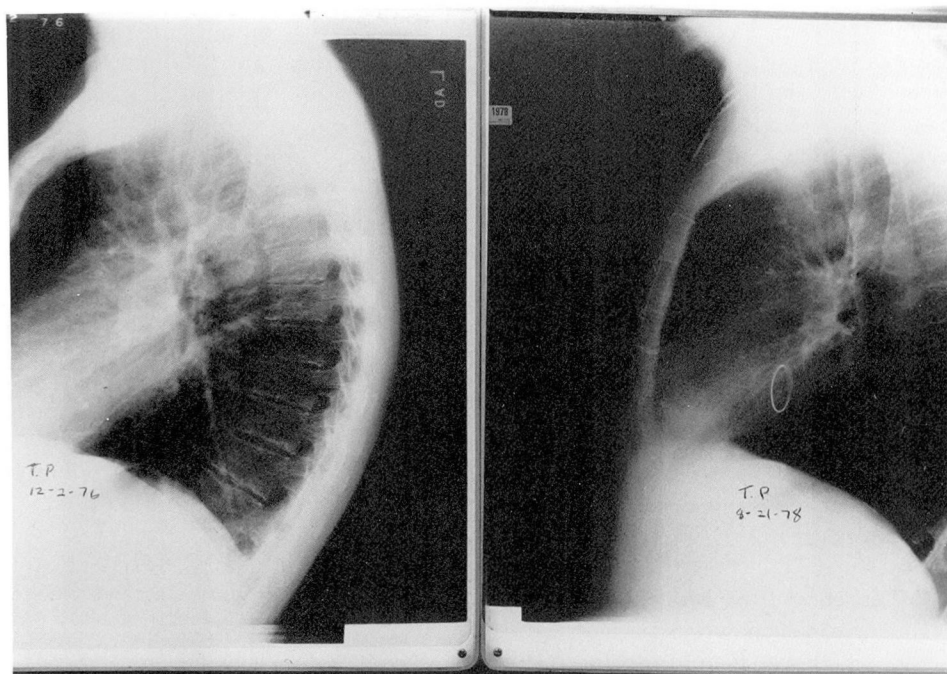


Fig. 3. Lateral chest roentgenograms, December 2, 1976, show enlargement of the cardiac silhouette posteriorly in area of left atrium and a large right pulmonary artery. X-ray film, August 21, 1978, shows opaque annulus of prosthetic mitral valve and marked decrease in size of left atrium and right pulmonary artery.

mediately improved by rapid-acting drugs such as inhaled beta agonists or intravenous aminophylline; a slower reversible component in COPD may be bronchial wall inflammation and mucous gland hyperplasia. Improvement occurs with the use of antibiotics and corticosteroid drugs, and abstinence from irritating cigarette smoke.

Acute bronchial obstruction and its reversibility can and should be evaluated routinely by spirometry immediately before and after inhaling a bronchodilator. The patient's true response can best be tested by withholding all acute-acting drugs such as inhaled and oral beta agonists and oral xanthines for 12 to 24 hours before testing if clinically feasible. (As a laboratory routine, the pulmonary function technician should always record all the bronchodilator

drugs, and the exact time the patient has taken them on the day the spirogram is made.) Slower reversibility of bronchoconstriction can only be shown accurately by a careful therapeutic trial with accurate baseline documentation before therapy and then follow-up testing in 1 to 3 months.⁶

Unfortunately, no medication reverses or prevents the deleterious effects of cigarette smoke. Therefore, if on the first clinic visit, the patient has a history of smoking heavily and still smokes heavily, I purposely do not prescribe any medication for emphysema or bronchitis. This is analogous to giving tolbutamide (Orinase) to a severely obese diabetic patient without diet instruction, urine tests, and other studies. If the patient who smokes is willing to admit or accept the fact that smoking is a

serious problem, I reinforce the importance of stopping smoking and offer him or her two pamphlets called "Why Do You Smoke?" and "Calling It Quits" available to physicians free from the Office of Cancer Communication, National Cancer Institute, National Institutes of Health, Bethesda, Maryland 20014. After discussing the smoking problem with the patient I believe it is important to devise a regimen.⁸

In general, for the past 10 years I have noted the following changes or reaffirmation in my management of patients with COPD.

1. Use of more nurse specialists and respiratory therapists for basic patient education.

2. Less compulsive bronchial hygiene regimens and then only in patients with active secretions. Rarely use intermittent positive pressure breathing for inpatients or outpatients. Often use longer-acting, metered-dose nebulizers with inhaled beta agonist, i.e., isoetharine mesylate (Bronkometer), metaproterenol sulfate (Alupent) for regular therapy. Rarely prescribe postural drainage, except for bronchiectasis and severe bronchitis with marked secretions.

3. Use of longer-acting theophylline oral drugs with 8- to 12-hour blood levels/dose, e.g., theophylline, anhydrous (Slo-Phyllin); theophylline, anhydrous (Theo-Dur).

4. More frequent use of prednisone but require spirometry before and one month after its initiation to document objective improvement.

5. Continued use of antibiotics liberally for clinical (without culture) exac-

erbation with tetracycline, ampicillin, trimethoprim and sulfamethoxazole (Bactrim), and chloramphenicol in that order.

6. Simple, progressive exercise taken regularly with walking and stair climbing as the major activities.

7. Prudent use of oxygen for medical and economic reasons, requiring patients to have hypoxemia documented, resting PaO_2 usually less than 50 torr and signs of tissue hypoxia, i.e., secondary erythrocytosis, pulmonary hypertension, and decompensated cor pulmonale (right-sided congestive heart failure).⁹

References

1. Corrao WM, Braman SS, Irwin RS: Chronic cough as the sole presenting manifestation of bronchial asthma. *N Engl J Med* **300**: 633-637, 1979.
2. Miller RD, Hyatt RE: Evaluation of obstructing lesions of the trachea and larynx by flow-volume loops. *Am Rev Respir Dis* **108**: 475-481, 1973.
3. Pardee NE, Martin CJ, Morgan EH: A test of practical value of estimating breath sound intensity; breath sounds related to measured ventilatory function. *Chest* **70**: 341-344, 1976.
4. Colp C, Williams MH Jr: Total occlusion of airways producing a restrictive pattern of ventilatory impairment. *Am Rev Respir Dis* **108**: 118-122, 1973.
5. Burrows B, Petty TL: Longterm effects of treatment in patients with chronic airway obstruction. *Chest* **60**: 25S-27S, 1971.
6. Petty TL, Brink GA, Miller MW, et al: Objective functional improvement in chronic airway obstruction. *Chest* **57**: 216-223, 1970.
7. Fraser RG, Paré JA: *Diagnosis of Diseases of the Chest*, V.3, ed 2. Philadelphia, WB Saunders, 1979, pp 1384-1385.
8. Farrington JF: Rehabilitation of the pulmonary cripple in private practice. *Chest* **60**: 18s-20s, 1971.
9. Neff TA: Selection of patients for oxygen therapy. *Chest* **68**: 481-482, 1975.