

Adenocarcinoma of the gastroesophageal junction presenting as achalasia

Mansour F. Maleki, M.D.*
Bertram Fleshler, M.D.
Edgar Achkar, M.D.

Department of Gastroenterology

Khalil Sheibani, M.D.

Division of Laboratory Medicine

Primary achalasia of the esophagus is a disease of unknown etiology characterized by failure of the lower esophageal sphincter to relax in response to swallowing and the absence of peristaltic activity in the body of the esophagus. Occasionally, carcinoma of the stomach and other tumors involving the gastroesophageal junctional area may have the presenting symptoms of achalasia.¹⁻⁶ It may be difficult to differentiate between primary and secondary achalasia, but it is important from the standpoint of selecting appropriate therapy. We report two cases of adenocarcinoma of the stomach presenting initially as achalasia.

Case 1. A 36-year-old black male was admitted with a 3- to 4-week history of intermittent dysphagia accompanied by vague substernal pain. The dysphagia was initiated by both solid foods and liquids. Cold liquids were particularly difficult to swallow. There was no history of nausea, vomiting, weight loss, or chest pain between meals. A laparotomy had been performed 12 years earlier for a gunshot wound of the abdomen, but there were no other unusual events in the history.

The physical examination was unremarkable. A barium meal showed dilatation of the entire esophagus with distal narrowing and delay of the passage of barium. The end of the esophagus was tapered and the mucosa appeared normal (*Fig. 1*). The roentgenographic diagnosis was achalasia. On endoscopic examination, the esophagus was dilated and no peristaltic movements were ob-

* Associate Professor of Medicine University of Isfahan, Iran. International Scholar, The Cleveland Clinic Foundation.

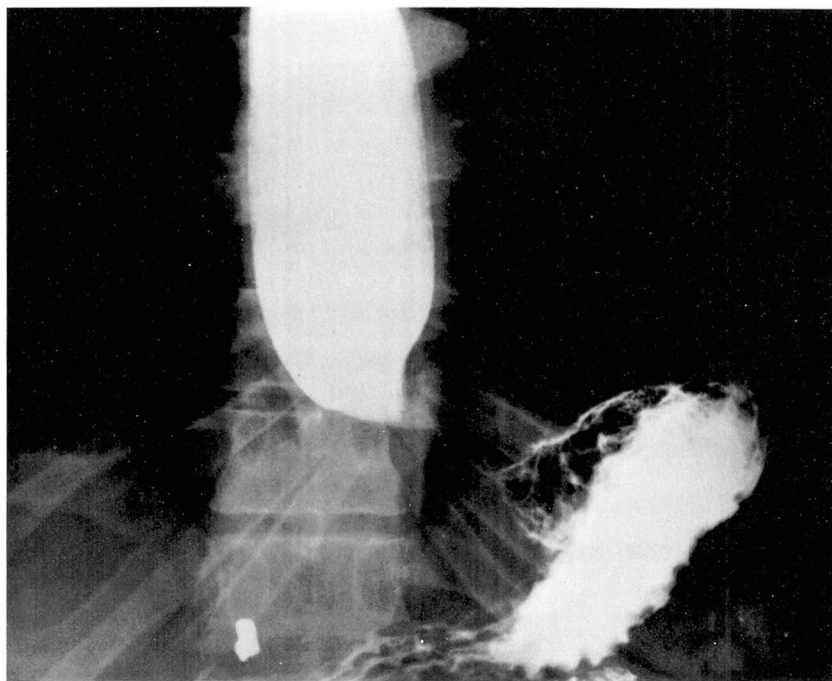


Fig. 1. Barium meal showing dilatation of the esophagus with a tapered narrowing at the esophagogastric junction (case 1). Roentgenographic diagnosis was achalasia.

served. The esophagogastric junction was tight, but the instrument could be passed through to the stomach with slight pressure. Retrograde views of the cardia revealed no abnormalities and the remainder of the stomach and duodenum was normal except for minimal hypertrophy of the gastric mucosa. The endoscopic diagnosis was achalasia and hypertrophic gastritis. Biopsy specimens obtained from sites at the esophagogastric junction that appeared normal showed signet cell adenocarcinoma. A gastroesophageal resection and pyloroplasty were performed. The resected segment of esophagus was estimated at 5 cm during operation, but on pathologic examination only 2 cm of esophagus was contained in the specimen and the proximal line of resection was involved with tumor.

Histopathologic examination revealed a poorly differentiated, highly invasive mucinous adenocarcinoma with transmural invasion of the gastroesophageal segment (*Fig. 2*). Ganglion cells of Meissner's plexus were

not found, because the neoplasm had massively invaded the submucosa. Ganglion cells within Auerbach's plexus were found with difficulty, and most of the few identifiable collections demonstrated invasion and destruction by malignant cells (*Fig. 3*). The patient survived 19 months after surgery. No autopsy was obtained.

Case 2. A 57-year-old black male had a history of an 18 kg (40 pound) weight loss in the previous 5 months, beginning shortly after the death of his wife. Initially there was no anorexia. One month before admission, the patient noted that food was sticking substernally, anorexia had developed, and regurgitation of food 30 to 60 minutes after a meal became increasingly frequent. These symptoms were accompanied by epigastric pain at night. There was no history of gastrointestinal symptoms. A barium meal showed a dilated esophagus with lengthening and tapering of the distal end (*Fig. 4*). The stomach was normal except for a deformity of the distal antrum and pylorus.

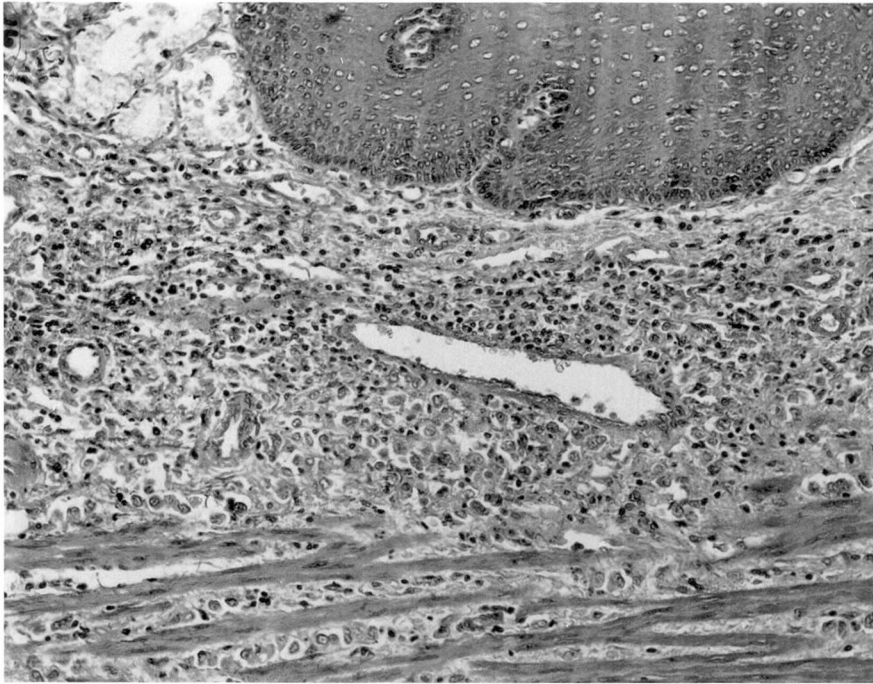

Fig. 2. Photomicrograph from the gastroesophageal junction demonstrating massive neoplastic infiltration (case 1) (hematoxylin and eosin stain, $\times 400$).

The roentgenographic diagnosis was achalasia with possible scarring from previous peptic ulcer disease. At endoscopy, the esophagus contained about 200 cc of thick, mucoid material. The esophagus was dilated and the instrument could not be passed into the stomach. The patient underwent dilatation with Maloney Bougies up to No. 48 French. Pneumatic dilation was attempted, but was unsuccessful. A week later a second attempt at pneumatic dilation was also unsuccessful and the patient was referred for surgery. Carcinoma of the upper half of the stomach involving the gastroesophageal junction was found. The tissue diagnosis was adenocarcinoma of the signet cell type. No resection was done. The patient did well for 4 months, but did not return for follow-up.

Discussion

Achalasia is a motor disorder of the esophagus caused by degeneration of the cells of Auerbach's plexus. In most cases, the cause is unknown. In certain

geographic areas, achalasia is produced by the action of the neurotoxin of *Trypanosoma cruzi*.⁷ No other agents have been identified that produce such degeneration.

Clinically and roentgenographically, achalasia has been described in association with carcinoma involving the cardioesophageal junction. In these cases, the question arises as to whether the cancer preceded and produced the achalasia or whether the cancer developed as a complication of achalasia. The latter phenomenon is recognized as a late and relatively unusual complication in long-standing achalasia.⁸⁻¹⁰ It is not possible to determine absolutely which disorder came first, but in the two cases described here, and other reported cases, the evidence supports the idea that carcinoma was the primary lesion. The factors favoring carcinoma as the primary

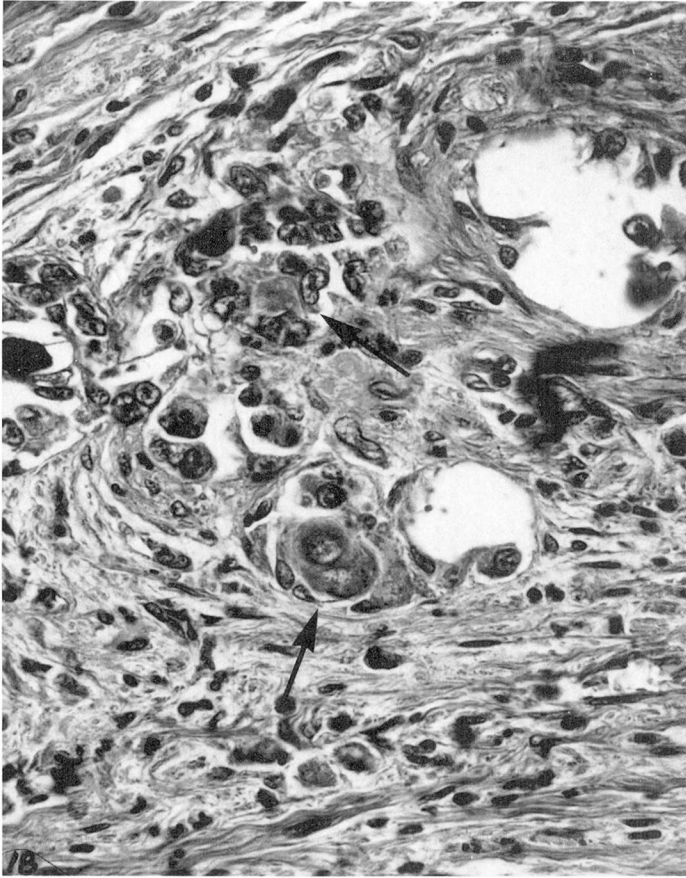


Fig. 3. Photomicrograph demonstrating partial destruction of a residual ganglion cell collection by invading malignant cells (arrows). Esophageal line of resection 12 mm proximal to the gastroesophageal junction (case 1) (periodic acid-Schiff stain, $\times 400$).

lesion were the short duration of symptoms (4 weeks and 5 months in our two cases, respectively) and the relatively rapid progression of disease once it was discovered. Idiopathic achalasia, by contrast, is a relatively indolent disorder, which results in little increase in mortality. Recent onset of symptoms, however, occurs in as many as 12% of patients with idiopathic achalasia.¹¹ Thus a short history, although suggestive, does not reliably differentiate achalasia apparently due to carcinoma from the idiopathic form.

It has been suggested that carcinoma

as a cause of achalasia should be considered, particularly in patients older than 50 years with a brief history and severe weight loss.¹ In our two patients the history was brief, but weight loss, at least in the first patient, was not severe, and the disease occurred at ages 36 and 57 respectively. Others have reported carcinoma with the picture of achalasia in patients in their 30s.^{1,6} Thus carcinoma as a cause must be considered in a patient with achalasia at any age.

Differentiation between idiopathic achalasia and achalasia secondary to carcinoma of the cardia may be diffi-

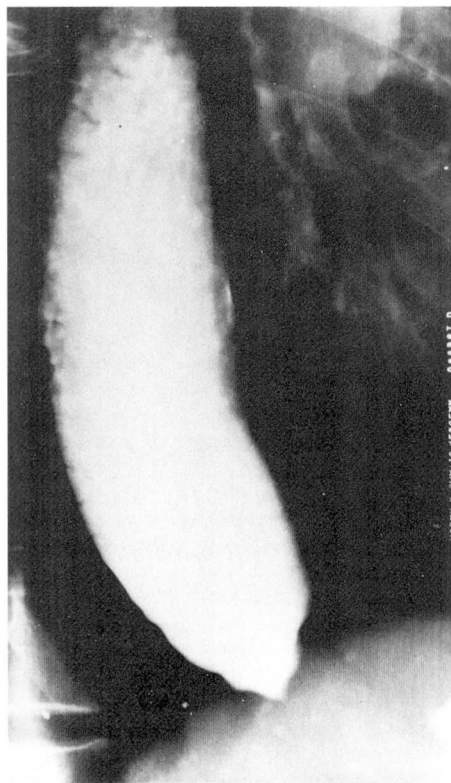


Fig. 4. Barium meal showing a dilated esophagus with lengthening and tapering at the distal end (case 2). Roentgenographic diagnosis was achalasia.

cult. Each of our patients had the typical roentgenographic features of achalasia although each had a neoplasm. Thus history, physical examination, and roentgenography may not establish the diagnosis. Endoscopy with biopsy remains the most helpful means of eliminating the diagnosis of carcinoma in a patient with apparent achalasia. However, in the two cases reported here, and in other reported cases,¹⁻³ endoscopy initially failed to establish the diagnosis of carcinoma. This may occur because the carcinomatous lesion is not seen, the upper stomach is not well visualized, or the carcinoma primarily is one that infiltrates the submucosa and, as in case

1, is difficult to observe. Biopsy is definitive when positive, but may not be helpful, since it is not unusual for an endoscopic biopsy to fail to identify neoplastic material and to simply sample tissue from surrounding areas of necrosis or inflammation.

The pathogenesis of the achalasia in adenocarcinoma of the cardia is not well defined. One possible mechanism producing the aperistalsis involves infiltration of esophageal myenteric and nerve plexuses with neoplastic cells. In the first case reported here all identifiable areas of Auerbach's plexus were infiltrated and destroyed up to and including the line of resection. Similar results and speculations have been reported by others.^{4, 12} Some have rejected the mechanism mainly on the basis of failure to demonstrate such invasion in certain cases.^{1, 3}

How much destruction of Auerbach's plexus is needed to produce achalasia is unknown. It has been estimated that as much as 90% destruction may be required.¹³ Since serial sections and careful counting of ganglion cells in cases of carcinoma with achalasia have not been done, it is not possible to be definitive about direct myenteric invasion and the pathophysiologic mechanism.

A second possible mechanism concerns the idea that achalasia may occur as a reaction to distal obstruction. Such a hypothesis is suggested by reversal of achalasia in a treated sarcoma¹⁴ and restoration of normal peristalsis following pneumatic dilatation in idiopathic achalasia.¹⁵ However, achalasia is rare in the many instances of distal obstruction due to cancer and stricture and true reversibility of idiopathic achalasia, with the exception cited, is unknown.

Finally, it has been suggested that achalasia in cancer represents a peripheral manifestation of cancer analogous

to the distant disorders of the central and peripheral nervous system associated with tumors.³ No direct evidence exists to support this hypothesis, and achalasia has not been reported in cancers that do not directly involve the area of the esophagus or stomach.

References

1. Tucker HJ, Snape WJ Jr, Cohen SC: Achalasia secondary to carcinoma; manometric and clinical features. *Ann Intern Med* **89**: 315-318, 1978.
2. McCallum RW: Esophageal achalasia secondary to gastric carcinoma. *Am J Gastroenterol* **71**: 24-29, 1979.
3. Shulze KS, Goresky CA, Jabbari M, et al: Esophageal achalasia associated with gastric carcinoma; lack of evidence for widespread plexus destruction. *Can Med Assoc J* **112**: 857-864, 1975.
4. Bessent CT, Lopez CA, Cocco AE: Case report; carcinoma of the EG junction mimicking achalasia. *Md State Med J* **22**: 47-50, 1973.
5. Herrera AF, Colon J, Valdes-Dapena A, et al: Achalasia or carcinoma? The significance of the Mecholyt test. *Am J Dig Dis* **15**: 1073-1081, 1970.
6. Ullal SR, Rao NR: Achalasia. An unusual manifestation of carcinoma of the cardia. *J Indian Med Assoc* **60**: 431-432, 1973.
7. Ferreira-Santos R: Aperistalsis of the esophagus and colon (megaesophagus and megacolon) etiologically related to Chagas' disease. *Am J Dig Dis* **6**: 700-726, 1961.
8. Ellis FG: The natural history of achalasia of the cardia. *Proc R Soc Med* **53**: 663-666, 1960.
9. Wychulis AR, Woolam GL, Andersen HA, et al: Achalasia and carcinoma of the esophagus. *JAMA* **215**: 1638-1641, 1971.
10. Just-Viera JO, Haight C: Achalasia and carcinoma of the esophagus. *Surg Gynecol Obstet* **128**: 1081-1095, 1969.
11. Lawrance K, Shoesmith JH: A review of the treatment of cardiospasm. *Thorax* **14**: 211-215, 1959.
12. Kolodny M, Schrader ZR, Rubin W, et al: Esophageal achalasia probably due to gastric carcinoma. *Ann Intern Med* **69**: 569-573, 1968.
13. Cassella RR, Brown AL Jr, Sayre GP, et al: Achalasia of the esophagus; pathologic and etiologic considerations. *Ann Surg* **160**: 474-486, 1964.
14. Davis JA, Kantrowitz PA, Chandler HL, et al: Reversible achalasia due to reticulum-cell sarcoma. *N Engl J Med* **293**: 130-132, 1975.
15. Mellow MH: Return of esophageal peristalsis in idiopathic achalasia. *Gastroenterology* **70**: 1148-1151, 1976.