

The effects of thiamine on abnormal brainstem auditory evoked potentials

Derrick Lonsdale, M.D.

Department of Pediatrics and Adolescent Medicine

Richard H. Nodar, Ph.D.

Department of Otolaryngology and Communicative Disorders

James P. Orlowski, M.D.

*Division of Anesthesiology
Department of Pediatrics and Adolescent Medicine
Pediatrics and Surgical Intensive Care*

The measurement of brainstem auditory evoked potentials (BAEP) has added further sophistication to the study and localization of lesions within the auditory nervous system and the brainstem.

The technique of BAEP testing has been applied successfully in the assessment of the auditory nervous system extending from the eighth nerve to levels just above the midbrain. It has been used for ascertaining hearing thresholds in infants¹ and for determining the site of lesions at the level of the eighth nerve and brainstem.² The response is characterized by seven distinct peaks, each of which is thought to represent a level along the auditory pathway.³ Peak I is considered to be generated by the eighth nerve and Peak II by the cochlear nucleus, both on the ipsilateral side of the test ear. Peaks III through VII are believed to represent levels contralateral to the stimulated ear. Peak III represents the superior olivary complex; Peak IV, the nucleus of the lateral lemniscus; Peak V, the inferior colliculus; Peak VI, the medial geniculates; and Peak VII, the cortical radiations. Some investigators have interpreted the responses more broadly, relating Peak I to the eighth nerve, Peak III to the level of the pons, and Peak V to the midbrain. Results of such tests have been shown to be remarkably reproducible, with the exception of a group of patients with multiple

sclerosis.⁴ We have used seven criteria for evaluating BAEP test results.⁵

Two infants with recurrent episodes of life-threatening apnea had abnormal BAEP test results. One of them received an intravenous injection of thiamine tetrahydrofurfuryl disulfide (TTFD) and BAEP test results improved greatly within 15 minutes. No further treatment was given and 5 days later the test results were again grossly abnormal. The infant was then given TTFD by mouth and sequential BAEP testing revealed slow steady improvement. The second infant had similarly abnormal BAEP test results and was treated with water-soluble thiamine hydrochloride. The BAEP returned to normal within one month.

Materials and methods

Laboratory studies. Urinary amino acid chromatography was performed by the method of Efron.⁶ Red cell transketolase activity (TKA) was performed by the method of Massod et al.⁷ In this method the amount of sedoheptulose-7-phosphate produced per unit of time is measured. Then the enzyme cofactor, thiamine pyrophosphate (TPP) is added to the test mixture and the rate of sedoheptulose-7-phosphate produced per unit of time is measured again. If there is an acceleration of TKA, it has been shown that this is proportionate to the degree of cofactor deficiency and is reported as TPP% or TPP effect (TPPE). Severe deficiency will cause a fall in TKA and an increase in TPPE, whereas mild deficiency will cause only an increase in TPPE.⁷⁻⁹ Lonsdale and Shamberger¹⁰ reported results of TKA and TPPE in healthy subjects that were consistent with the results published by Massod et al.⁷ The subacute necrotizing encephalomyelopathy (SNE) inhibitor was kindly measured by Dr. J. R.

Cooper, Yale University School of Medicine. The methods used for measuring, recording, and interpreting the BAEP test results are reported.⁵

Case reports

Case 1. A 7-month-old white female infant was admitted to the Cleveland Clinic Hospital as an emergency because of repeated life-threatening apnea. During pregnancy the mother had a craving for candy, gained 23 kg, and had severe headaches and dental decay. At the age of 2 weeks the infant became acutely irritable and had an episode of opisthotonic posturing and deviation of the head and eyes to the left, which lasted for several hours. She began to choke repeatedly. Computed tomography (CT) of the head and an electroencephalogram (EEG) were reported to be normal. Anticonvulsants had no effect, and at the age of 4 months she had hypotonic musculature and several episodes of choking were followed by at least one respiratory arrest. Repeated apnea, restlessness, and sweating occurred during sleep, and there was chronic nasal congestion and constipation. Examination revealed severe muscular hypotonia, no balance when sitting, and truncal titubation when supported in the sitting position. CT of the head and EEG were again normal. The results of routine laboratory tests were essentially normal. Urinary amino acid chromatography was normal except for accentuation of beta amino isobutyric acid. Red cell TKA was 112.7 mU/L/min (normal, 42.1 to 86.1 mU/L/min), and TPPE was 0% (normal, 0% to 17.4%). Urine was positive for SNE inhibitor substance. The increased TKA and normal TPPE indicate that there was no TPP deficiency in this case.

Case 2. A 3-month-old black female infant had diarrhea, vomiting, nasal congestion, cough, and three episodes of apnea at the age of 8 weeks. She was admitted to Cleveland Clinic Hospital for study. The history revealed that during pregnancy the mother admitted to excessive ingestion of carbohydrates. Continuous electronic monitoring of the infant revealed one brief episode of bradycardia, but no apnea. The nor-

mal red cell TKA (68.5 mU/L/min) and the elevated TPPE value (40.2%) are pathognomonic for thiamine deficiency. There was moderate increase in serum glutamic oxaloacetic transaminase (SGOT) and lactic dehydrogenase (LDH) and increases in urinary glycine and alanine. She was discharged from the hospital and electronic monitoring was continued without any treatment. At the age of 11 weeks she had three more episodes of apnea, which caused the mother to call a rescue squad and the infant was readmitted to the hospital. CT of the head and the EEG were normal. No apneic episodes were observed during a period of monitoring. The repeat TKA was 83.5 mU/L/min and TPPE, 22.3%.

Results

A normal BAEP test result for a 4-week-old infant is shown in *Figure 1*. BAEP results in case 1 revealed gross abnormalities in wave shape, amplitude, latency and response stability (*Fig. 2A*). It was repeated 2 days later and was also abnormal. After obtaining parental informed consent, the infant was then given 25 mg TTFD by intravenous injection. The BAEP test response showed great improvement within 15 minutes (*Fig. 2B*). No further treatment was given for 5 days and the BAEP test was repeated; it was grossly abnormal

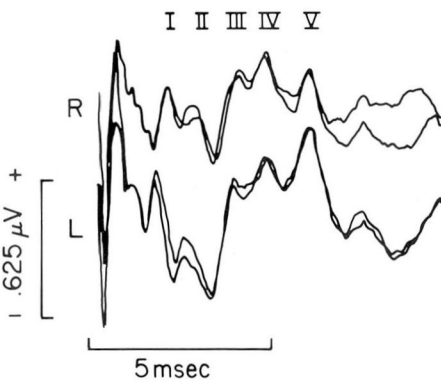


Fig. 1. Brainstem auditory evoked potential test results on a 4-week-old infant.

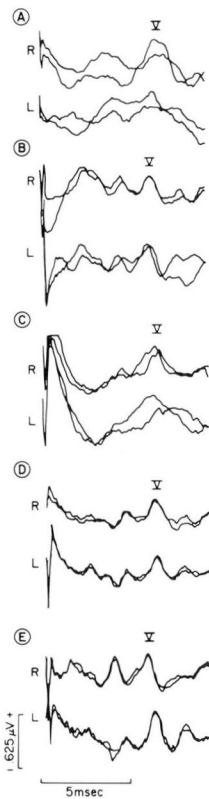


Fig. 2. BAEP results from a 7-month-old infant (case 1) showing an abnormal pattern (A); results on the same child 15 minutes after intravenous TTFD (B), after 5 days with no treatment (C); and after 3 days (D) and 2 weeks (E) with oral administration of TTFD.

(*Fig. 2C*). Parental informed consent for continued therapy with TTFD was obtained and this was given orally in a daily divided dose of 100 mg. BAEP testing was continued daily for the next 3 days and on the third day the results were nearly normal (*Fig. 2D*). The result of the test after 2 weeks of continued therapy is shown in *Figure 2E*. The improvement in wave shape, amplitude, response stability, and latencies was striking.

The initial BAEP test result in case 2 was grossly abnormal, particularly in response stability and wave shape, as in

case 1 (Fig. 3A). Thiamine hydrochloride in a daily divided dose of 150 mg was given orally and the test repeated in 2 weeks (Fig. 3B), and after one month of such therapy (Fig. 3C). A comparison between Figures 1 and 3C shows that the latter is essentially normal.

Discussion

This investigation was undertaken because of the links that have been reported between thiamine metabolism and brainstem function. Platt¹¹ noted that sudden death frequently occurred

in beriberi and suspected that there was a central effect in the brain rather than acute heart failure as was generally thought to be the cause of death at that time. Peters,¹² in his classic studies with B₁ avitaminotic pigeons, noted that the effect of thiamine was more noticeable in the lower brain. Of equal importance was the fact that he saw no difference in cellular respiration in the avitaminotic brain brei, as compared with controls, until glucose was added. The severe deficiency of respiration in the deficient brain tissue then became clearly manifest. Fehily¹³ noted a sudden death syndrome in breast fed infants of B₁ avitaminotic Chinese mothers, and Lonsdale¹⁴ in a review of thiamine metabolism, noted the parallel between this syndrome and the sudden infant death syndrome (SIDS). Fehily also pointed out the association with caloric intake, noting that the syndrome disappeared when the intake of avitaminotic rice was rationed to the Chinese nursing mothers. In our two cases there was a history of excessive carbohydrate ingestion during pregnancy. It is not known whether this had any bearing on the symptoms that were observed in these two patients since they were not breast fed. It is to be noted again, however, that case 2 showed laboratory evidence of TPP deficiency and the improvement in her BAEP test response after thiamine supplementation supports this.

Leigh's disease (SNE)¹⁵ has been shown in some cases to be associated with brain deficiency of thiamine triphosphate (TTP)¹⁶ and may give rise to a form of primary hypoventilation syndrome (Ondine's curse).¹⁷ One of the causes for TTP deficiency has been reported to be related to the appearance of a substance in urine that interferes with synthesis of TTP in brain.¹⁶ In case

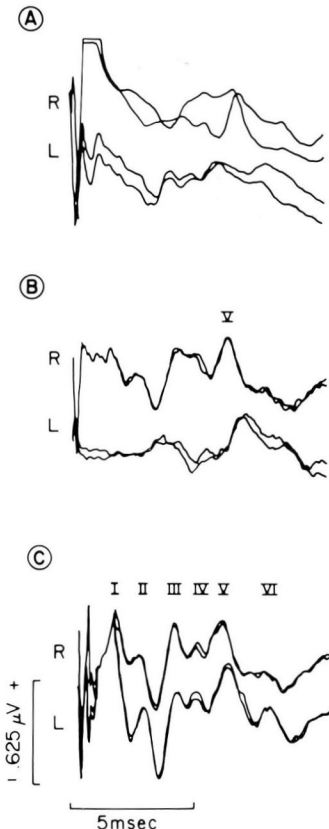


Fig. 3. BAEP test results from an 11-week-old infant (case 2) before treatment (A), 2 weeks (B), and 4 weeks (C) after initiating oral administration of thiamine hydrochloride. Compare BAEP result C with Figure 1.

1, the TKA was above the normal range, and the TPPE was normal, suggesting that there was no deficiency of TPP in this infant. The SNE inhibitory substance was present in the urine. It is possible, therefore, that the response in BAEP to TTFD therapy was due to its effect on TPP metabolism since this form of the vitamin is known to play a part in neuronal membranes, which is distinct and separate from that of TPP as a cofactor.¹⁸ Fat soluble thiamine derivatives are an important group of compounds, which have been studied comprehensively in Japan and used in the United States for treatment of SNE¹⁹. The newest of the synthetic compounds is TTFD. It is rapidly absorbed across cell membranes²⁰ and TTFD pretreated mice have been reported to be partly protected from the lethal effect of cyanide,²¹ suggesting that it has some effect in promoting cellular respiratory function.

The repeated improvement in the BAEP test results following the use of thiamine in these two infants was impressive. To our knowledge, there are no reports of similar improvement following administration of any medication. These findings are particularly striking since stability of response is characteristic of the test. The results reported in this study suggest that BAEP testing may have an important role in detecting brainstem abnormalities in infants and children who are critically ill. Abnormal BAEP results were found in eight other infants and are reported.⁵

Acknowledgment

TTFD was generously provided by Takeda Chemical Industries, Limited, Osaka, Japan, and used under FDA independent investigator license 11019.

References

1. Hecox K, Galambos R: Brain stem auditory evoked responses in human infants and adults. *Arch Otolaryngol* **99**: 30-33, 1974.
2. Starr A, Achor J: Auditory brain stem responses in neurological disease. *Arch Neurol* **32**: 761-768, 1975.
3. Stockard JJ, Stockard JE, Sharbrough FW: Detection and localization of occult lesions with brainstem auditory responses. *Mayo Clin Proc* **52**: 761-769, 1977.
4. Nodar RH: The effects of multiple sclerosis in brain stem and auditory evoked potentials. *Proceedings of First International Congress Symposium on Evoked Potentials*. M. T. P. Press Limited, Nottingham (in press), 1979.
5. Orlowski JP, Nodar RH, Lonsdale D: Abnormal brainstem auditory evoked potentials in infants with threatened sudden infant death syndrome. *Cleve Clin Q* **46**: 77-81, 1979.
6. Efron ML: Two-way separation of amino acids and other ninhydrin-reacting substances by high-voltage electrophoresis followed by paper chromatography. *Biochem J* **72**: 691-694, 1959.
7. Massod MF, McGuire SL, Werner KR: Analysis of blood transketolase activity. *Am J Clin Pathol* **55**: 465-470, 1971.
8. Dreyfus PM: Clinical application of blood transketolase determinations. *N Engl J Med* **267**: 596-598, 1962.
9. Brin M, Tai M, Ostashever AS, et al: The effect of thiamine deficiency on the activity of erythrocyte hemolysate transketolase. *J Nutr* **71**: 273-281, 1960.
10. Lonsdale D, Shamberger RJ: The potential value of red cell transketolase in the metabolic evaluation of disease. *Cleve Clin Q* **45**: 267-274, 1978.
11. Platt BS: Thiamine deficiency in human beriberi and in Wernicke's encephalopathy, in *Thiamine Deficiency; Biochemical Lesions and Their Clinical Significance*. Wolstenholme GEW, O'Connor M, eds. London, Little, Brown, and Company, 1967, pp 135-143.
12. Peters RA: The biochemical lesion in vitamin B₁ deficiency. *Lancet* **i**: 1161-1165, 1936.
13. Fehily L: Human milk intoxication due to B₁ avitaminosis. *Br Med J* **2**: 590-592, 1944.
14. Lonsdale D: Thiamine metabolism in disease. *Crit Rev Clin Lab Sci* **5**: 289-313, 1975.
15. Leigh D: Subacute necrotizing encephalomyelopathy in an infant. *J Neurol Neurosurg Psychiatr* **14**: 216-221, 1951.

16. Cooper JR, Itokawa Y, Pincus JH: Thiamine triphosphate deficiency in subacute necrotizing encephalomyelopathy. *Science* **164**: 74-75, 1969.
17. Cooper JR, Pincus JH: Role of thiamine triphosphate in subacute necrotizing encephalomyelopathy. *J Agric Food Chem* **20**: 490-493, 1972.
18. Muralt A von: Part III. Physiology and clinical use of thiamine. The role of thiamine in neurophysiology. *Ann NY Acad Sci* **98**: 499-507, 1962.
19. Pincus JH, Cooper JR, Murphy JV, et al: Thiamine derivatives in subacute necrotizing encephalomyelopathy. *Pediatrics* **51**: 716-721, 1973.
20. Thomson AD, Frank O, Baker H, et al: Thiamine propyl disulfide; absorption and utilization. *Ann Intern Med* **74**: 529-534, 1971.
21. Fujiwara M: Absorption, excretion and fate of thiamine and its derivatives in human body, *in* Review of Japanese Literature on Beriberi and Thiamine Deficiency. Shimazono N, Katsura E, eds. Tokyo, Igaku Shoin Limited, 1965, pp 179-213.