

Tuberous sclerosis presenting as a mass lesion in infancy

Janet W. Bay, M.D.

Department of Neurological Surgery

A. David Rothner, M.D.

Department of Neurology

Department of Pediatrics and Adolescent Medicine

Edward S. Sadar, M.D.

Department of Neurological Surgery

Tuberous sclerosis is a heredofamilial disorder characterized by a clinical triad of adenoma sebaceum, seizures, and mental retardation. In addition to the central nervous system, involvement of virtually every organ of the body by a variety of “tumors” has been described. Though initially described by von Recklinghausen¹ in 1862, the disease was more fully characterized and named by Bourneville^{2,3} in a series of papers between 1880 and 1900. He discussed several cases of mental deficiency associated with “potato-like” nodules in the brain.

This case of tuberous sclerosis is reported because of the unusual clinical course which included the presence of a tuber acting as a mass lesion during infancy; the usual cutaneous stigmata of tuberous sclerosis were absent.

Case report

A 6-month-old infant was admitted to the Cleveland Clinic Hospital for evaluation of seizures. The pregnancy and delivery had been uncomplicated. Birth weight was 3 kg (6 pounds 9 ounces) with an initial Apgar score of 7. A grand mal seizure occurred when the patient was 4 days old. The seizures continued despite treatment with phenobarbital, and she was admitted to another hospital for evaluation when she was 2 weeks old. Skull roentgenograms, electroencephalogram, and pneumoencephalo-

gram failed to disclose a cause for the seizures. By the age of 6 months she was having about 25 brief seizures a day, despite treatment with primidone, phenytoin, and pyridoxine.

The family history was positive for seizures in a maternal cousin. Both parents and an older sibling were normal, and lacked any cutaneous abnormalities.

Physical examination at the time of admission revealed a somewhat lethargic infant. Her head circumference was 47 cm (third percentile). The fontanel was soft and the skin showed no lesions. Cranial nerves including fundi were normal. Increased tone on the right was noted. Development was considered to be at the 3- to 4-month level.

Chest and skull roentgenograms were normal. Metabolic testing was nondiagnostic. Seizures continued despite the addition of ACTH given intramuscularly.

Computed axial tomography (CAT) of the head showed a calcified mass involving the medial left frontal lobe (*Fig. 1*). The EEG showed left frontal high voltage, slow activity, and epileptiform discharges. Cerebral angiography confirmed the presence of an avascular left frontal lobe mass with shift of the left anterior cerebral artery to the right.

A left frontal craniotomy was performed. The surface of the brain appeared normal, but a firm mass was palpable within the brain substance. This mass was found to arise on the medial surface of the hemisphere. Diagnosis on frozen section was "tuber", and the total mass was excised. The child did quite well postoperatively, and the final pathology report confirmed the diagnosis of tuberous sclerosis (*Fig. 2*).

A complete eye examination and intravenous pyelogram done postoperatively were within normal limits as were complete examinations of both parents and siblings.

The patient is now 3 years old and seizure control has improved with the ketogenic diet. She also requires anticonvulsants. Development has been severely delayed. Her head circumference is 44 cm (less than the second percentile), and the right hemiparesis persists. Reexamination of the skin at age 3

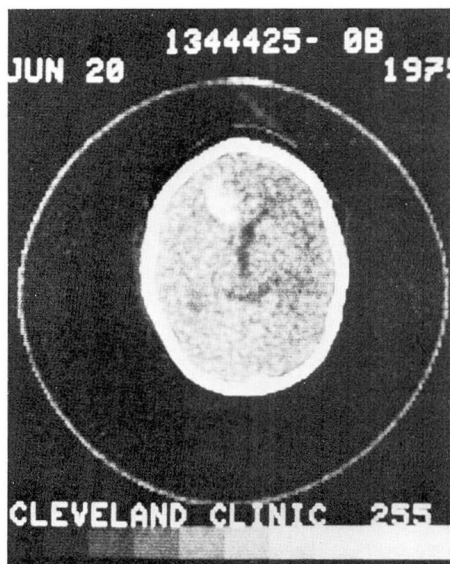


Fig. 1. CAT scan of head showing calcified mass involving medial left frontal lobe.

years shows one small depigmented area on the right arm.

Pathology

Grossly, the specimen was firm and whitish yellow. Microscopically, disordered cortical lamination was seen. The predominant cells were greatly swollen, bizarre astrocytes, some of which were multinucleated (*Fig. 2*). Other prominent abnormalities included groups of very large cells suggestive of neurons by their pyramidal shape and small areas of calcification particularly along the cortical surface. The underlying white matter showed severe gliosis.

Discussion

Tuberous sclerosis is rare. The exact incidence is difficult to determine, but estimates vary between 1 in 20,000 and 1 in 150,000 persons.^{4, 5} Manifestations of the disease also vary and many incomplete forms exist. The disease occurs worldwide in all races and there is an almost equal sex distribution.

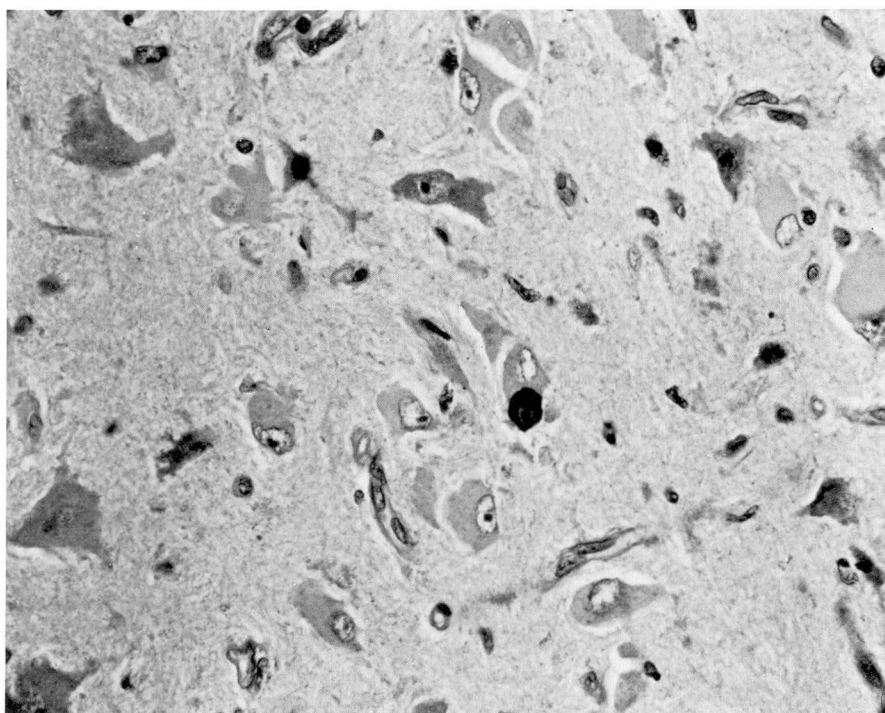


Fig. 2. Photomicrograph of frozen section from medial surface of left hemisphere of brain confirming diagnosis of tuberous sclerosis ($\times 400$).

The heredofamilial nature of the disease was first appreciated by Berg⁶ in 1913. It is inherited as an autosomal dominant condition with variable penetrance.⁷ Sporadic cases appear to be in the majority.⁸

The term tuberous sclerosis applies to only one feature of a varied disorder. The more common findings are summarized in the accompanying graph (Fig. 3). Rhabdomyomata of the heart, pulmonary cysts, and hamartomas of bone, thyroid, liver, adrenals, duodenum, and ovary have been described less frequently.^{9, 10}

The most frequently presenting symptoms of the disorder are seizures in early childhood. The seizures usually begin between 2 months and 2 years of age, although they may appear in the newborn. They may be of any type, but

between 6 months and 18 months infantile spasms predominate. They are extremely difficult to control. Mental deficiency becomes apparent quite early. This varies in severity, but is present in some degree in 60% to 70% of patients.⁵

The rash of adenoma sebaceum, if present, is pathognomonic and acne-form involving the butterfly area of nose and midcheeks. This finding is rarely present at birth and may not appear until puberty. Other cutaneous manifestations include depigmented areas, shagreen patches, periungual fibromas and cafe-au-lait spots. The depigmented areas are frequently present at birth and are best visualized with a Wood's light.

The lesions in the optic fundi in the tuberous sclerosis complex have been classified as phakomas.¹⁰ These small whitish nodules of disordered glial tissue

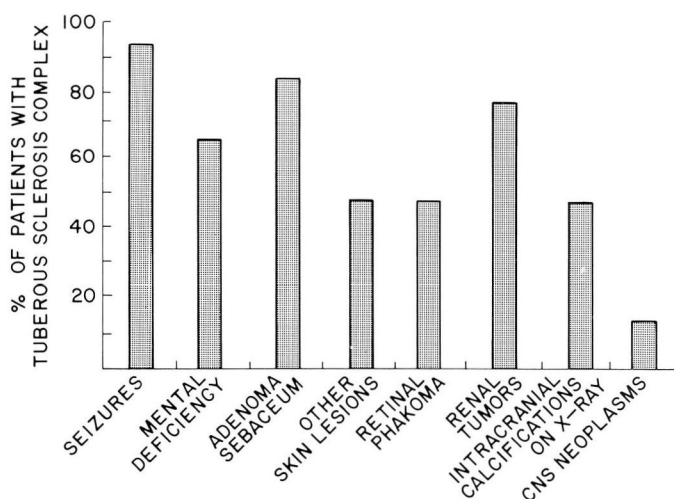


Fig. 3. Occurrence of common symptoms of tuberous sclerosis.

are usually multiple, but a single large lesion near the optic nerve head may dominate the picture. The lesions do not usually interfere with vision and have not been found to undergo malignant degeneration.

The characteristic neuropathologic feature is a cortical tuber. These sclerotic patches involving the gyri are more easily felt than seen in the unfixed brain. The frequently multiple tubers occur anywhere in the cortex, but have a predilection for the frontal areas.⁴ Histologically, our case is typical, but it is unique for a tuber to exert mass effect. We do not believe that such a case has been reported in the English literature. Growth of the tuber usually parallels that of the remainder of the cortex, and compression of surrounding tissue is slight.⁴

Other pathologic manifestations in the brain include clusters of heterotopic cells in white matter, and subependymal glial nodules frequently situated around the foramen of Monro. These nodules are often calcified and are responsible for the characteristic roentgenogram

and CAT scan. The nodules may undergo malignant degeneration to become subependymal giant cell astrocytomas. Although the occurrence of brain tumors in tuberous sclerosis is said to be rare, according to two published reports, tumors have been found about the anterior ventricular system in 10% to 15% of cases.^{11, 12} In contrast intracortical tubers do not appear to undergo neoplastic change.¹³

The evaluation of the patient suspected of having tuberous sclerosis should include careful examination of the skin, dilated fundus examination, EEG, CAT scan, intravenous pyelogram, and ECG. A careful examination of the parents, possibly including CAT scans to detect asymptomatic calcifications, should be carried out.

The course of this disease is somewhat unpredictable. The prognosis is generally poor. Early total evaluation of any patient with tuberous sclerosis and his or her family is mandatory for early recognition and therapy of associated problems, so that accurate genetic counseling may be provided. If no manifes-

tations are found in the parents, this may represent a spontaneous gene mutation.

Summary

An unusual case of tuberous sclerosis in infancy with a cortical tuber acting as a mass lesion and without skin lesions is presented. The various manifestations of the tuberous sclerosis complex are discussed.

References

1. von Recklinghausen F: Ein Herz von einem Neugeborenen, welches mehrene, theils nach aussen, theils nach den Hohlen prominirende Tumoren (Myomen) trug. *Monatschrift Geburtshilfe Gynakol* **20**: 1-2, 1862.
2. Bourneville DM: Contribution à l'étude de l'idiotie. Sclérose tubéreuse des circonvolutions cérébrales; idiotie et épilepsie hémiplegique. *Arch Neurol (Paris)* **1**: 81-91, 1880-1881.
3. Bourneville DM: Idiotie et épilepsie symptomatiques de sclérose tubéreuse ou hypertrophique. *Arch Neurol (Paris)* **10**: 29-39, 1900.
4. Donegani G, Grattarola F-R, Wildi E: Tuberous sclerosis; Bourneville disease, Ch. 11, in *Handbook of Clinical Neurology*, v. 14,

Phakomatoses. Vinken PJ, Bruyn GW, eds. Amsterdam, North Holland Publishing Co, 1972.

5. Lagos JC, Gomez MR: Tuberous sclerosis; reappraisal of a clinical entity. *Mayo Clin Proc* **42**: 26-49, 1967.
6. Berg H: Vererbung der tuberöse Sklerose durch zwei bzw. drei Generationen. *Z Neurol Psych* **19**: 528, 1913.
7. Paulson G: Changing concepts of tuberous sclerosis. *Dev Med Child Neurol* **9**: 493-494, 1967.
8. Medley BE, McLeod RA, Houser OW: Tuberous sclerosis. *Sem Roentgenol* **11**: 35-54, 1976.
9. Moolten SE: Hamartial nature of the tuberous sclerosis complex and its bearing on the tumor problem; report of a case with tumor anomaly of the kidney and adenoma sebaceum. *Arch Intern Med* **69**: 589-623, 1942.
10. Blackwood W, Corsellis JA: *Greenfield's Neuropathology*. London, Edward Arnold Publishers Limited, 1976, pp 410-417.
11. Kapp JP, Paulson GW, Odom GL: Brain tumors with tuberous sclerosis. *J Neurosurg* **26**: 191-202, 1967.
12. Fitz CR, Harwood-Nash DCF, Thompson JR: Neuroradiology of tuberous sclerosis in children. *Radiology* **110**: 635-642, 1974.
13. Rubinstein LJ: Tumors of the central nervous system. Washington, DC, Armed Forces Institute of Pathology, Fasc **6**: 40-42, 1972.