

Progressive myxomatous degeneration of the cardiac valves

Santos A. Uy, Jr., M.D.

Department of Cardiology

Paul C. Taylor, M.D.

*Department of Thoracic and
Cardiovascular Surgery*

John R. Kramer, M.D.

Department of Cardiology

Pure valvular insufficiency with no history of rheumatic fever may be caused by myxomatous degeneration. The involved valve has a characteristic gross and histologic appearance. The “floppy valve syndrome” as described by Read et al¹ has been observed in stillborn infants, those with ventricular septal defect with prolapse of aortic cusps,² fibroelastosis, Hurler’s syndrome,³ Ehler-Danlos syndrome,⁴ atrial septal defect,⁵ and Marfan’s syndrome and its formes frustes.⁶ This pathologic change has also been described in the mitral valve prolapse-click syndrome,⁷ which occurs in approximately 6.3% of the healthy female population.⁸ This entity is probably a milder expression of the myxomatous process, since few of these patients require valve replacement.^{9, 10}

We report a case of myxomatous degeneration involving the mitral and aortic valves that resulted in mitral valve replacement followed by aortic valve replacement within 15 months.

Case report

A 63-year-old welder was in good health until he was hospitalized with acute pulmonary edema in August 1976. During hospitalization he responded to appropriate therapy, but continued to experience dyspnea on exertion and orthopnea after discharge despite adequate Digoxin and diuretic therapy. He was referred to the Cleveland Clinic for further evaluation.

On physical examination, he weighed 75.2 kg (167 pounds) and was 172.5 cm (5 feet 9 inches) tall. The blood pressure was 140/80 mm Hg and the pulse rate was 75 beats per minute. The lungs revealed fine crackling rales at the bases. The point of maximum impulse was at the sixth left intercostal space 2 cm left of the midclavicular line. A left ventricular heave and systolic thrill were present. There was a Grade IV/VI harsh holosystolic murmur at the apex radiating to the axilla. There was no diastolic murmur.

The complete blood count, SMA-18, urinalysis, and VDRL were normal. The chest roentgenogram showed left ventricular enlargement and pulmonary vasculature congestion. The electrocardiogram revealed left ventricular hypertrophy. Right and left cardiac catheterization with angiography revealed marked prolapse of the posterior leaflet of the mitral valve with severe mitral insufficiency (*Fig. 1*) and mild pulmonary hypertension (PA: 45/8 mm Hg). Left ven-

tricular contractility and the coronary arteries were normal. Selective aortography was not performed.

The mitral valve was replaced (Starr-Edwards Model 6120 M4 prosthesis) in December 1976. Pathologic findings confirmed fibromyxoid degeneration. Convalescence was smooth with no murmur noted throughout the postoperative course. On routine examination 6 weeks postoperatively, a new Grade II/VI diastolic murmur at the left sternal border was noted. The blood pressure was 142/72 mm Hg. The electrocardiogram was unchanged and the chest film showed improvement. He was advised to increase activities and return to work.

His clinical condition gradually deteriorated until he was readmitted to the Cleveland Clinic Hospital in February 1978. For the first time, a wide pulse pressure was noted (blood pressure 130/40 mm Hg). Cardiac examination revealed diffuse point of maximal impulse at the sixth left intercostal space outside the midclavicular line with a

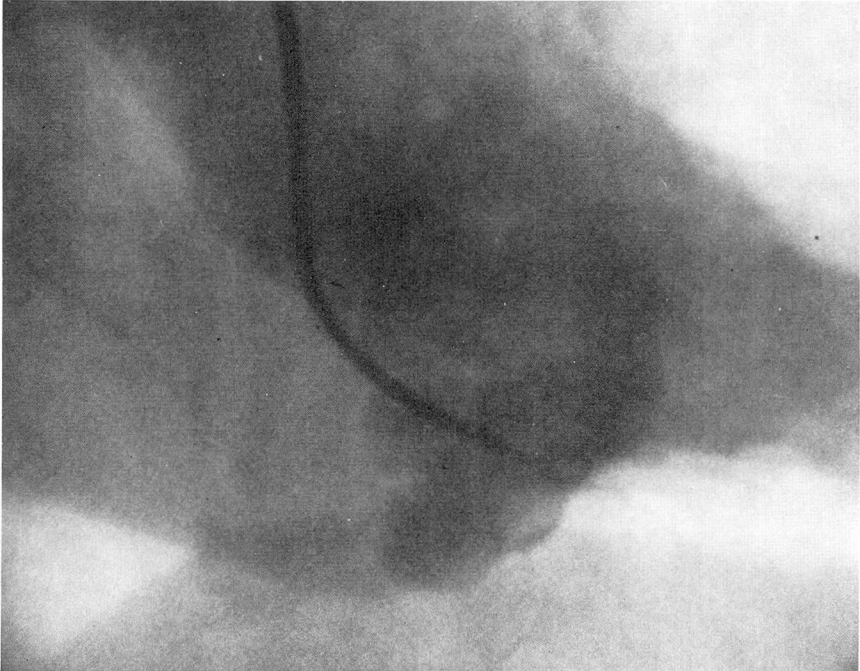


Fig. 1. Left ventriculogram during the first cardiac catheterization showing marked prolapse of the posterior leaflet of the mitral valve with moderately severe mitral insufficiency.

left ventricular lift. Prosthetic sounds were good. A Grade III/VI early diastolic blowing murmur and a Grade II/VI systolic ejection murmur were present at the lower left sternal border radiating to the base. The electrocardiogram remained unchanged. The chest film showed increasing cardiac size. The laboratory data were unremarkable.

Recatheterization showed normal prosthetic function and no evidence of a periprosthetic leakage. Ventriculography revealed moderate impairment of left ventricular contractility with increased end-diastolic and end-systolic volumes (left ventricular end-diastolic pressure = 18 mm Hg). Aortography revealed severe aortic insufficiency.

The aortic valve was replaced (Starr-Ed-

wards Model 1260 A11 prosthesis). At surgery, a large fenestration of the noncoronary cusp was noted. The aortic annulus was not calcified and the ascending aorta was unremarkable. Examination of the aortic valve revealed extensive myxoid degeneration (*Fig. 2*). Postoperative convalescence was smooth and at postoperative follow-up 6 weeks later, he was doing well without clinical evidence of valvular insufficiency.

Discussion

Read et al¹ reported nine cases of valvular myxomatous degeneration proved either at surgery or autopsy. Two of these patients had histologic diagnosis of myxomatous degeneration




Fig. 2. High power view of the aortic valve showing fibromyxoid degenerative process similar to that of the mitral valve (hematoxylin and eosin stain, $\times 200$).

of both mitral and aortic valves. One had presenting symptoms of massive isolated mitral insufficiency; the other had no clinical evidence of valvular incompetence. Davis et al¹¹ noted one case of moderate aortic insufficiency in a group of five patients with severe mitral insufficiency due to myxomatous degeneration. In 1972, Cooley et al¹² reported on 50 patients who underwent valve replacement for severe mitral insufficiency. One of these patients required simultaneous replacement of his aortic valve because of myxomatous disease. Therefore, significant multiple valve involvement, although not common, can occur secondary to myxomatous degeneration. Our patient initially had presenting symptoms of mitral insufficiency without clinical evidence of aortic valvular involvement. Five months after uneventful mitral valve replacement, congestive heart failure developed secondary to aortic insufficiency.

Three mechanisms by which myxomatous degeneration of the aortic valve can lead to aortic insufficiency have been described. First, a central defect can occur secondary to retraction and prolapse of curled and wrinkled aortic valve cusps. This occurred in three patients with pure aortic insufficiency reported by Read et al.¹ Second, spontaneous detachment of the diseased cusp from the aortic annulus allows prolapse into the left ventricle with sudden onset of severe aortic insufficiency. Two such cases were reported by O'Brien et al¹³ in 1968. Third, spontaneous rupture of a fenestrated leaflet can occur. Fenestration of the semilunar valves is often found at autopsy, but aortic insufficiency usually does not result, since the fenestration is above the line of valve closure. However, hypertension, syphilitic aortitis, dilatation of the ascending

aorta, or myxomatous degeneration can predispose a weakened fenestrated valve to spontaneous rupture and aortic insufficiency.^{14, 15}

The pathogenesis of myxomatous or mucoid degeneration is still unknown. Myxomatous degeneration has also been noted to involve the mitral annulus, papillary muscles, chordae tendineae and large arteries, aside from the mitral and aortic valves. The surgical importance of this entity lies in the tendency for disruption of suture lines and dehiscence of valve prostheses¹⁶ related to the friability of the valve annulus or the aorta or both.

The case reported here illustrates that surgically significant myxomatous degeneration of a cardiac valve is not always an isolated event. It may also be progressive, affecting different cardiac valves at different times requiring sequential valve replacement.

Summary

A case of progressive myxomatous degeneration of the mitral and aortic valves is reported. Clinical manifestations of valvular insufficiency occurred as isolated events requiring sequential prosthetic valve replacement. A review of the literature reveals that this is a rare occurrence.

References

1. Read RC, Thal AP, Wendt VE: Symptomatic valvular myxomatous transformation (the floppy valve syndrome). A possible forme fruste of the Marfan syndrome. *Circulation* 32: 897-910, 1965.
2. Nadas AS, Thilenius OG, LaFarge CG, et al: Ventricular septal defect with aortic regurgitation, medical and pathologic aspects. *Circulation* 29: 862-873, 1964.
3. Berenson GS, Geer JC: Heart disease in the Hurler and Marfan syndromes. *Arch Intern Med* 111: 58-69, 1963.
4. Brandt KD, Sumner RD, Ryan TJ, et al:

- Herniation of mitral leaflets in the Ehlers-Danlos syndrome. *Am J Cardiol* **36**: 524-528, 1975.
5. Hynes KM, Frye RL, Brandenburg RO, et al: Atrial septal defect (secundum) associated with mitral regurgitation. *Am J Cardiol* **34**: 333-338, 1974.
 6. Brown OR, DeMots H, Kloster FE, et al: Aortic root dilatation and mitral valve prolapse in Marfan's syndrome; an echocardiographic study. *Circulation* **52**: 651-657, 1975.
 7. Jeresaty RM: Etiology of the mitral valve prolapse-click syndrome. *Am J Cardiol* **36**: 110-113, 1975.
 8. Procacci PM, Savran SV, Schreiter SL, et al: Prevalence of clinical mitral-valve prolapse in 1169 young women. *N Engl J Med* **294**: 1086-1088, 1976.
 9. Appelblatt NH, Willis PW III, Lenhart JA, et al: Ten to 40 year follow-up of 69 patients with systolic click with or without apical late systolic murmur. (Abstr) *Am J Cardiol* **35**: 119, 1975.
 10. Mills P, Rose J, Hollingsworth J, et al: Long-term prognosis of mitral-valve prolapse. *N Engl J Med* **297**: 13-18, 1977.
 11. Davis RH, Schuster B, Knoebel SB, et al: Myxomatous degeneration of the mitral valve. *Am J Cardiol* **28**: 449-455, 1971.
 12. Cooley DA, Gerami S, Hallman GL, et al: Mitral insufficiency due to myxomatous transformation; "Floppy valve syndrome." *J Cardiovasc Surg* **13**: 346-349, 1972.
 13. O'Brien KP, Hitchcock GC, Barratt-Boyes BG, et al: Spontaneous aortic cusp rupture associated with valvular myxomatous transformation. *Circulation* **37**: 273-278, 1968.
 14. Marcus FI, Ronan J, Misanik LF, et al: Aortic insufficiency secondary to spontaneous rupture of a fenestrated leaflet. *Am Heart J* **66**: 675-678, 1963.
 15. Castleman B, Towne VW: Case records of Massachusetts General Hospital. *N Engl J Med* **245**: 941, 1951.
 16. Read RC, Thal AP: Surgical experience with symptomatic myxomatous valvular transformation (the floppy valve syndrome). *Surgery* **59**: 173-182, 1966.