

Aplastic anemia

Effect of antithymocyte globulin on erythroid colony formation

Susan A. Rothmann
Hamburger, Ph.D.

*Department of Laboratory Hematology and
Blood Banking*

James H. Finke, Ph.D.

Division of Research

Dennis L. Laffay, M.D.

*Department of Laboratory Hematology and
Blood Banking*

Ronald M. Bukowski, M.D.
James S. Hewlett, M.D.

*Department of Hematology and Medical
Oncology*

George C. Hoffman, M. B.,
B. Chir., F.R.C. Path.

*Department of Laboratory Hematology and
Blood Banking*

Acquired aplastic anemia is a diverse hemato-poietic disorder in which pancytopenia is associated with extremely reduced bone marrow cellularity. Although certain drugs, organic solvents, and viral infections have been found to antedate this disorder,¹ an etiologic agent cannot be identified in approximately 50% of patients.² In cases where a toxic agent or infection can be implicated in causing the disease, the exact pathogenesis is unknown.³ Experimental and clinical evidence has been accumulating to show that in some cases of acquired aplastic anemia, a population of lymphocytes is present which can suppress normal hematopoiesis.⁴⁻¹⁰ Based on these findings, several clinical trials have been initiated using antithymocyte globulin (ATG) as a therapeutic agent. We report the results of a study of bone marrow erythroid colony formation in a patient with idiopathic aplastic anemia before and after ATG therapy.

Case report

A 12-year-old girl with aplastic anemia of 3 weeks' duration was referred to The Cleveland Clinic Foundation for further evaluation and treatment. Her clinical course is diagrammed in *Figure 1*. Blood and bone marrow evaluations at admission revealed marked pancytopenia and hypocellular marrow (*Table 1*). There was no history of exposure to myelotoxic substances, recent infection, or previous hematologic disease. Peripheral blood lympho-

cytes contained numerous nonspecific chromosome breaks in 80% of metaphases examined (*Fig. 2A*); however, no other signs of Fanconi's syndrome were present. Bone marrow transplantation was considered, but no suitable donor was available. Treatment with equine ATG (Upjohn, lot 17, 912 [-5]) was initiated 2 weeks after admission. Five hundred milligrams of ATG were administered by continuous intravenous infusion over a 4-hour period on 5 alternate days. Subsequent bone marrow studies are listed in *Table 2*. Serum sickness developed on the last day of ATG infusion and resolved after a 5-day course of prednisone. Marrow biopsy and aspirate specimens on the eighth day after completion of ATG therapy were hypocellular (less than 5%). No chromosome breaks were present in peripheral blood lymphocytes cultured on day 18 (*Fig. 2B*). By day 65 her marrow cellularity increased to 30% and remained unchanged through day 94. Her peripheral leukocyte count rose to $2 \times 10^9/l$ with 35% mature neutrophils. The marrow and leukocyte counts indicated a partial response to therapy. The patient has

continued to require frequent transfusions of platelets and red blood cells.

Methods

All clinical and experimental studies were performed with informed consent as part of a therapeutic protocol approved by the Institutional Review Committee. Normal bone marrow was obtained from hematologically normal individuals having bone marrow aspiration as part of their diagnostic testing.

Bone marrow collection. Ten milliliters of bone marrow was collected in a plastic syringe containing 1000 U of preservative-free heparin (Fellows Medical Manufacturing Co, Inc) with a Jamshidi needle. To remove mature granulocytes and erythrocytes, the marrow was layered over a ficoll-hypaque gradient and centrifuged at 400 g for 60 minutes at room temperature. The mononuclear cells were retrieved and

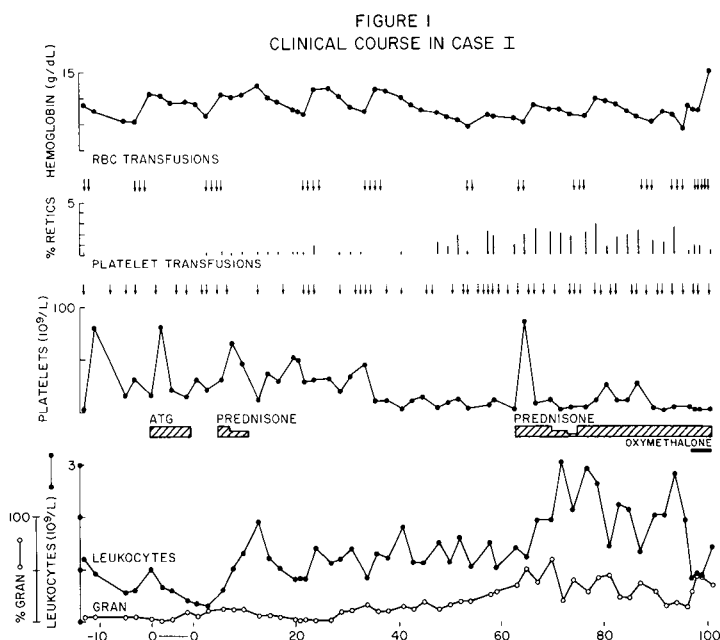


Fig. 1. Case 1; clinical course.

washed three times in alpha medium (Flow Labs) containing 30% fetal calf serum, penicillin (100 U/ml) and streptomycin (100 µg/ml). The final cell concentration was adjusted to approximately 10⁶/ml.

Erythroid colony culture. Marrow cells were depleted of granulocyte-macrophage colony-stimulating factor activ-

ity by the method of Messner et al.¹¹ Thus, the cell suspension was placed in 10 × 35 mm “tissue culture” (not Petri) dishes (Flow Labs) and incubated at 37 C in a humidified atmosphere containing 5% CO₂. After incubation overnight the nonadherent cells were removed and the cell concentration was adjusted to 5 × 10⁵/ml. The cells were cultured in “nontissue culture” (Petri) dishes in alpha medium containing 0.8% methylcellulose as described by Iscove et al.¹² with and without the addition of 1.5 U/ml erythropoietin (Ep) or 250 µg/ml ATG (Upjohn, lot 17, 912 [-5]). The Ep (supplied by the National Heart, Lung, and Blood Institute) had a specific activity of 100 U/ml and contained no detectable granulocyte colony stimulating activity. The ATG was dialyzed against normal saline for 24 hours at 4 C to remove the preservative, thimersol.

Table 1. Summary of admission hematologic values*

	Patient	Normal
White blood cell, 10 ⁹ /l	1.2	4-11
Granulocytes, %	4	40-73
Hemoglobin, g/dl	8.9	14.4
Platelets, 10 ⁹ /l	3	150-400
Normalized reticulocytes, %†	0.06	0.2-2.0
Serum erythropoietin, mIU‡	75	37-75
Marrow cellularity—biopsy, %	5	50
Granulocytes, %	5	50-80
Erythrocytes, %	1	15-35
Lymphocytes, %	94	5-15

* After transfusion of packed red cells.
† Reticulocyte, % × Hct/nl Hct.
‡ Measured by hemagglutination-inhibition.

Results
Erythroid colony formation before ATG treatment. The number of erythroid colonies formed per 10⁵ nucleated bone marrow cells plated is shown in

Table 2. Summary of bone marrow hematologic values

Date of aspi- rate*	Cellularity, %	L:E ratio	Megakaryocytes	Granulo- cytic pre- cursors, %	Erythroid precur- sors, %	Lympho- cytes, %	Plasma cells, %
Admission	10	...	0	13	1	79	7
-7	10	...	Present but marked de- crease	9	2	48	32
8	10-30	...	0	8	Rare	92	4
16	10	13:1	Marked decrease	19	7	67	5
23	10	13:1	Rare	23	7	65	5
30	10	...	One identified	5	0	84	11
38	10-20	11:1	Rare	60	9	25	5
49	10	8:1	Marked decrease	46	11	41	2
65	30	2.3:1	Marked decrease	45	30	14	11
78	20	1:1.5	Marked decrease	22	58	29	1
94	40	1:1.5	Marked decrease	35	56	9	

* Days after completion of ATG treatment.




Fig. 2. A, Before ATG treatment. Numerous breaks present. B, After treatment. No breaks observed.

Table 3. Only rare colonies were formed in the presence of 1.5 U Ep in contrast to 200–300 erythroid colonies formed by 10⁵ normal bone marrow cells. Cultures to which both Ep and ATG were added contained normal numbers of erythroid colonies which stained positive for hemoglobin with benzidine. ATG alone has had no effect on erythroid colony formation.

Erythroid colony formation after ATG therapy. Cultures prepared from marrow obtained 52 days after ATG treatment was completed responded normally to Ep added alone with formation of benzidine-positive colonies. Addition of ATG caused no further increase in the number of erythroid colonies.

Discussion

The in vitro and clinical data presented here confirm the idea that in some cases of aplastic anemia, an immunologic mechanism may be responsible for the disease. Marrow from our patient did not respond normally in vitro to Ep alone, but when coincubated with Ep and ATG, a dramatic increase in erythroid colony formation was observed.

The patient appears to have a partial response to ATG therapy. Her bone marrow cellularity has increased and the circulating granulocyte and reticulocyte counts are significantly higher than pretreatment values. The normal erythroid colony response to erythropoietin also represents a positive change. However, she continues to require red cell and platelet transfusions. The patient's pretreatment peripheral blood lymphocytes contained numerous chromosome breaks, which were not present after ATG therapy. The high frequency of breaks makes an in vitro artifact unlikely, and may indicate DNA instabil-

Table 3. Erythroid colonies in untreated aplastic anemia

Additions to culture	Colonies per 10 ⁵ plated cells	
	Patient	Normal
Bone marrow alone	1	0
Marrow + ATG	Not done	0
Marrow + Ep	8	200–300
Marrow + ATG + Ep	225	200–300

Each result represents the average of two culture plates.

ity in an abnormal clone of lymphocytes.¹³ The disappearance of chromosome breaks after ATG treatment may represent elimination of the abnormal cells by the antibody preparation.

Several investigators have presented results that suggest that some patients with aplastic anemia possess a population of lymphocytes that can suppress erythropoiesis⁴ and granulopoiesis in culture.^{7, 8} Furthermore, clinical evidence supporting this concept is contained in several reports of bone marrow recovery from aplasia after treatment with immunosuppressive agents including antilymphocyte globulin.^{5, 6, 9, 10} A direct assay of human pluripotent stem cells is not available; thus, studies of more differentiated hematopoietic precursor cells must be used as an indirect indicator of stem cell function. Our results show that the marrow from a patient with aplastic anemia was not capable of responding normally in vitro to Ep. When coincubated with Ep and ATG, normal erythroid colony formation was restored. This suggests that the ATG inhibited a population of lymphocytes that suppress normal hematopoiesis at a multipotential cell level in this patient. In addition, the patient's improved clinical course and normal posttreatment erythroid colony formation provide further evidence that lymphocyte-mediated suppression of bone

marrow stem cells may represent a pathogenetic mechanism in some cases of aplastic anemia.

References

1. Williams DM, Lynch RE, Cartwright GE: Drug-induced aplastic anemia. *Semin Hematol* **10**: 195-223, 1973.
2. Corrigan GE: An autopsy survey of aplastic anemia. *Am J Clin Pathol* **62**: 488-490, 1974.
3. Stohlman F Jr: Aplastic anemia. *Blood* **40**: 282-286, 1972.
4. Hoffman R, Zanjani ED, Lutton JD, et al: Suppression of erythroid-colony formation by lymphocytes from patients with aplastic anemia. *N Engl J Med* **296**: 10-13, 1977.
5. Speck B, Gluckman E, Haak HL, et al: Treatment of aplastic anaemia by antilymphocyte globulin with and without allogeneic bone-marrow infusions. *Lancet* **2**: 1145-1148, 1977.
6. Jeannet M, Speck B, Rubinstein A, et al: Autologous marrow reconstitutions in severe aplastic anaemia after ALG pretreatment and HL-A semi-incompatible bone marrow cell transfusion. *Acta Haematol* **55**: 129-139, 1976.
7. Ascensao J, Kagan W, Moore M, et al: Aplastic anaemia; evidence for an immunological mechanism. *Lancet* **1**: 669-671, 1976.
8. Kagan WA, Ascensao JA, Pahwa RN, et al: Aplastic anemia; presence in human bone marrow of cells that suppress myelopoiesis. *Proc Natl Acad Sci* **73**: 2890-2894, 1976.
9. Royal Marsden Hospital Bone-Marrow Transplantation Team: Failure of syngeneic bone-marrow graft without preconditioning in post-hepatitis marrow aplasia. *Lancet* **2**: 742-745, 1977.
10. Thomas ED, Storb R, Giblett ER, et al: Recovery from aplastic anemia following attempted marrow transplantation. *Exp Hematol* **4**: 97-102, 1976.
11. Messner HA, Till JE, McCulloch EA: Interacting cell populations affecting colony formation by normal and leukemic human marrow cells. *Blood* **42**: 701-710, 1973.
12. Iscove NN, Sieber F, Winterhalter KH: Erythroid colony formation in cultures of mouse and human bone marrow; analysis of the requirement for erythropoietin by gel filtration and affinity chromatography on agarose concanavalin A. *J Cell Physiol* **83**: 309-320, 1974.
13. Hashimoto Y, Takaku F, Kosaka K: Damaged DNA in lymphocytes of aplastic anemia. *Blood* **46**: 735-742, 1975.