

The mesenteric sling technique

New method of constructing an intestinal nipple valve for the continent ileostomy

Les Bokey, M.B., B.S.,
F.R.A.C.S.
Victor W. Fazio, M.D.

*Department of Colon and Rectal
Surgery*

In 1967, Kock¹ devised a continent ileostomy consisting of a low pressure terminal ileal reservoir and an outlet. At first, the indications for this procedure included proctocolectomy for ulcerative colitis, familial polyposis, and in some instances Crohn's disease. It soon became obvious, however, that the risks of constructing a reservoir in a patient with Crohn's disease were considerable, and now Crohn's disease is a definite contraindication. Since 1967, there have been several technical modifications mainly associated with the outlet mechanism. These have been necessitated by a considerable reoperation rate for incontinence.

In the original procedure the terminal ileum distal to the reservoir was simply brought out obliquely through the rectus muscle and excised flush with the skin. No special valvular mechanism was constructed and continence depended on the sphincteric action of the rectus muscle on the terminal ileum. Some of these patients did well and remained continent, but in many patients incontinence developed, and the concept of the nipple valve was devised by Kock.

The nipple valve is constructed by intussuscepting 8 cm of the terminal ileum into the reservoir and, indeed, it does function as a

continent valve as long as the intussusception is maintained. Unfortunately it has a natural tendency to dessuscept. This usually occurs on the mesenteric side, presumably because this is the bulkier and more difficult side to fix. The first signs usually occur after the third postoperative month. The patient usually complains of difficulty in catheterizing the reservoir and soon incontinence develops.

Several methods have been used to prevent dessusception:

1. Myotomy. The seromuscularis was myotomized to promote healing between the opposed segments. This technique which was described by Turnbull and Fazio² is useful in promoting healing on the antimesenteric side of the intussusception. However, since it cannot be applied to the mesenteric side, dessusception can still occur on that side.

2. Through-and-through sutures. Through-and-through sutures were used to try to fix the opposed segments of bowel. These helped matters somewhat, but created a problem of their own. Some tore through creating a fistula, usually at the base of the nipple valve. This rendered the patient incontinent, since the reservoir contents bypassed the nipple valve through the fistulous tract.

3. Staples. Staples have been used on both the antimesenteric and the mesenteric sides of the intussusception. On the mesenteric side, two rows of staples were used on either side of the vascular component. This technique, which has been used by Fazio has not been entirely satisfactory in preventing dessusception on the mesenteric side.

4. Stripping of the mesentery and placement of rotation suture. Strip-

ping of the mesenteric peritoneum and defatting the mesentery was suggested by Madigan³ in 1974 and adopted by Kock et al,⁴ who introduced a new technique of nipple valve construction in 1977. In this technique, the mesentery is deperitonealized and defatted, and a rotation suture is placed through its middle to rotate the two segments of bowel to be intussuscepted and thus to redistribute the bulky mesentery over a wider area of the bowel circumference.

Although this technique has helped reduce the rate of nipple valve sliding, this complication continues to occur and remains the single major technical problem associated with the continent ileostomy. Because of this a new technique of nipple valve construction was sought and specific attention was directed to the mesenteric side of the intussusception where most of the problems appeared to be.

The new technique makes use of a strip of fascia which is threaded in such a way as to fix effectively the mesenteric side of the intussusception.

Mesenteric sling technique

The operation is performed on a dog under general anesthesia. The operator stands at the left side. A midline incision is made and the peritoneal cavity is entered. With cutting diathermy a 0.5 by 5 cm strip of fascia is excised from the left posterior rectus fascia. The terminal ileum is identified and divided as close to the ileocecal junction as possible. In the dog it is considered important to make use of the terminal ileum in constructing the nipple valve, because its mesentery more closely re-

sembles human mesentery than proximal ileal mesentery, which in the dog tends to be relatively flimsy and not bulky. The distal end of the ileum is then closed in two layers of interrupted 3-0 chromic catgut and interrupted seromuscular 3-0 ethibond sutures and returned to the peritoneal cavity.

The following lengths are now carefully measured from the terminal ileum (*Fig. 1*): (1) 5 cm to construct the external ileostomy; (2) 8 cm for the nipple valve; (3) 2 cm to assist in closing the reservoir; (4 and 5) Two 15-cm loops which are joined along the antimesenteric border in a U-shape to construct the reservoir. An umbilical tape is applied proximally to minimize contamination.

The two 15-cm segments are opposed with a posterior seromuscular layer of interrupted 3-0 ethibond sutures (*Fig. 2*). Each limb is opened

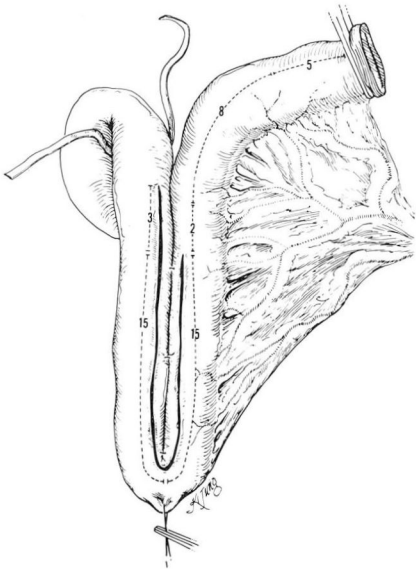


Fig. 1. Two limbs of terminal ileum, each 15 cm long, approximated along their antimesenteric borders using an interrupted seromuscular suture.

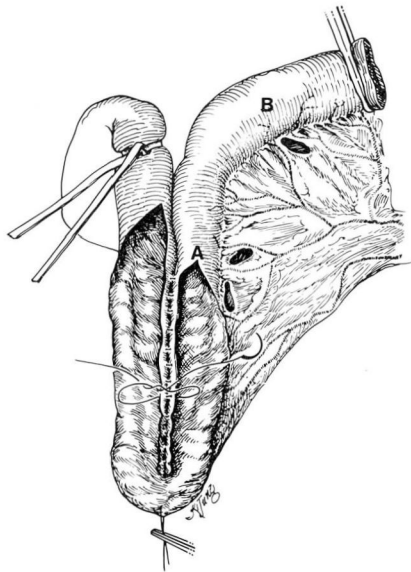


Fig. 2. Each limb is opened and posterior anastomosis is completed. Three small mesenteric windows are made close to bowel wall.

close to the posterior layer starting at the apex of the U. The incision on the afferent limb is extended 3 cm further to help close the reservoir. The posterior anastomosis is completed using through-and-through interrupted 3-0 chromic catgut sutures.

Attention is directed to the construction of the nipple valve. Three windows are made in appropriate avascular spaces on the mesenteric side close to the bowel wall (*Fig. 2*). Two windows are made 2 cm proximal to the intended beginning of the valve (point A) and one window opposite the intended end of the valve (point B). A Kelly forceps is passed through these windows and the strip of fascia is threaded through (*Figs. 3 and 4*).

The valve is intussuscepted (*Fig. 5*) and the fascia sling encircles the base of the nipple. A Medina catheter is passed through the valve into the

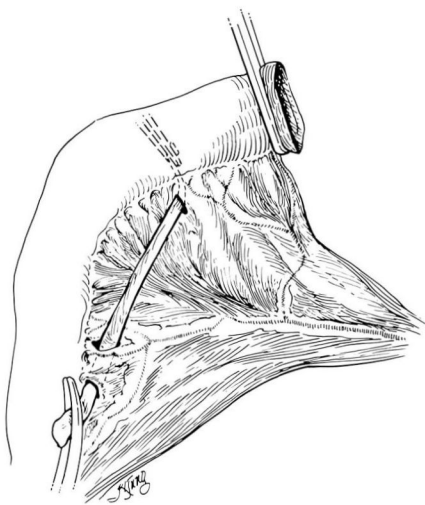


Fig. 3. Strip of fascia 0.5×5 cm is threaded through windows.

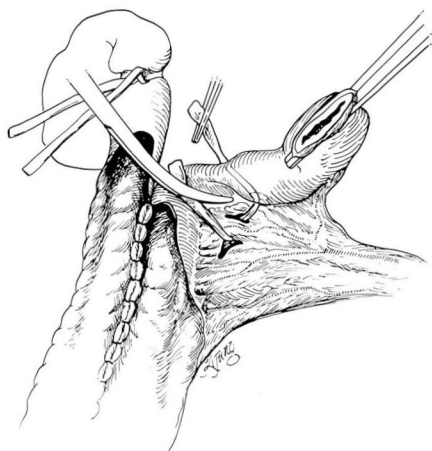


Fig. 4. Strip of fascia threaded through all windows.

reservoir and care is taken to ensure that the fascia sling is not unduly tight and permits easy passage of the catheter into the reservoir (*Fig. 6*).

Several interrupted 3-0 ethibond sutures are placed to hold the fascia in place (*Fig. 6*). These sutures include the opposed seromuscularis and a full thickness bite of the fascia. They are tied and kept long, and will

be used to secure the reservoir to the ileostomy exit site.

The reservoir is folded over itself (*Fig. 7*) and closed in two layers of interrupted 3-0 chromic catgut sutures and interrupted seromuscular 3-0 ethibond sutures. The pos-

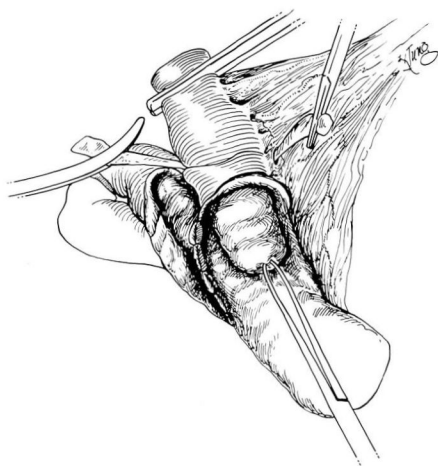


Fig. 5. Four centimeters of terminal ileum is intussuscepted into reservoir to construct nipple valve.

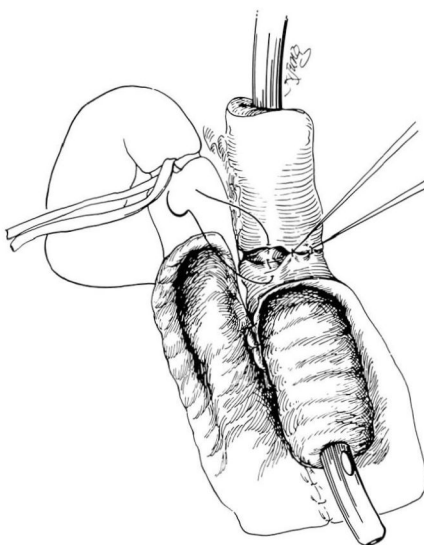


Fig. 6. Medina catheter is inserted into reservoir. Interrupted sutures are used to hold fascia strip in place.

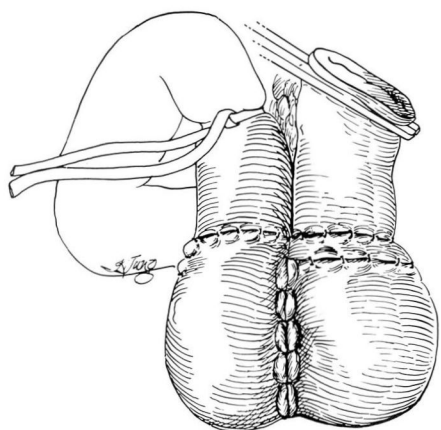


Fig. 7. Intestinal plate is folded over to close reservoir.

terior aspect of the reservoir is brought into view by placing the whole reservoir between the mesenteric leaves as described by Kock. Continence is tested by injecting 200 cc of air into the reservoir via a Medina catheter.

A suitable site is selected for the ileostomy exit wound. A 1-cm disc of skin is excised at the proposed site and the rectus fascia is divided in a cruciate fashion. The rectus muscle is split with a Kelly forceps, and the posterior rectus sheath is divided with cutting diathermy sufficiently to admit one finger.

The posterior row of 3-0 ethibond sutures which had been kept long are used to secure the posterior aspect of the base of the nipple to the posterior edge of the ileostomy exit wound.

The terminal ileum is then passed through the ileostomy exit site, and the anterior row of 3-0 ethibond sutures which had been kept long are used to fix the anterior aspect of the nipple base to the anterior edge of the ileostomy site.

The reservoir mesentery is sutured to the parietal peritoneum using in-

terrupted 3-0 chromic catgut sutures to obliterate the paraileostomy space.

Before closing the peritoneal cavity, it is important to ensure easy passage of a Medina catheter into the reservoir. The abdomen is now closed with a continuous layer of O-Prolene and a continuous layer of subcuticular 3-0 Dexon sutures.

Results

The efficacy of this technique has been demonstrated in dog experiments. Continent ileostomies using the fascia sling technique have been constructed in 10 dogs. The survival period has varied between 10 days and 8 weeks postoperatively. All the dogs remained fully continent up to the dates of death. Three of the animals were killed after 3 weeks to assess progress. The other seven died of causes unrelated to the technique of nipple valve construction. In all the animals, attempts to dessuscept manually the valve at postmortem failed, and macroscopically there appeared to be solid healing around the base of the nipple valve and especially on its mesenteric side. Vascular compromise was not noted in any of the valves constructed with this technique.

All the valves were subjected to histologic scrutiny. In all, there was evidence of fibrosis and healing especially on the mesenteric side of the intussusception.

The mesenteric sling technique was used in two dogs to construct a continent transverse colostomy. Both dogs are in their fourth postoperative week and both remain fully continent.

The technique has also been applied to each of two patients with a continent ileostomy in whom the nipple valve had dessuscepted after the

third postoperative month. In both patients staples had been used to construct the nipple valve and in both dessusception had occurred on the mesenteric side. In these patients a strip of ox fascia was used rather than the patient's own fascia. Both patients have been followed up for 4 and 5 months respectively and both remain continent.

The continent ileostomy is an exciting concept. It has now been applied to several hundred patients around the world. The major problem associated with it has been and continues to be dessusception of the nipple valve. This complication is difficult to manage and frequently requires several reoperations.

It is believed that the mesenteric sling technique, by reducing or eliminating this problem, will render the continent ileostomy a more attractive proposition to both patient and surgeon.

This mesenteric sling technique has several advantages:

1. It is easy to perform and is not time consuming.
2. It fixes effectively the mesenteric side of the intussusception.
3. It provides an easy method of fixing the reservoir to the ileostomy exit site.
4. It may be used in combination with other techniques such as myotomy or staples.

The results obtained so far on both animal experiments and human ap-

plication have been encouraging. Animal research is still in progress, and a full report will be published.

Summary

In 1967, Kock¹ introduced the continent ileostomy. Since then the results of this procedure have gradually improved. Unfortunately incontinence develops in 30% to 40% of patients usually in the third postoperative month. This is usually due to dessusception of the nipple valve which is an integral and essential part of the continent mechanism.

A new technique of constructing intestinal nipple valves was devised. Specific attention was directed to the mesenteric side of the intussusception where most of the problems appeared to be. The technique was used successfully in dog experiments and has now been applied to two patients at the Cleveland Clinic.

References

1. Kock NG: Intra-abdominal "reservoir" in patients with permanent ileostomy; preliminary observations on a procedure resulting in fecal "continence" in five ileostomy patients. *Arch Surg* **99**: 223-231, 1969.
2. Turnbull RB Jr, Fazio V: Advances in the surgical technique of ulcerative colitis surgery: endoanal proctectomy and two-directional myotomy ileostomy. *Surg Annu* **7**: 315-329, 1975.
3. Madigan MR: The continent ileostomy and the isolated ileal bladder. *Ann R Coll Surg Engl* **58**: 62-69, 1976.
4. Kock NG, Darle N, Hulten L, et al: Ileostomy. *Curr Probl Surg* **14**: 1-52, 1977.