

# Craniosynostosis and related syndromes

## *Pathogenesis and treatment*

Joseph F. Hahn, M.D.

*Department of Neurological Surgery*

John A. Jane, M.D.\*

The term craniostenosis was coined by Virchow<sup>1</sup> in 1851. He suggested that when premature fusion of the cranial vault occurs, there is an inhibition of the normal growth of the skull in the direction perpendicular to the suture which is fused. This results in a compensatory growth in a direction parallel to the fused suture.

Because not much is known about the pathogenesis of craniostenosis, there is much confusion concerning the need for, the timing of, and the forms of treatment. Treatment is directed usually at the closed suture. This is not the origin of the problem but the result. Because of this lack of understanding, the cranial sutures often reclose prematurely. Many attempts have been made to prevent this occurrence. No procedure is universally successful; hence the great number of variations. These include painting the dura with Zenker's solution, applying polyethylene film to the suture line, and removing the suture. It is our impression that reclosure following craniostynostectomy can be prevented. Attention must be given to the underlying pathology which will be discussed.

The normal cranial sutures are closed in a fibrous union by 6 months of age. By 20

---

\* *Department of Neurological Surgery, University of Virginia, Charlottesville, Virginia.*

months, the anterior fontanelle has closed. At approximately 8 years of age, the bones are completely ossified. Craniosynostosis by definition is present shortly after birth.

Craniosynostosis is not an uncommon problem. The incidence is approximately 5 per 10,000 births.<sup>2</sup> Matson<sup>3</sup> reported on 519 cases collected between 1930 and 1966. Sagittal synostosis, the most common form, is much more common in boys; coronal synostosis is more common in girls. Craniosynostosis is rare in blacks. There are associated anomalies of other organ systems in 26% of children with sagittal synostosis and in 33% of children with coronal synostosis. If both coronal sutures are involved, the number with associated anomalies increases to 59%. Mental retardation is reported in approximately 5% of children with sagittal synostosis.<sup>2</sup>

It is not our intention to discuss the various terms given each form of suture closure. It is sufficient to note that all variations exist from partial closure of one cranial suture to premature closure of all sutures. More and more syndromes are being described with craniosynostosis as one of the features. The common ones are Crouzon's, Apert's, and Carpenter's; these syndromes account for approximately 10% of all cases of craniosynostosis.

The cause of craniosynostosis is not known. It is believed to be due to a prenatal event. The abnormality may not be fully expressed until after delivery. Intrauterine infection, radiation during pregnancy, syphilis, rickets, birth trauma, and anoxia have been incriminated, but are rarely present. Hyperthyroidism and hypophosphatemia have been reported to

cause premature suture closure. No etiologic agent has been definitely identified.

Heredity is a factor in craniosynostosis associated with Crouzon's, Apert's, and Carpenter's syndromes. Cohen<sup>4</sup> has reviewed the subject in detail.

All forms of craniostenosis demonstrate an abnormal relationship of the basal skull bones. Moss<sup>5</sup> has proposed a theory relating this finding to premature suture closure. Using this concept one can suggest a reasonable surgical approach to the problem.

Moss has suggested that abnormal tension within the dura causes premature suture closure. The dura is anchored in five places: the crista galli, the lesser wings of the sphenoid, and the petrous pyramids. These attachments produce tension in the dura. This tension transmits to the sutural area the appropriate messages concerning closure. How this is done is not known. The relationships of the sutures to the attachments are crista galli to sagittal suture, sphenoid bone to coronal suture, and petrous bone to lambdoid suture.

If there is a deformity at the point of attachment, tension within the dura is altered. The result is early closure of the suture line. For example, if there is a malformation of one sphenoid wing, there will be a unilateral closure of the coronal suture. This is confirmed by roentgenography.

Support for the Moss theory has been produced by Kontokollas<sup>6</sup> and Markens.<sup>7</sup> Markens was able to show the effect of basal dysplasia on the maturation of fibers in the dural capsule and its relation to closure of the sutural edges.

Bennett<sup>8</sup> and Seeger and Gabrielsen<sup>9</sup> have reported that cranial base dysplasia has a primary role in premature craniosynostosis. However, this idea is not widely accepted. In fact, many radiology texts do not describe abnormalities of the base in reviewing craniosynostosis. If the facial, sphenoid, and petrous bones are examined, aberrations are apparent. Matson<sup>3</sup> stated that "skull roentgenograms frequently also demonstrate associated abnormalities of the orbital, nasal, sphenoid, and maxillary bones." We suggest that if a close examination is made, abnormalities of the basal bones will be noted in most of these children. Abnormalities of the facial bones are characteristic of Crouzon's, Apert's, and Carpenter's syndromes. However, with sagittal synostosis, the frontal fossa is foreshortened and the orbits appear elevated (*Fig. 1*).

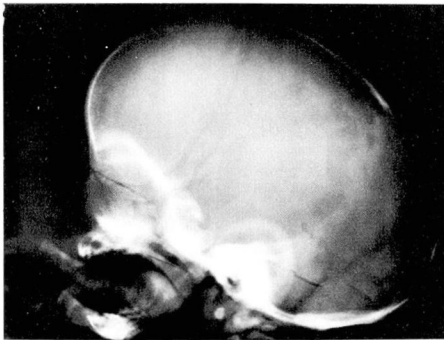
Campbell<sup>10</sup> described the findings in premature closure of the coronal or lambdoid suture. He pointed out that the classic signs of obliteration and ridging of the suture were frequently lacking. Coronal synostosis is characterized by asymmetric eleva-

tion of the lesser sphenoid wing and orbital roof on the affected side in the frontal projection (*Fig. 2*). The nasal septum and crista galli are often deviated to the side of closure.

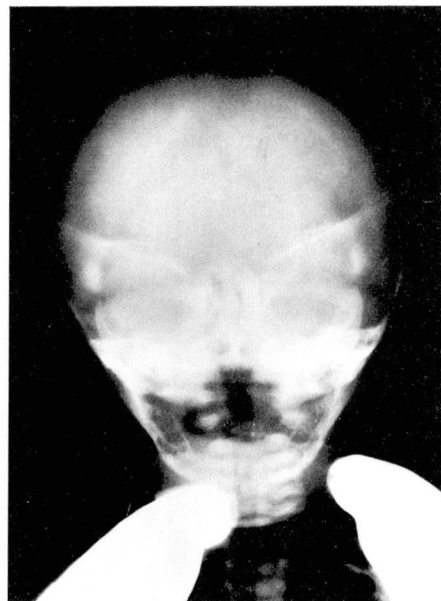
With unilateral lambdoid suture closure, there is deepening of the posterior fossa with shortening of the ipsilateral wall of the occipital fossa. These are the classic findings. Obviously, all varieties and combinations may coexist.

Accepting this idea, there are two ways to correct the craniosynostosis. The cranial base or dural forces must be changed. An attempt to reconstruct the basal skull bones would be a large undertaking. However, repair of Crouzon's anomalies requires this type of approach.

Changing the dural forces can be done easily. Jane<sup>11</sup> has described a simple maneuver of plicating the dura across the lines of tension. This



**Fig. 1.** Lateral roentgenogram of skull with sagittal craniosynostosis. Note foreshortening of frontal fossa and apparent elevation of orbital roof.

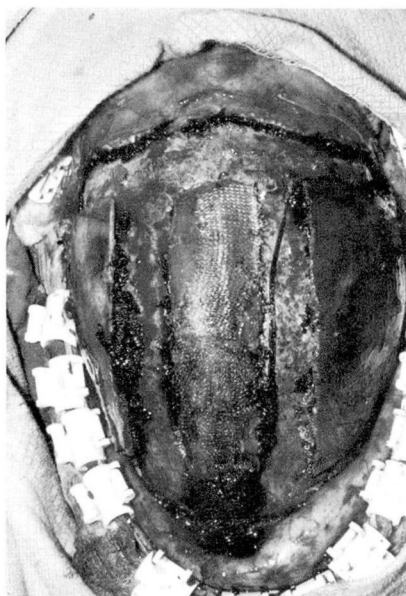

**Fig. 2.** Elevation of lesser sphenoid wings. The child has coronal synostosis bilaterally.

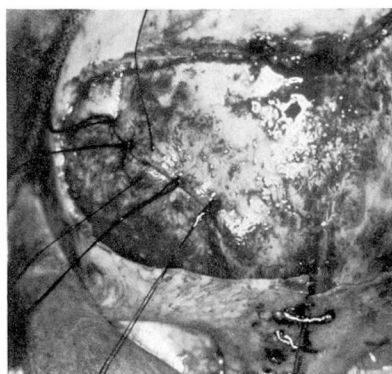creates a new set of information for the induction of suture closure.

A craniectomy is done in the form of the Greek letter  $\pi$ . The limbs are made on either side of the sagittal suture, and the suture is left in place. The horizontal portion of the craniectomy is carried along the coronal suture line bilaterally (Fig. 3). The dura is then plicated as shown in Figure 4. This alters the tension within the dura produced by the abnormal attachment areas. This procedure is useful for sagittal, unilateral, or bilateral coronal synostosis. The horizontal limb is placed at the lambdoid suture for premature closure in this area. The dura is plicated as before.

The alteration of the dura changes the tensile forces within it. Information is no longer transmitted to the sutural area and reclosure of the suture does not occur.



**Fig. 3.** Craniectomy defects shown at operation. The horizontal limb is across the coronal suture line at the top of the photograph.



**Fig. 4.** Intraoperative photograph showing dural plication.

To date, this approach has been used in over 40 cases of craniosynostosis. There has been no reclosure of suture lines. There have been three cases of increasing size of the craniectomy defect; these children required cranioplasties.

The indications for surgery remain debatable. There are two accepted indications: prevention of neurologic deficit associated with constriction and/or distortion of the growing brain and prevention of cosmetic deformity. The neurologic findings caused by constriction of the growing brain may include raised intracranial pressure, optic atrophy (either primary or secondary to raised intracranial pressure), bilateral pyramidal tract signs, and strabismus.

Andersson and Gomes<sup>12</sup> stated that when two or more sutures are involved, surgery is a virtual certainty. Increased intracranial pressure with or without ocular symptoms will develop in most of these patients.

We suggest treating these children as early as possible. Ideally the surgical decompression should be done before 3 months of age. There has been no need for reoperation for reclosure of the suture with this



method. The mortality is less than 0.5%. Morbidity consists of wound hematoma and infection and is less than 1%. As noted, three children required cranioplasties to close surgical defects. As we learn more about the dural forces, this group will be eliminated.

### Summary

A unified approach to the treatment of children with craniosynostosis and related problems has been presented. Correction of the premature suture closure requires alteration of the tensile forces within the dura, not removal of the offending suture. The indications for surgery are cosmetic deformity or neurologic deficit or both resulting from the synostosis. If necessary, surgical correction should be done as early as possible.

### References

1. Virchow R: *Verhandl d phys-med Gesellsch zu Würzburg* 2: 247, 1851. Cited by Faber HK: Craniosynostosis (Oxycephaly and related disorders), in *Contributions to Medical Science*, Stone WJ, ed. Ann Arbor, Wahr, 1927.
2. Menkes JH: *Textbook of Child Neurology*. Philadelphia, Lea and Febiger, 1974.
3. Matson DD: *Neurosurgery of Infancy and Childhood*. Springfield, Ill, Charles C Thomas, 1969.
4. Cohen MM: Genetic perspectives on craniosynostosis and syndromes with craniosynostosis. *J Neurosurg* 47: 886-898, 1977.
5. Moss ML: Functional anatomy of cranial synostosis. *Childs Brain* 1: 22-33, 1975.
6. Kontokollas J: Die Entwicklungskinetik der Schädelnähte. *Z Morph Anthropol* 57: 29-40, 1965.
7. Markens IS: De embryonale ontwikkeling van der sutura coronaria bij de Mens en de Rat en enige eigenschappen van dit Weefsel. Doctoral thesis, Utrecht, University of Utrecht, 1974.
8. Bennett KA: Craniostenosis; a review of the etiology and a report of new cases. *Am J Phys Anthropol* 27: 1-10, 1967.
9. Seeger JF, Gabrielsen TO: Premature closure of the frontosphenoidal suture in synostosis of the coronal suture. *Radiology* 101: 631-635, 1971.
10. Campbell JA: Roentgen aspects of cranial configurations. *Radiol Clin North Am* 4: 11-31, 1966.
11. Jane JA: Craniofacial anomalies and their repair. Presented at Southern Neurosurgical Society, Marco Island, March 3-5, 1976.
12. Andersson H, Gomes SP: Craniosynostosis; review of the literature and indications for surgery. *Acta Paediatr Scand* 57: 47-54, 1968.