

Surgical techniques

Ch. Hahn, M.D.
Ninoslav Radovanovic, M.D.
Martin Schmuziger, M.D.
E. Hauf, M.D.
B. Faidutti, M.D.

Geneva, Switzerland

Between January 1968 and September 1977, 1979 patients were operated on for coronary artery disease. This statistic is divided into five groups (*Table 1*). These groups are defined with regard to the pathologic specifications and the problems of surgical technique as well as the operative risk.

The surgical procedure is listed in *Table 2*. In the majority of cases, the bypass is achieved by way of a venous autotransplant, in general, saphenous. In a small number of cases, the internal mammary artery is anastomosed directly to the left anterior descending artery or the circumflex artery. A complementary coronary endarterectomy was performed in 21.8% of these cases.

Evolution

At the beginning of our experience, we performed mainly single bypasses on the right coronary artery. From 1969 the revascularization involved also the left anterior descending artery and the circumflex artery. As our surgical experience increased and the diagnoses became more precise, the character of myocardial revascularization became more and more complete, thanks to the increasing frequency of multiple bypasses.

Table 1. Groups of coronary patients

	No. of patients
Chronic coronary	1697
Acute coronary insufficiency	103
Left ventricular aneurysm	96
Associated valvular lesions	52
Associated vascular lesions	31
Total	1979

Table 2. Procedures used in this series

Surgical procedure	No. of patients
Simple	364
RCA 128	
LCA 236	
Double	728
LAD + RCX 164	
R + L 564	
Triple	548
Quadruple	165
Quintuple	18
Sextuple	2
DMR + Vineberg	6
DMR + LV aneurysm resection	81
IMAG	65
Patch	2
Total	1979

There is no doubt that the concept of complete revascularization allowed us to enlarge indications in the cases of diffuse coronary artery disease as well as in the cases of bad left ventricle (*Fig. 1*).

Extracorporeal circulation

At present, extracorporeal circulation is performed in total hemodilution. Bubble oxygenators are commonly used for short extracorporeal circulations. We are using membrane oxygenators increasingly for long interventions involving complete revascularization by multiple anastomoses; these oxygenators guarantee a better extracorporeal circulation and the possibility of circulatory assistance, if

need be. On the other hand, we recently introduced a pulsatile flow in extracorporeal circulation in the cases of bad left ventricular function and in a patient in very poor general condition. We are convinced that the use of a membrane oxygenator and of a pulsatile flow can assure greater security in high risk patients.

Myocardial protection

In the majority of cases, we perform a moderate hypothermia at 27 to 28 C. In such cases where the rest of coronary circulation is extremely poor, we use the local, intrapericardial cooling technique, by way of frozen serum at 4 C. This technique is also used in the cases of interventions for impending infarction. On the contrary, in the cases of a single bypass, we perform only a minimum hypothermia, at about 33 to 34 C or no hypothermia at all.

In general, it is not necessary to clamp the aorta more than 15 minutes for each anastomosis. According to a technique which has been used for almost 20 years, a left ventricle decompression on the apex is performed.

Coronary anastomoses

In general, an arteriotomy is 10 to 15 mm long. Anastomoses are performed by way of Prolene 7-0 or 6-0. The usual technique consists of using two hemicontinuous sutures (*Fig. 2A and B*), or a single continuous suture (*Fig. 2C and D*).

Whatever the technique, we must be particularly attentive at the passage of the distal end. For this reason, either we place a first suture on this distal end in order to visualize the vascular lumen and the graft, or we start placing a single continuous

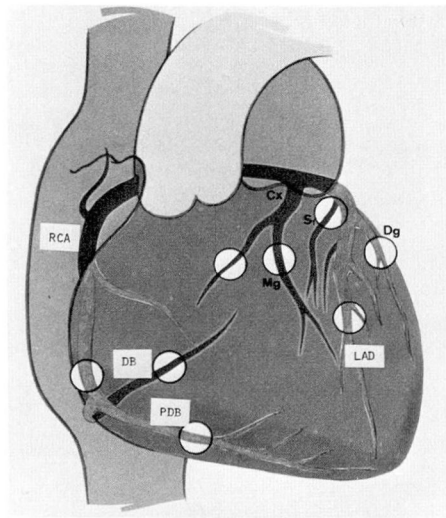


Fig. 1. Possibilities of coronary revascularization (distal implantations of the grafts).

suture on the lateral face of the arteriotomy in order to get over the distal end without the risk of stenosis of the latter. In any case, the anastomoses are controlled afterward by way of explorators.

Aortic anastomoses (*Fig. 3*)

These anastomoses are performed on the left anterolateral face for left grafts and on the right anterolateral face of the ascending aorta for right graft or grafts. The aortic anastomoses are usually performed under tangential clamping of the aorta. Before suturing the graft, a small window is made in the aortic wall. Anastomoses are performed by way of a single continuous Prolene 5-0 suture. The left grafts are placed in such a way as to avoid a compression at their passage over the pulmonary artery, after having been placed on the heart.

If grafts are inserted in the high part of the left anterior descending artery or of the circumflex artery, it

is sometimes better to pass them through the transverse sinus and graft them on the right posterolateral face of the ascending aorta in order to avoid any kinking of these grafts.

Coronary circulation reconstruction tactics

Reconstruction of the right coronary artery, left anterior descending artery, and circumflex artery are discussed.

Reconstruction of the right coronary artery. If lesions are situated at the trunk of the right coronary artery, this one is approached at its bifurcation in posterior descending

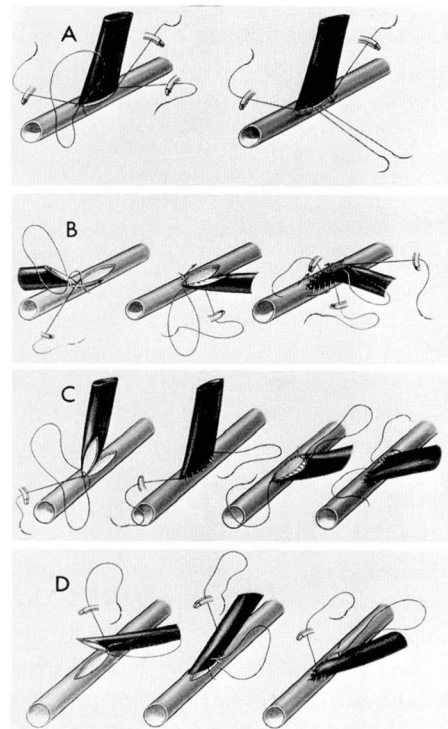


Fig. 2. A, Two hemicontinuous sutures: $\phi > 2$ mm. B, Two hemicontinuous sutures: $\phi < 2$ mm. Distal starting. C, Single continuous suture: $\phi \geq 2$ mm. Distal starting. D, Single continuous suture. Proximal starting (internal mammary artery).

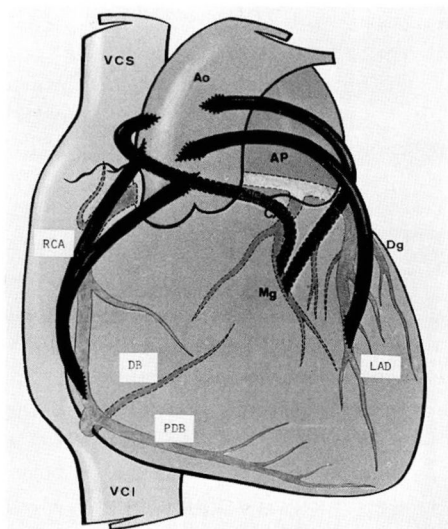


Fig. 3. Aortic anastomoses.

branch and diaphragmatic branch.

If lesions go beyond this bifurcation, if they are important, or if the right coronary artery branches are small and the intima is very thick, we perform an endarterectomy before placing the bypass.

If lesions are extended beyond the bifurcation and are bead-like, which are bad conditions for an endarterectomy, and if the right coronary artery branches are more than 1 mm in diameter, we prefer to perform revascularization of each branch of right coronary artery, more frequently by way of a jump-graft, with an end-to-side anastomosis on the diaphragmatic branch and a side-to-side anastomosis on the right posterior descending artery (Fig. 4).

Reconstruction of the left anterior descending artery. If the left anterior descending artery has a lesion at its origin, we perform a single bypass.

If the left anterior descending artery has distal lesions extended beyond the vessel's lower third, and if there is an important diagonal branch more than 1 to 2 mm in

diameter, we perform a single bypass on the diagonal in order to revascularize the lateral wall of the left ventricle. If there are two important diagonal branches, both will be revascularized by a single or a double bypass (Fig. 5).

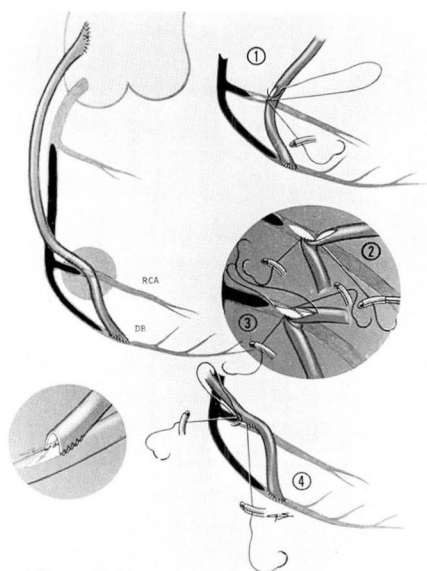


Fig. 4. Jump-graft on right coronary artery.

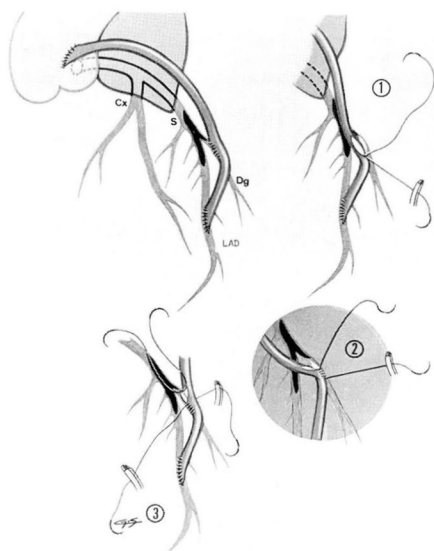


Fig. 5. Jump-graft on left anterior descending artery + diagonal.

If the left anterior descending artery is blocked at its origin and the lesions extend to the periphery, we perform an extensive endarterectomy to allow the opening of septal and diagonal branches. Sometimes it is possible to avoid such an endarterectomy by performing two arteriotomies, the first one proximally with a side-to-side anastomosis, the second one distally in the last third of the left anterior descending where the vessel is free from lesions (*Fig. 6*).

If the septal branch is stenosed, or a stenosis exists upstream or downstream from its origin, we believe that this vessel must be revascularized (*Fig. 7*).

Reconstruction of the circumflex artery. In the majority of cases, it is the marginal branch of the circumflex which is revascularized. The posterolateral branch can be directly revascularized, especially in its distal part. If lesions are very proximal, the marginal branch will be revascu-

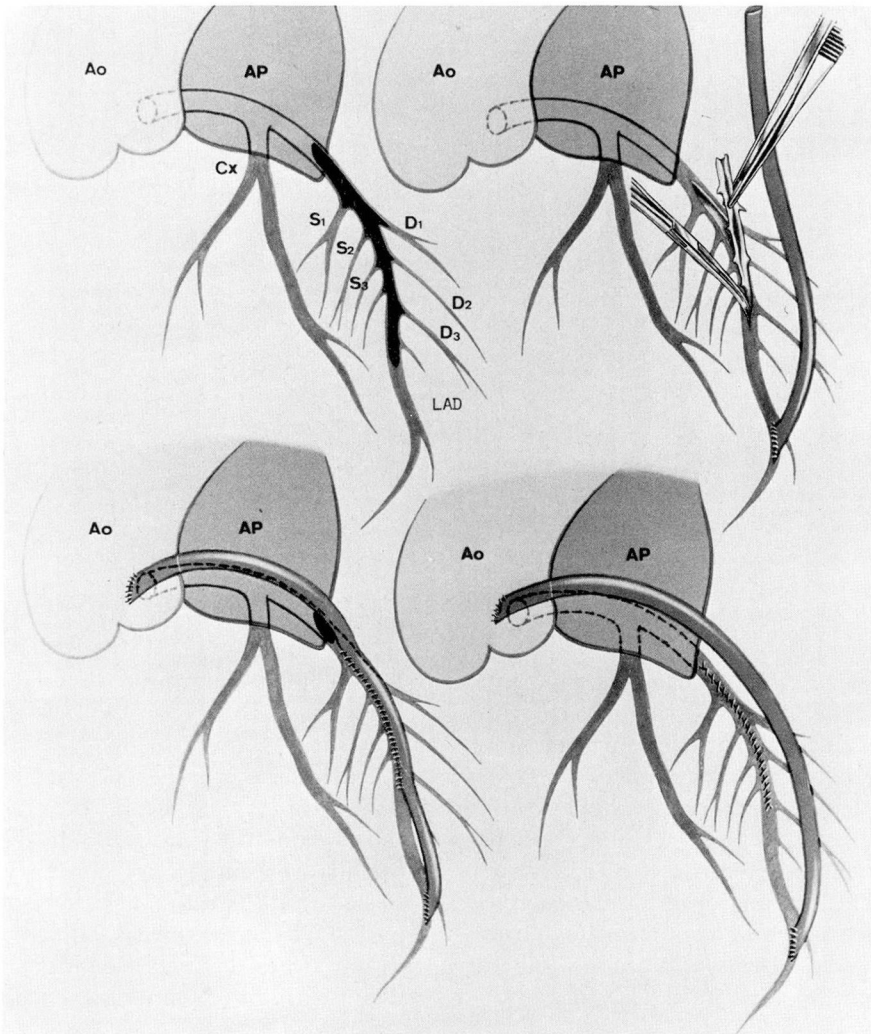


Fig. 6. Endarterectomy of left anterior descending artery.

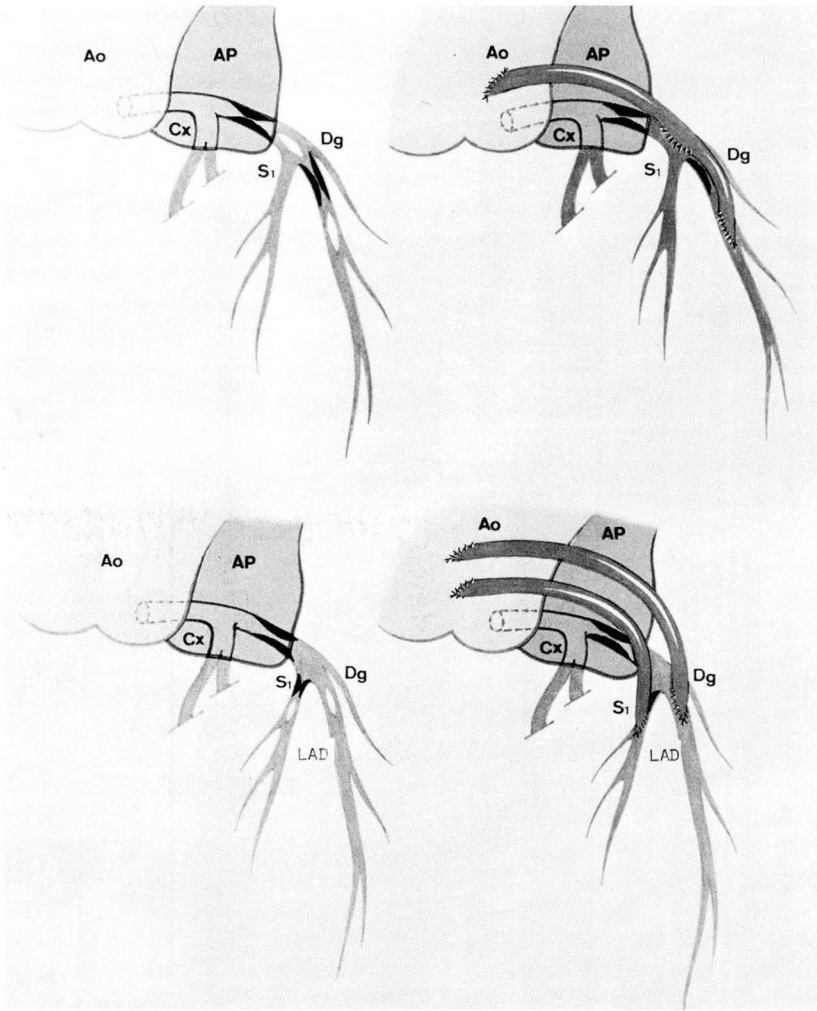


Fig. 7. Revascularization of the septal branch.

larized directly. If there are peripheral lesions, it is possible in very rare cases to perform an endarterectomy, especially if the circumflex artery is dominant. If the two branches of the circumflex artery are of a good diameter, we perform the reconstruction by way of a jump-graft with an end-to-side and a side-to-side anastomosis on the two branches of the circumflex artery.

Perspectives in coronary artery surgery

During the past decade, direct coronary surgery by means of a graft, most frequently venous, boldly developed from a single aortocoronary bypass (mostly a right one) to a more and more complete revascularization as our surgical experience increased. The future development of coronary

surgery is conditioned by the excellence of preoperative diagnosis by a more precise delimitation of myocardial regions still viable from regions completely destroyed. We are convinced that the dynamic cineventriculography with the nitroglycerine

test and the routine use of coronary angiography with gamma-cameras will enable us to give a better appreciation of patients, thus a better definition of the results that we shall obtain.