

Myocardial scintigraphy in coronary artery disease

Elias H. Botvinick, M.D.
David Shames, M.D.
William W. Parmley, M.D.
San Francisco, California

Advances in nuclear medicine physics and engineering technology have permitted the practical application of scintigraphic methods for the diagnosis and evaluation of cardiac disease. For the ambulatory patients with suspected or known coronary disease, there are now two new, valuable, noninvasive clinical tools.

Myocardial perfusion scintigraphy

Thallium-201 (Tl) is an intracellular cation which behaves much like potassium following its intravenous injection. Seventy-five to 80% of the radionuclide is extracted from the coronary circulation during the first pass, where it localizes in the myocardial cell in proportion to the relative coronary blood flow. Other determinants of Tl-201 distribution include the presence of scar and, likely, the integrity of the myocardial cell membrane. Myocardial regions which are relatively underperfused, scarred, or possess membrane abnormalities will demonstrate scintigraphic defects of "cold spots." Although coronary perfusion may remain relatively normal even through grossly stenotic vessels at rest, coronary vessels with significant stenoses cannot accommodate the increased

flow necessitated by the demands of stress. Injection of Tl-201 during graded treadmill exercise may, therefore, demonstrate a stress-induced heterogeneity of coronary flow resulting from the presence of a stenotic vessel among other patent or less diseased vessels. The demonstration of new stress-induced perfusion scintigram defects has proven to be both more sensitive and more specific for the diagnosis of ischemic heart disease than stress-induced electrocardiographic S-T segment depression. Further, the stress electrocardiogram is difficult to interpret in the setting of prior infarction, intraventricular conduction abnormalities, drug effect, electrolyte abnormalities, hyperventilation, or a multitude of other conditions. The stress scintigram appears to maintain its specificity even under these conditions (*Figure and Table*).

The perfusion scintigram cannot differentiate between transient ischemia, acute infarction, or remote infarction. However, a defect in the rest scintigram of an asymptomatic patient likely represents a region of prior scar, most commonly related to prior infarction. The rest scintigram appears more sensitive than the electrocardiogram for the diagnosis of both acute and remote infarction and appears extremely useful for infarct diagnosis early after the event. Additionally, both rest and stress perfusion abnormalities are important for their localizing value. The region of a perfusion abnormality can be correlated with a stenosis in the coronary vessel perfusing that region. The perfusion scintigram will likewise be of great use in objectively evaluating the results of coronary bypass graft surgery, and together with infarct

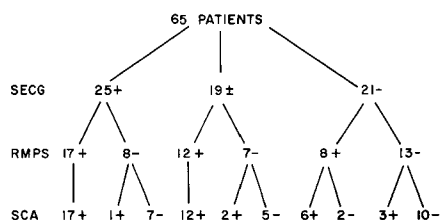


Figure. Shown are the overall results of stress electrocardiography (SECG), regional myocardial perfusion, scintigraphy (RMPS) with Thallium-201 and selective coronary angiography (SCA) in 65 patients. "+" denotes a positive study; "-" denotes a negative study, and "±" represents an equivocal study. A positive SECG study was defined as 1.0 mm of flat or downsloping S-T segment depression below the isoelectric baseline. RMPS was more accurate than SECG in identifying the presence of significant coronary artery disease. Additionally, RMPS clarified the equivocal SECG.

scintigraphy will aid infarct sizing and help differentiate regions of transient ischemia from acute and remote infarction.

Radioangiography

This technique allows visualization of the cardiac chambers throughout the cardiac cycle following the intravenous injection of a blood pool imaging agent. Following the intravenous injection of technetium (Tc)^{99m} pertechnetate bound to red cells in vivo, images of the cardiac silhouette may be obtained in orthogonal projections at end-systole and end-diastole. End-diastolic and end-systolic frames are chosen by their relationship to the patient's electrocardiogram and phonocardiogram, end-diastolic corresponding to the peak of the ECG R wave, and end-systolic corresponding to the patient's second heart sound. Gating the scintillation camera throughout the cardiac cycle using the electrocardiographic and phonocardiographic markers, we can

Table. Analysis of results

Sensitivity matrix		
SECG		
RMPS	TP	FN
TP	17	6
FN	1	3
Sensitivity – SECG – .67		
RMPS – .85		0.10 > p > 0.05
Specificity matrix		
SECG		
RMPS	TN	FP
TN	10	7
FP	2	0
Specificity – SECG – .63		
RMPS – .89		0.20 > p > 0.10
Accuracy matrix		
SECG		
RMPS	TP + TN	FP + FN
TP + TN	27	13
FP + FN	3	3
Accuracy – SECG – .65		
RMPS – .87		0.05 > p > 0.02

The results of the stress electrocardiogram (SECG) and the relative myocardial perfusion scintigram (RMPS) are compared and analyzed statistically. A true-positive test (TP) refers to an abnormal electrocardiographic or scintigraphic study performed in a patient with documented significant coronary lesions. A true-negative test (TN) refers to a normal electrocardiographic or scintigraphic study in a patient with documented normal or insignificantly narrowed coronary arteries. A false-positive test (FP) refers to an abnormal electrocardiographic or scintigraphic study in a patient with documented normal or insignificantly narrowed coronary arteries. A false-negative test (FN) refers to a normal electrocardiographic or scintigraphic study in a patient with documented significant coronary lesions. In evaluating our results, only the 46 patients with definitely positive or definitely negative stress electrocardiograms could be compared to the results of scintigraphy. Among this number those 27 patients with abnormal coronary angiograms are considered under the sensitivity matrix, while those 19 patients with “normal” coronary angiograms are considered under the specificity matrix. The accuracy matrix attempts to evaluate simultaneously sensitivity and specificity and is a compilation of the preceding two matrices. Results were analyzed by McNemar’s test (15) (see text).

obtain cumulative images of the cardiac chambers during ventricular end-diastole and end-systole. If we then outline the parameters of the left ventricle in each phase of the cardiac cycle in each projection and superimpose them manually or alternate images of end-diastole and end-systole, we can gain an accurate assessment of ventricular size, as well as global and segmental wall motion.

Using a standard source for linear calibration, we are able to calculate left ventricular ejection fraction, end-diastolic volume, end-systolic volume, and stroke volume by this method. In 20 randomly selected patients who had gated radioangiography in close temporal relation to invasive ventriculography, there was an excellent correlation between the two studies when analyzed for ejection

fraction, ventricular volume measurements, and segmental wall motion.

The gated radioangiogram is of great clinical utility for assessing ventricular size and function. The study delineates the relative size of the two ventricles, is ideal for the noninvasive identification of ventricular aneurysm, and can easily differentiate the patient with well localized segmental wall motion abnormalities from the patient with diffuse myocardial disease. This study is extremely useful for the sequential monitoring of ventricular size and function in patients and is a significant asset for the assessment of medical or surgical therapy. In the setting of acute infarction the gated radioangiogram aids the assessment of functional loss and may be performed at the bedside to monitor ventricular size and function in the critically ill patient.

If count information were obtained over the left ventricular cavity throughout the cardiac cycle and was then displayed as a time versus activity curve, we would noninvasively generate a ventricular volume curve, since counts are proportional to volume. Such ventricular volume curves can only be obtained presently following tedious, lengthy evaluation of the invasive ventriculogram. Here simple noninvasive evaluation will likely supply the diagnostic cardiologist with another valuable parameter of ventricular function.

The rapid computer acquisition of gated radioangiograms will make possible the assessment of ventricular size as well as global segmental function, both before and at the peak of maximal stress. Since the functional defect has been found both experimentally and clinically to be the abnormality most sensitive to the presence of ischemia, appearing before the onset of chest pain or S-T segment changes, evaluation of ventricular function and segmental wall motion at peak stress promises to provide a yet more sensitive diagnostic index for the presence, location, and functional threat of ischemic heart disease. In association with myocardial perfusion scintigraphy and infarct scintigraphy, the gated radioangiogram can assess the functional deficit and classify it into reversible ischemia and irreversible infarction. Such an accurate and discrete assessment of functional abnormalities will permit the choice of the optimal therapeutic regimen and allow for its continual bedside assessment.

Taken together, the two techniques described previously represent new and meaningful methods to diagnose coronary disease, its extent and its effects on the myocardium at all levels of clinical pathology. Their judicious application will lead to the most complete diagnostic evaluation of the coronary patient and help to optimize treatment for each individual.