

Pancreatic angiography

Thomas R. Havrilla, M.D.
Norbert E. Reich, D.O.
John R. Haaga, M.D.

Department of Radiology

Avram M. Cooperman,
M.D.

Department of General Surgery

Angiography has become an important procedure in the diagnosis of pancreatic disease. Because of the difficulty in examining the pancreas by the traditional roentgenographic techniques such as gastrointestinal barium examinations, hypotonic duodenography, and endoscopic retrograde pancreatography (ERCP), angiography serves as a complementary study. Perhaps the chief attribute is its role in diagnosing pancreatic tumors. The angiogram can aid in showing the extent of a tumor, its resectability, and vascular variations which may complicate the surgical procedure. It is the procedure of choice for diagnosing and locating islet cell adenomas because they frequently are small and difficult to find on exploration. With accurate localization, only limited resection of the pancreas is needed and operative mortality and morbidity are reduced.¹ Pancreatitis is more of a clinical diagnosis than an angiographic one. However, it must be differentiated from pancreatic carcinoma. Angiography is also an aid in the diagnosis of cystadenomas and cystadenocarcinomas, other rare endocrine tumors, metastatic disease, and lymphomas. Occasionally, it is an aid in the diagnosis of trauma and congenital vascular abnormalities.

Technique

Since the first selective celiac and superior mesenteric angiograms performed by arteriotomy of the carotid or brachial arteries in 1951,² angiographic technique has been perfected to almost a fine art. Today, pancreatic angiography is usually performed by a percutaneous femoral approach utilizing the Seldinger technique, first performed in 1953.³ If the femoral arteries cannot be utilized secondary to severe atherosclerotic disease, axillary catheterization is a good alternative.^{4,5} Usually celiac and superior mesenteric angiography should be performed either as a combined injection using two catheters from each femoral artery or by sequential injections using one catheter only. Sequential injections help separate many of the pancreatic vessels from overlying celiac and mesenteric artery branches on the combined injections. Combined injections can aid in gross pancreatic diagnoses, in showing the vascular anatomy, and possibly demonstrating liver metastases. At present double catheter techniques are not widely used.^{6,7}

Selective superior mesenteric angiography usually is performed with 40- to 60-ml Renografin 76 delivered with a pressure injector at a rate of 7 to 12 ml/sec for 7 seconds. Serial filming is necessary at one to two exposures per second for 7 seconds with a total filming time of 18 to 30 seconds. A satisfactory program consists of 7 ml/sec for 7 seconds with one exposure per second for 7 seconds and then one exposure per 3 seconds for the next 21 seconds. Usually this results in excellent visualization of both arterial and venous systems and can demonstrate prolonged

arterial blush, for example, in various pancreatic lesions as well as collateral circulation when vascular occlusions are present. Magnification techniques are rarely used. Film subtraction techniques are not of great benefit but can occasionally demonstrate small areas of tumor blush or neovascularity. Therefore, subtraction techniques are used only in selected patients to enhance a questionable abnormality.

Superselective injection of individual pancreatic arteries is done routinely by many investigators if a lesion is suspected on the initial celiac or mesenteric arteriogram or if there is strong clinical evidence of pancreatic abnormality.^{5,8,9} Superselective studies are usually performed by advancing a catheter into the gastroduodenal artery or into a pancreatic branch of the splenic artery. If a standard catheter cannot be advanced, a catheter shaped to conform to the vascular anatomy is used; remotely controlled guide wires and catheters have also been developed.⁹ Injections can be made by hand or by large bolus injections delivered with a pressure injector to visualize small capillaries, pancreatic parenchyma, and the venous system.¹⁰

Injections into the gastroduodenal, dorsal pancreatic and splenic arteries have four advantages.¹ (1) The pancreatic arteries are filled with higher concentration solution. (2) Overlying left gastric and jejunal artery branches are not a problem. (3) Injection into the gastroduodenal artery distends the pancreatoduodenal arcade branches. Therefore, fixed, nondistensible irregularities in the lumen are more easily seen. (4) Excellent filling of the splenic and portal veins can be attained for visualization of

venous narrowing and occlusion. Subtle changes in the pancreatoduodenal arcades are often the only clue in the diagnosis of tumor.

The pancreatic arteries are usually well demonstrated by injecting the splenic and gastroduodenal arteries. The anastomosing branches of the pancreatic arcades of the dorsal pancreatic artery allow evaluation of the head and body of the pancreas. Injection of the splenic artery will visualize the branches to the distal tail. The splenic vein is also well visualized. Injection of the dorsal pancreatic artery, because of wide anastomoses throughout the pancreas, will demonstrate the branches in the head and body. In superselective catheterization, the injection volume should be kept to a minimum and care should be taken to avoid wedging of the catheter.

Pharmacangiography has also been adapted for evaluating pancreatic abnormalities. Some pharmaceuticals enhance the visualization of certain vessels in selective and superselective angiography. Two basic categories are vasoconstrictive and vasodilating drugs.¹¹ Vasoconstrictors consist of epinephrine, norepinephrine, vasopressin, and angiotensin.¹² Small doses of epinephrine (5 to 10 μ g) given intraarterially will constrict the entire splenic bed, but in different degrees. Since pancreatic vessels react the least to epinephrine, shunting occurs from the gastric, hepatic, and splenic beds into the pancreatic vascular bed on the celiac angiogram. Small tumor vessels in pancreatic carcinoma and abnormal vessels in pancreatitis are often displayed to better advantage. This is secondary to the relative increase in pancreatic flow and also because neovascularity char-

acteristically does not react to a vasoconstrictor.¹³⁻¹⁵

Bradykinin is a potent arterial dilator and gives earlier and better filling of veins. Tolazoline (Priscoline) can also enhance the venous phase in dosages of approximately 25 mg. Secretin, trypsin, and histamine have been used to improve the parenchymal phases of the pancreatic angiogram.¹⁶ Tolazoline and prostaglandin E have also been investigated.^{17, 18}

The complications of percutaneous femoral angiography are few and directly related to the experience and expertise of the angiographer. The number of catheter changes, the total time of the procedure, and the presence of arterial disease are also related factors.¹¹ The incidence of minor complications is below 3%; major complications occur in less than 0.5% of patients. Complications which can occur are bleeding and femoral arterial thrombosis at the site of catheter introduction, hematoma, arterial venous fistula, and embolization secondary to formation of thrombi at the puncture site. Complications rarely include thrombophlebitis of the lower extremity, dissection of the aorta or its branches, vascular perforation, and parenchymal infarction secondary to wedging of the catheter. A rare complication is permanent paralysis secondary to transverse myelitis. Breakage of catheters and guide wires intravascularly may also occur. Abdominal pain may occur at the time of injection but usually lasts only a few moments.¹⁹

Normal vascular anatomy

The arterial supply to the pancreas originates from the celiac and superior mesenteric arteries. The arterial supply varies²⁰ and selective angiog-

raphy is usually necessary for evaluation of the intrapancreatic arteries. With the aid of superselective gastroduodenal and splenic angiograms, the entire pancreatic circulation can be demonstrated. The celiac artery divides into three major branches (*Fig. 1*) in approximately 60% of patients: left gastric, splenic, and common hepatic arteries.¹ Occasionally the dorsal pancreatic artery arises from the celiac artery. The dorsal pancreatic artery arises from the proximal aspect of the splenic artery in about 40% of patients. This feeds the dorsal surface of the pancreas and uncinate process. The transverse pancreatic artery arises from the dorsal artery and supplies blood to the tail of the pancreas. The pancreatic magna artery extends from the distal third of the splenic artery and supplies the tail of the pancreas. Many

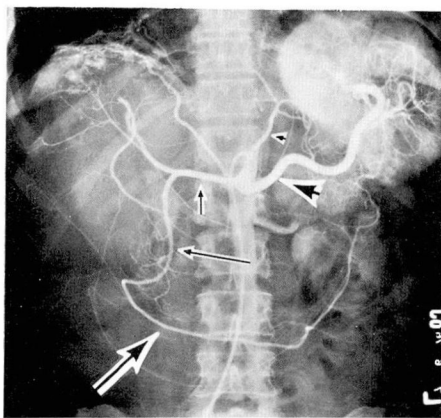


Fig. 1. Normal celiac trunk. The hepatic (short small arrow), splenic (large arrow head) and left gastric (small arrow head) arteries are demonstrated originating from the celiac trunk. The gastroduodenal artery (small arrow) is a branch of the common hepatic artery. The right gastroepiploic artery (large arrow) supplies the greater curvature of the stomach. Increased subdiaphragmatic vascularity is secondary to an incidental echinococcal cyst in the dome of the right lobe of the liver with calcifications.

small pancreatic arteries also arise from the splenic artery throughout its course. Rich anastomotic branches extend to the anterior or posterior pancreaticoduodenal arcade.

The gastroduodenal artery is the first major branch of the hepatic artery and extends inferiorly behind the first portion of the duodenum (*Fig. 2*). Its first branch is the posterior superior pancreaticoduodenal artery. This artery courses next to the common duct and over the dorsal aspect of the head of the pancreas. It forms a portion of the posterior arcade. The second branch of the gastroduodenal artery is the anterior superior pancreaticoduodenal artery. This artery passes along the anterior aspect of the pancreatic head supplying the head and forming the anterior pancreatic arcade.

The common hepatic artery arises from the celiac trunk in approximately 50% of patients. The right hepatic artery has its origin from the superior mesenteric artery in 8% to 14% of persons.¹

The inferior pancreaticoduodenal artery arises from the superior mesenteric artery proximally and aids in forming the inferior portion of the anterior and posterior arcades. Normal pancreatic parenchyma has a patchy, lobulated pattern. The intrapancreatic veins have the same distribution as the arteries and drain into the portal, superior mesenteric, and splenic veins.

The anatomy of the venous system varies, but knowledge of the venous system and drainage patterns is important for thorough angiographic investigation. Veins of the gastrointestinal tract drain into the portal system. The superior mesenteric vein and splenic vein join to form the

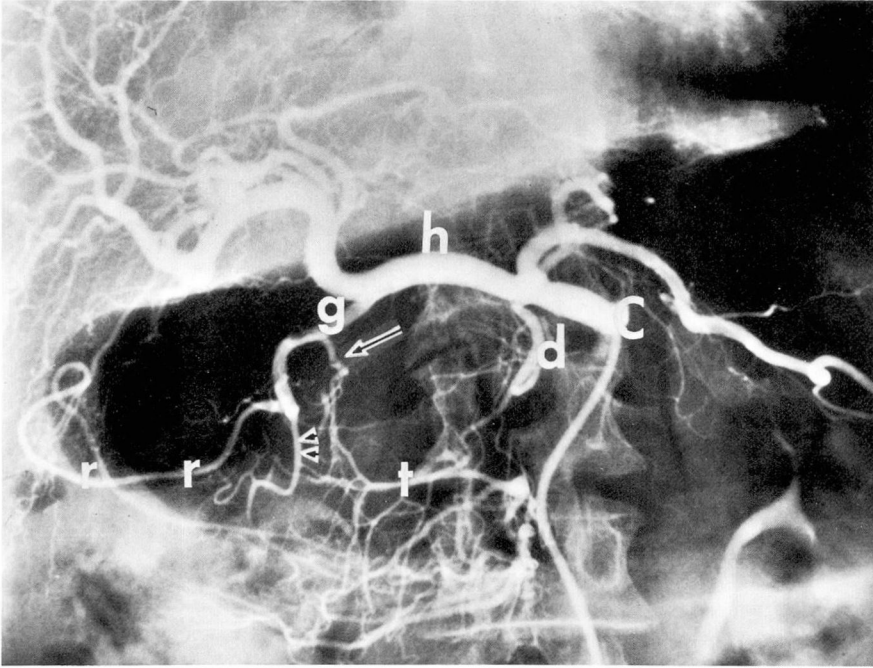


Fig. 2. Gastroduodenal artery. Celiac angiogram. The gastroduodenal artery (g) originates from the hepatic artery (h). The posterior superior pancreaticoduodenal artery (arrow) arises 2 cm from the origin of the gastroduodenal artery. It anastomoses with the transverse pancreatic artery (t) which in turn arises from the dorsal pancreatic artery (d) originating from the celiac trunk (C). The anterior superior pancreaticoduodenal artery (arrow heads) is one of the terminal branches of the gastroduodenal artery which anastomoses with the inferior pancreaticoduodenal arteries and the superior mesenteric artery. The other terminal branch of the gastroduodenal artery is the right gastroepiploic artery (r). Overlying gas is present in the stomach.

portal vein. The portal vein then enters the liver hilum and usually divides into right and left branches which empty toward the periphery of the liver (*Fig. 3*). The portal veins are therefore oriented toward the liver hilum. The portal venous system can have potential collateral anastomoses to the systemic venous system.¹ The veins of Retzius form a retroperitoneal plexus between the colic, splenic, duodenal, and pancreatic veins and the inferior vena cava via the phrenic and azygous veins. Collateral pathways also are present between the gastric and splenic veins, left renal veins, and inferior phrenic veins.

Angiographic evaluation of pancreatic disease

Goldstein et al²¹ in 1974 defined the angiographic criteria needed for evaluating the pancreatic disease and providing an accurate diagnosis. The criteria are as follows: (1) arterial encasement as evidenced by irregular or smooth narrowing of a vessel (*Fig. 4*); (2) arterial occlusion; (3) tortuosity or sharp angulations of intrapancreatic arteries without narrowing; (4) beaded arteries suggesting localized dilatations along the course of an artery; (5) displacement indicating enlargement of the pancreas or a portion thereof (*Fig. 5*); (6) increased

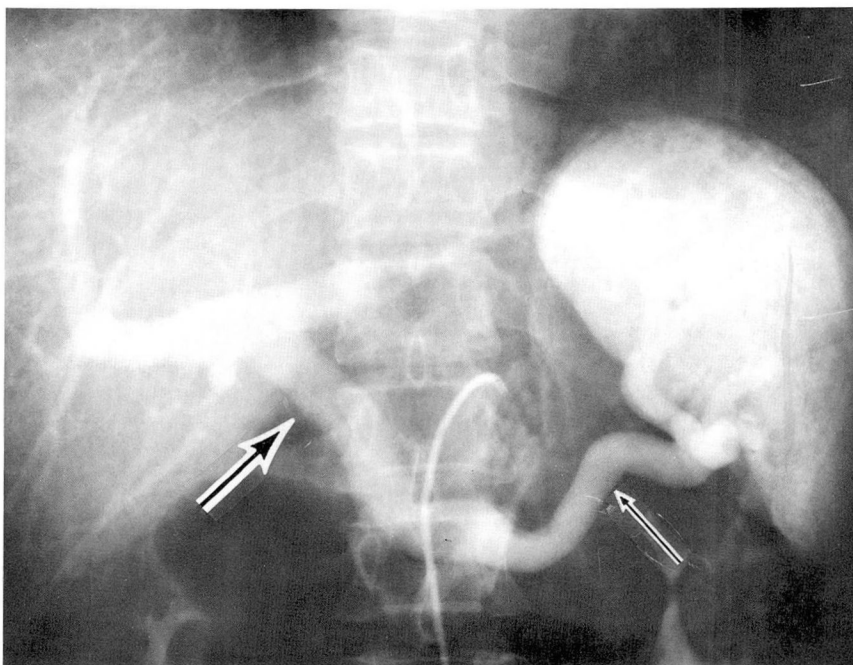


Fig. 3. Portal venous system. Venous phase, celiac angiogram. The splenic (small arrow) and portal veins (large arrow) are well demonstrated including the distal hepatic portal branches.

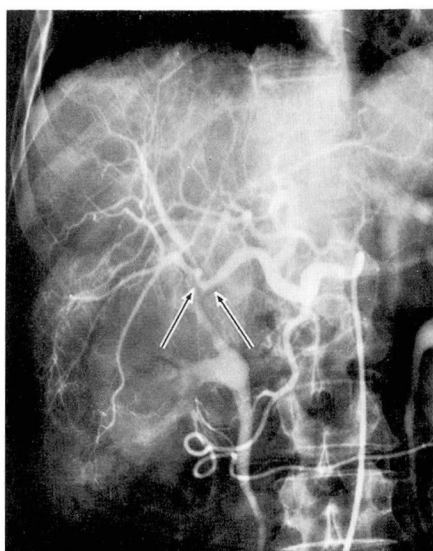


Fig. 4. Selective hepatic arteriogram. Smooth encasement of the distal right hepatic artery and proximal intrahepatic branches (arrows) in a patient with invasive mucinous adenocarcinoma of the pancreas involving the liver and porta hepatis.

vascularity, decreased vascularity, neovascularity, or abnormal pancreatic stain; (7) compression, displacement, or occlusion of splenic, portal or superior mesenteric veins; (8) distention of the gallbladder; and (9) signs of hepatic metastases. These criteria are defined in the several specific disease entities.

Pancreatic carcinoma

According to some investigators, angiographic abnormalities can be identified in all symptomatic patients with pancreatic carcinoma.²¹ Pancreatic adenocarcinoma is usually a scirrhous infiltrating tumor and is poorly vascularized. The main angiographic finding is encasement of the arteries about the pancreas (*Fig. 6*). Reuter and Redman¹ described two types of arterial encasement depending on the size of the vessel. In a

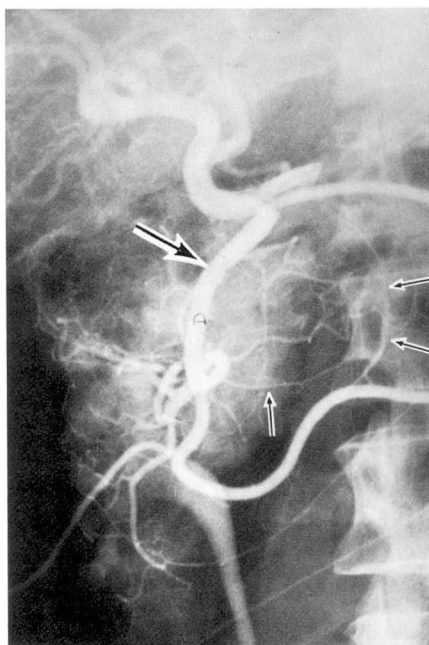


Fig. 5. Selective gastroduodenal arteriogram. Symmetrical displacement of several branches (small arrows) of the gastroduodenal artery (large arrow) secondary to pancreatic carcinoma in the head of the pancreas. The intense blush is within the duodenum and normal variation.

large vessel, for example, the splenic or hepatic artery, the encased vessel will have a saw-tooth margin with a serrated appearance. Small vessels such as an intrapancreatic branch often have abrupt angulations in the course and caliber, termed serpiginous encasement. Smooth encasement of an artery, however, is a non-specific sign and can be seen in atherosclerotic disease. If smooth encasement is present, other signs of neoplasm must also be present on angiograms for valid diagnosis. Reuter and Redman also state that tumor vessels can be seen in approximately 60% of carcinomas of the pancreas. They believe that the ability to demonstrate these vessels is directly proportional to the quality of the roent-

genographic examination. Superselective angiography is also a great benefit. Another major sign of carcinoma is venous invasion (*Fig. 7A and B*). Carcinomas in the head of the pancreas will often distort or block the superior mesenteric vein or the splenic vein in the region of the tail of the pancreas. Also for better visualization of the superior mesenteric and splenic veins, a large injection of contrast medium is made into the splenic or superior mesenteric arteries.

Less reliable signs of carcinoma are arterial displacement, parenchymal blush, and early venous drainage. Neovascularity can occur and some authors believe that small vessel changes are the most common abnormal findings in pancreatic carcinoma.¹¹ These small vessel changes usually are of deformed abnormal tortuous vessels which vary in caliber. Often they are only seen in the periphery of a tumor and may require superselective techniques and magnification for visualization. The incidence of venous involvement ranges from 40% to 98%.^{22, 23}

Differential diagnosis of pancreatic carcinoma

Differentiation between pancreatitis and carcinoma can be made in up to 85% of cases.²¹ Arterial encasement alone or venous abnormality alone are often suggestive of pancreatitis, whereas encasement plus venous abnormalities more often imply carcinoma. Neovascularity is a prominent feature of carcinoma. Arterial tortuosity and angulations without narrowing are more characteristic of pancreatitis. Arterial displacement with vascular or parenchymal enhancement and early venous

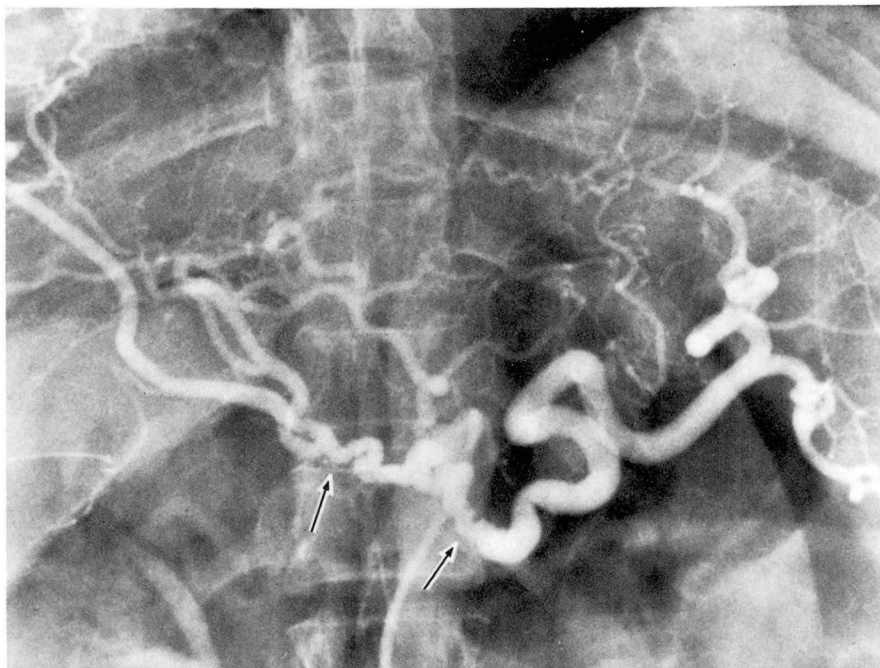


Fig. 6. Celiac arteriogram depicting encasement of the proximal splenic and common hepatic arteries (arrows). The encasement is of the serrated type.

drainage are all signs of pancreatitis. Hypervascularity and alternating dilations and stenoses in pancreatic arteries are also characteristic of pancreatitis. Pancreatitis is usually more diffuse than carcinoma.

In an elderly population, atherosclerotic changes can be a problem. Atherosclerotic disease usually consists of smooth, short stenoses of major arteries with complete or partial occlusion. The stenoses usually are within the proximal 1 cm of the major take-off of the artery. The veins are always normal in atherosclerosis. If smooth encasement is present, tumor vessels or venous invasion must also be present before a diagnosis of pancreatic carcinoma can be made.¹ Arterial and venous changes in different regions of the pancreas indicate pancreatitis; localized stenoses and occlusions indicate carcinoma.

The pancreatogram phase of carcinoma usually is decreased in comparison with the increased phase in pancreatitis.

Peripancreatic malignant lymphomas can mimic the clinical features of primary pancreatic disease.²⁴ Usually, these lymphomas appear as a large hypovascular mass with displacement of pancreatic and peripancreatic arteries and compression of adjacent veins. Smooth arterial encasement can occur. Signs of mass out of proportion to signs of invasion mitigate against the diagnosis of carcinoma.

Pancreatography²⁵ or retrograde pancreatic cholangiography²⁶ are complementary procedures which can aid in outlining the internal architecture of the pancreatic gland and ductal system. Percutaneous antecubital transvenous cholangiogra-

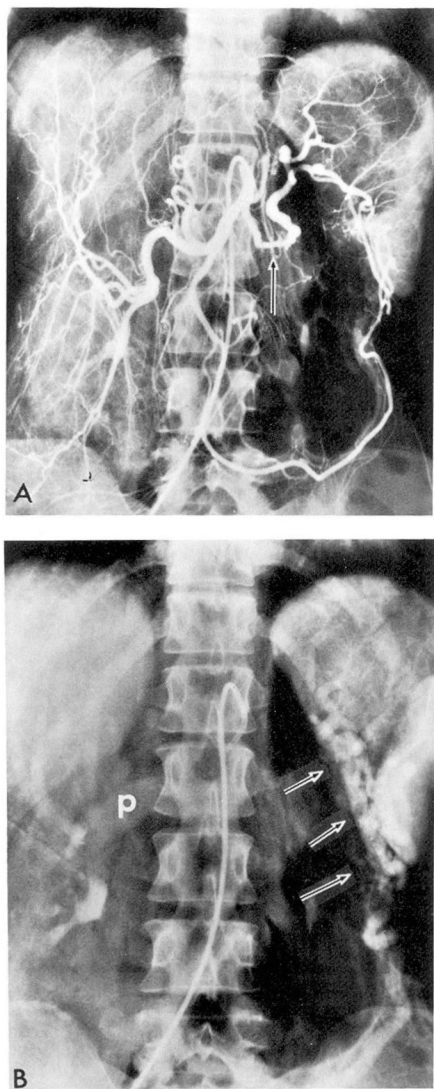


Fig. 7. A, Celiac arteriogram. Smooth encasement of the proximal splenic artery is depicted (arrow). Hepatomegaly is also present with straightening of intrahepatic arteries. B, On the venous phase, the splenic vein is not visualized and completely occluded with visualization of the portal vein (p) filling retrograde from splenic and mesenteric varices (arrows). Pathologic diagnosis: carcinoma, body and tail of the pancreas.

phy²⁷ and retrograde pancreatic venography⁹ may also aid in diagnosis in the future.

Endocrine tumors

Adenomas of the islands of Langerhans fall into several groups. The insulinoma is composed of beta cells and causes hyperinsulinism; the Zollinger-Ellison adenoma is a nonbeta-cell tumor causing overproduction of gastrin.¹ Another nonbeta-cell tumor can produce severe diarrhea and hypokalemia and an alpha-cell tumor can produce hyperglucanemia and diabetes. Some islet cell adenomas are nonfunctioning.²⁸ The overall success rate in finding these adenomas is approximately 60%;¹ surgical success in removing these tumors blindly is 50%.²⁹ Most of these tumors have a homogeneous blush and a prolonged capillary stain. Insulinomas are usually found in the body and tail of the pancreas but may be multiple. Usually they are smaller than nonbeta islet cell tumors. Some irregular vessels may occasionally be seen within the tumor. Often, a benign and malignant adenoma cannot be differentiated by angiography.

In small lesions, the main angiographic finding is a well-circumscribed area of increased contrast in the capillary and venous phases. The number of tumor vessels is proportional to the size of the tumor. Because of the subtleness in angiographic findings, superselective techniques may be necessary for assistance in diagnosis. A false-positive study can occur if a localized area of increased vascularity near the junction of the body and tail of the pancreas in normal patients is not recognized. This finding is most likely secondary to prominence of a pancreatic magna or dorsal pancreatic artery.¹ Malignancy should be suspected when tumors are more than 5 cm in diameter (Fig. 8A). Metastases are

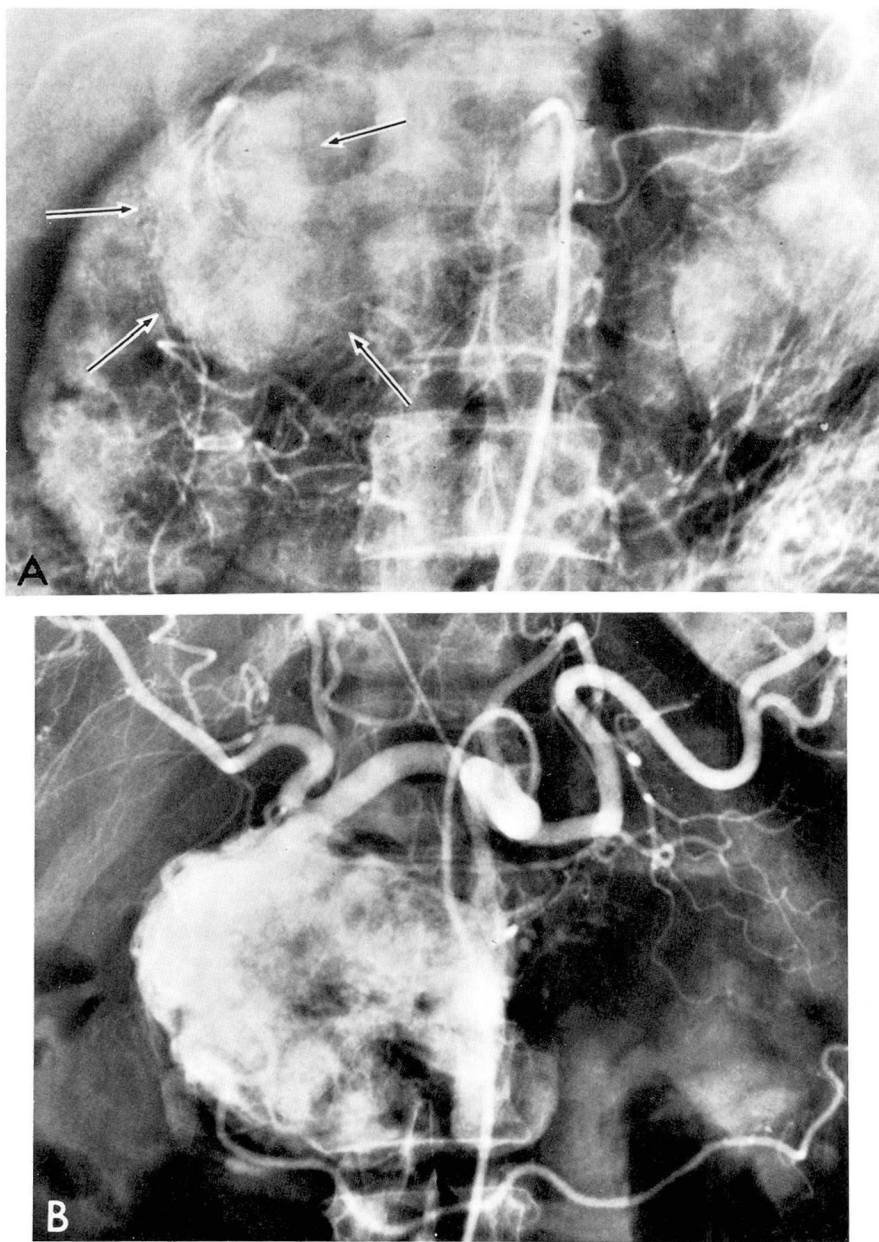


Fig. 8. *A*, Venous phase, celiac arteriogram. Intense, large venous blush is present (arrows) overlying the upper pole, right kidney. Diagnosis at laparotomy and pathologic diagnosis: islet cell carcinoma. *B*, Nonfunctioning benign islet cell tumor. Celiac arteriogram. Dense capillary staining is noted on the arterial phase of this very large pancreatic tumor. (Published with permission of Bagheri S et al, *Radiology* 120: 57-59, 1976.

usually demonstrated in the liver and are hypervascular.

Nonfunctioning tumors usually do not have endocrine or other specific

clinical findings.²⁸ Mainly, nonfunctioning islet cell tumors are large because of the lack of clinical findings in the early stages of tumor growth.

Clinical diagnoses are usually made after a palpable mass is noted or an adjacent organ is obstructed. All cases of nonfunctioning islet cell tumors show severe hypervascularity with dense capillary stains (*Fig. 8B*). A pathologic condition of the vessels can occur with early venous filling.^{28, 30} Vascular displacement is common.

Insulinomas cause hyperinsulinism with bouts of hypoglycemic shock. They are the most frequent type of islet cell tumors (75%).³¹ Only 5% of the tumors do not secrete hormones. Beta-cell tumors show signs of hyperinsulinism with hypoglycemia, migraine, and psychosis, and can mimic conditions found in alcoholism, brain tumors, and hyperthyroidism. Gastrin-producing tumors give rise to hyperacidity with recurrent ulcerations.

Cystadenoma

Cystadenomas usually are lobulated pancreatic tumors, well-encapsulated with many cystic spaces; they grow slowly. On angiography, they are usually highly vascular and large. Multiple fine tumor vessels are seen throughout the lesion on the arterial phase with a prolonged capillary stain.^{32, 33} Multiple avascular cystic areas are present within the zones of hypervascularity. Arterial venous shunting and tortuous veins can occur with displacement of adjacent vessels because of the large size of the tumor. With the malignant forms, irregular and truncated vessels are seen. Differentiation between benign and malignant cystadenomas cannot always be made by angiography. Malignancy can be suspected if the lesions are large or if peripancreatic invasion and hepatic metastases occur.¹

Pancreatitis

Pancreatitis is an important differential diagnosis in pancreatic carcinoma. The angiographic abnormalities are related to the chronicity of the disease,³⁴ and the variable findings often depend on the stages of the disease. Acute or mild pancreatitis does not have significant abnormalities by angiography. Patients with hemorrhagic pancreatitis and pancreatic necrosis can have normal angiograms. With acute pancreatitis, there may be minor alterations in the size and shape of the pancreas with mild widening or stretching of the pancreatic arcades. Associated hypervascularity may be present. As the disease progresses, nonspecific, mild arterial irregularities of the intrapancreatic branches can be seen. Hypervascularity is again prominent and occasionally arterial venous shunting occurs. With chronic pancreatitis, the arteries assume a beaded appearance. Smooth narrowing of the splenic artery often occurs. The course of the arteries remains unchanged. Abrupt angulations and distortions of the arteries also may be present. In the capillary phases, the pancreatic parenchyma is nonhomogeneous. The splenic and mesenteric veins can be involved with either irregular lumens or occlusion. Aneurysms of the intrapancreatic vessels may occur.

Pancreatic pseudocysts are secondary to chronic pancreatitis or previous trauma. The main angiographic finding is arterial stretching or displacement with sharp pancreatic parenchymal margins (*Fig. 9*). Very large cysts occlude the splenic vein and even erode into arteries causing hemorrhage into the cyst. Smaller pseudocysts resemble intra-

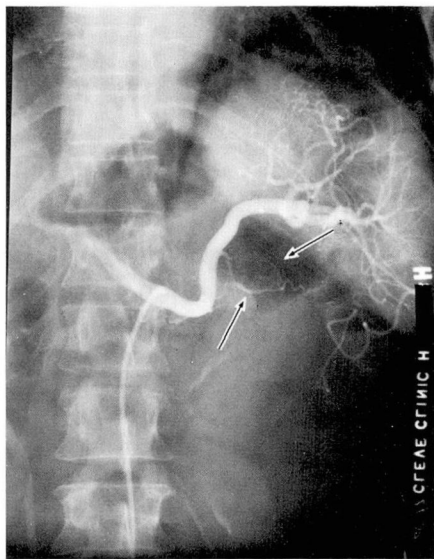


Fig. 9. Selective splenic arteriogram shows smooth displacement of the dorsal pancreatic artery and its branches (arrows) in a patient with a history of chronic alcoholism and chronic pancreatitis. Diagnosis at laparotomy and pathologic diagnosis: pseudocyst, tail of the pancreas.

pancreatic aneurysms. Usually, pancreatic pseudocysts are easily diagnosed by angiography, although occasionally a large cystadenoma mimics a pseudocyst.

Trauma

Trauma is very rare with a frequency of 0.5% to 5.4%.³⁵ Pancreatic injury is frequently associated with multiple, severe organ injuries and laparotomy is usually performed without angiography. Complications that may occur from trauma are complete transection, traumatic pseudocyst, hematoma, and pancreatitis. Angiographic findings may include arterial occlusion secondary to vascular laceration, displacement of adjacent arteries by hematoma and edema, and portal vein obstruction. But even in complete pancreatic tran-

section, angiographic findings are subtle.³⁶ Therefore, the role of pancreatic angiography in trauma has been minor.

Pancreatic vascular disease

Congenital abnormalities of the pancreas are rare. Grannis et al³⁷ reported a case of arteriovenous fistula of the pancreas and duodenum secondary to an arteriovenous malformation. In this rare lesion, angiography provided accurate delineation of the lesion allowing proper surgical treatment with pancreatoduodenal resection. Usually, arteriovenous malformations are managed by total or partial excision of the organs involved in order to control the vascular malformation and associated intestinal bleeding.

Harris et al³⁸ have described several cases of aneurysms of the small pancreatic arteries causing upper abdominal pain and intestinal bleeding. A high mortality rate is associated with rupture of these aneurysms which can occur in patients with pancreatitis or pancreatic pseudocysts. Often the preoperative diagnosis can be made by selective arteriography.

Another major factor in the formation of aneurysms is atherosclerotic disease. These aneurysms occur in long-standing celiac artery stenosis or stenosis of the superior mesenteric artery. Possibly, chronic increased blood flow in the pancreatoduodenal arcade weakens the arterial walls and accounts for the acute or chronic blood loss secondary to vessel dilatation and tortuosity with aneurysm formation. Rarely, aneurysms are found associated with pancreatic carcinoma, retroperitoneal tumor, penetrating duodenal ulcer, surgery and trauma.

Discussion

Although the technique of angiographic diagnosis of pancreatic carcinoma has been perfected, the prognosis in carcinoma is still poor. Five-year survival is approximately 1% to 2%. Frequently when a tumor is diagnosed by angiography, the lesion is unresectable, that is, the tumor has broken out of the confines of the pancreatic organ. Angiography can aid in the management of pancreatic carcinoma and once the diagnosis is established, it can alleviate the further need for clinical or surgical investigations. Also benign diseases can be differentiated. The normal vascular anatomic variants to the pancreas and liver can be detected prior to surgery and can be an invaluable aid to the surgeon. A prediction of resectability can be made.²¹ If one or two intrapancreatic arteries are invaded, a direct correlation with resectability and survival in tumors of the head of the pancreas can be made according to Suzuki et al.^{39, 40} In Suzuki's series, 11 of 53 cases were considered resectable. In Goldstein's series, nonresectability was predicted in 25 of 29 lesions.²¹

Although initially it was hoped that angiography would diagnose pancreatic carcinoma in an early stage, this has not proved to be the case. Accuracy of a prospective diagnosis of carcinoma by angiography increases with superselective technique. The presence of two or more signs of malignancy improves diagnostic accuracy.¹¹

In conclusion, pancreatic angiography has not affected the prognosis of pancreatic carcinoma, although it has aided in earlier diagnosis in differentiation among benign entities. In patients suspected of having car-

cinoma, angiography is highly accurate depending upon the experience of the angiographer and the radiologic technique used. Resectability, and the surgical and therapeutic approach to treatment can be determined. Since endocrine tumors are usually vascular, angiography is an ideal method for localizing these lesions, which can be detected in over 50% of patients.

References

1. Reuter SR, Redman HC: Gastrointestinal Angiography. Philadelphia, WB Saunders Co, 1972.
2. Bierman HR, Miller ER, Byron RL Jr, et al: Intra-arterial catheterization of viscera in man. *Am J Roentgenol* **66**: 555-568, 1951.
3. Seldinger SI: Catheter replacement of the needle in percutaneous arteriography; a new technique. *Acta Radiol* **39**: 368-376, 1953.
4. Beachley MC, Ranniger K: Abdominal aortography from the axillary approach. *Am J Roentgenol* **119**: 508-511, 1973.
5. Boijesen E: Selective visceral angiography using a percutaneous axillary technique. *Br J Radiol* **39**: 414-421, 1966.
6. Bedacht R, Zimmermann H: Angiographie zur präoperativen Pankreasdiagnostik. *Bruns Beitr Klin Chir* **215**: 257-274, 1967.
7. Lunderquist A: Angiography in carcinoma of the pancreas. *Acta Radiol (Suppl)* **235**, 1965.
8. Boijesen E, Samuelsson L: Angiographic diagnosis of tumors arising from the pancreatic islets. *Acta Radiol (Diag)* (Stockh) **10**: 161-176, 1970.
9. Rösch J, Grollman JH Jr: Superselective arteriography in the diagnosis of abdominal pathology; technical considerations. *Radiology* **92**: 1008-1013, 1969.
10. Eisenberg H: Angiography of the pancreas, in *Small Vessel Angiography*. Hilal S, ed. St. Louis, CV Mosby Co, 1973.
11. Ranniger K, Beachley MC: Pancreatic angiography, *Curr Probl Radiol*. Chicago, Year Book Medical Publishers Inc, July-August 1974.
12. Kaplan JH, Bookstein JJ: Abdominal visceral pharminoangiography with angi-

- otensin. *Radiology* **103**: 79-83, 1972.
13. Cen VM, Rosenbusch G: Zöliakographie mit Adrenalin (Möglichkeiten der Pharmakoangiographie in der Pankreasdiagnostik). *Fortschr Roentgenstr* **111**: 82-92, 1969.
 14. Steckel RJ, Ross G, Grollman JH Jr: A potent drug combination for producing constriction of the superior mesenteric artery and its branches. *Radiology* **91**: 579-581, 1968.
 15. Wehling H: Zur Frühdiagnose von Pankreastumoren; Untersuchungen zur angiographischen Darstellung des Pankreas unter Verwendung vasoaktiver Stoffe. *Fortschr Med* **89**: 1008-1011, 1971.
 16. Schmarsow R: Angiography of the pancreas following the administration of secretin, trypsin and histamine. *Acta Radiol (Diag)* **12**: 175-183, 1972.
 17. Hawkins IF, Kaude JV, MacGregor A: Priscoline and epinephrine in selective pancreatic angiography: a comparison study using high pressure injection, valsalva maneuver and geometric magnification. *Radiology* **116**: 311-321, 1975.
 18. Davis LJ, Anderson JH, Wallace S, et al: The use of prostaglandin E₁ to enhance the angiographic visualization of the splanchnic circulation. *Radiology* **114**: 281-286, 1975.
 19. Meaney TF: Complications of percutaneous femoral angiography. *Geriatrics* **29**: 61-64, April 1974.
 20. Michels NA: Blood Supply and Anatomy of the Upper Abdominal Organs with a Descriptive Atlas. Philadelphia, JB Lippincott Co, 1955.
 21. Goldstein HM, Neiman HL, Bookstein JJ: Angiographic evaluation of pancreatic disease; a further appraisal. *Radiology* **112**: 275-282, 1974.
 22. Rosch J, Herfort K: Splenoportographic diagnosis of pancreatic diseases. *Geriatrics* **19**: 725-734, 1964.
 23. Buranasiri S, Baum S: The significance of the venous phase of celiac and superior mesenteric arteriography in evaluating pancreatic carcinoma. *Radiology* **102**: 11-20, 1972.
 24. Neiman HL, Goldstein HM, Silverman PJ, et al: Angiographic features of peripancreatic malignant lymphoma. *Radiology* **115**: 589-592, 1975.
 25. Clouse ME, Gregg JA, Sedgwick CE: Angiography vs pancreatography in diagnosis of carcinoma of the pancreas. *Radiology* **114**: 605-610, 1975.
 26. Triller J, Voegeli E, Halter F, et al: Die Selektive Pankreas-Angiographie und retrograde Pankreas-Cholangiographie als Kombinationsuntersuchung. *Fortschr Geb Roentgenstr Nuklearmed* **122**: 138-144, 1975.
 27. Hawkins IF Jr, McNeely GF, Weaver DL Jr: Percutaneous antecubital transvenous cholangiography; a modified technique using a flexible needle. *Radiology* **120**: 423-425, 1976.
 28. Bagheri S, Alfidi RJ, Zelch MG: Angiography of nonfunctioning islet cell tumors of the pancreas. *Radiology* **120**: 57-59, 1976.
 29. Wolfe WG, Mullen DC, Silver D: Insulinoma of the pancreas; use of the tolbutamide test, arteriography, and selenium scan in modern diagnosis. *Arch Surg* **104**: 56-59, 1972.
 30. Deutsch V, Adar R, Jacob ET, et al: Angiographic diagnosis and differential diagnosis of islet-cell tumors. *Am J Roentgenol* **119**: 121-132, 1973.
 31. Deninger HK: Possibilities of radiologic diagnosis of insulinoma. *Radiologe* **14**: 173-181, 1974.
 32. Bieber WP, Albo RJ: Cystadenoma of the pancreas; its arteriographic diagnosis. *Radiology* **80**: 776-778, 1963.
 33. Ranniger K, Saldino RM: Arteriographic diagnosis of pancreatic lesions. *Radiology* **86**: 470-474, 1966.
 34. Reuter SR, Redman HC, Joseph RR: Angiographic findings in pancreatitis. *Am J Roentgenol* **107**: 56-64, 1969.
 35. Haertel M, Fuchs WA: Angiography in pancreatic trauma. *Br J Radiol* **47**: 641-645, 1974.
 36. Soroudi M, Bookstein JJ: Angiography in acute pancreatic transection. *Radiology* **115**: 309-311, 1975.
 37. Grannis FW, Foulk WT, Miller WE, et al: Diagnosis and management of an arteriovenous fistula of pancreas and duodenum. *Mayo Clin Proc* **48**: 780-782, 1973.
 38. Harris RD, Anderson JE, Coel MN: Aneurysms of the small pancreatic arteries; a cause of upper abdominal pain and intestinal bleeding. *Radiology* **115**: 17-20, 1975.
 39. Suzuki T, Kawabe K, Imamura M, et al: Survival of patients with cancer of the pancreas in relation to findings on arteriography. *Ann Surg* **176**: 37-41, 1972.
 40. Suzuki T, Kawabe K, Nakayasu A, et al: Selective arteriography in cancer of the pancreas at a resectable stage. *Am J Surg* **122**: 402-407, 1971.