

# Transcatheter adrenal ablation for metastatic carcinoma of the breast

Richard D. Jablonski, M.D.

*Department of Endocrinology*

Thomas F. Meaney, M.D.

*Department of Diagnostic Radiology*

O. Peter Schumacher, M.D.,  
Ph.D.

*Department of Endocrinology*

Adrenal insufficiency has been reported following diagnostic adrenal venography. In 1965 Starer<sup>1</sup> reported that only one of his eight patients had adrenal hemorrhage, but there was no permanent abnormality. In 1970 Bayliss et al<sup>2</sup> reviewed 363 cases and found only 10 with adrenal hemorrhage. Of 80 cases reported by Mitty et al,<sup>3</sup> only five had extravasation, but none had prolonged symptoms or persistent hypoadrenalism.

During this time, cases were also reported which indicated that some patients could suffer permanent hypoadrenalism from adrenal venography and adrenal hemorrhage. The vast majority of these cases were patients with adrenal pathology.<sup>4-9</sup> A new twist was added in 1971 when Lecky and Plotkin<sup>10</sup> reported the intentional bilateral ablation of the adrenal glands in a patient with metastatic cancer. After the ablation, the patient had normal baseline studies while taking steroid replacement, but there was no response to corticotropin infusion. Others have also reported the intentional bilateral adrenal ablation in patients with ectopic ACTH syndrome.<sup>11-12</sup>

In 1972 one of the authors (T.F.M.) performed an adrenal venogram for the diagnosis

and localization of a suspected aldosterone tumor of the adrenal gland. Adrenal venous samples were initially obtained for the purpose of assay for aldosterone, and following this selective angiography of the right adrenal vein resulted in inadvertent rupture. Assay of the venous samples obtained from the right adrenal vein showed high levels of aldosterone. After the procedure, the clinical signs and laboratory values indicative of an excess of aldosterone disappeared and have not recurred during the 4-year follow-up of this patient.

In 1974 Zimmerman et al<sup>13</sup> attempted to study the chemical effects of the procedure in a group of six patients with metastatic cancer in whom bilateral adrenalectomy had been planned. In one patient, the procedure was technically unsatisfactory, so their data include five patients. There is no question that four of the five patients had blunted responses to alpha 1, 24 corticotropin (Cortrosyn). The fifth patient had some response. The abnormality with regard to Cortrosyn testing persisted in two patients followed 30 weeks, but one of those two did have more response at 10 weeks and 30 weeks than initially after the procedure. The other patient followed 10 weeks also regained some response to Cortrosyn. Zimmerman et al<sup>13</sup> pointed out that the hospital stay was only 4 days, and there was little morbidity.

In 1975<sup>12</sup> we performed an intentional transcatheter rupture of the adrenal veins in a 56-year-old woman with medullary carcinoma of the thyroid gland in whom Cushing's syndrome developed. Twelve and one-half months after the ablation, urinary 17-hydroxycorticoids, 17-keto-

steroids, and serum cortisol levels still revealed adrenal hypofunction.

Surgical adrenalectomy performed in patients with metastatic carcinoma of the breast can provide significant remission from symptoms of the disease.<sup>14</sup> However, because relief of symptoms is variable and because of difficulty in predicting results of operation, physicians are often reluctant to advise a major surgical procedure in patients with advanced neoplastic disease who are often less than optimal surgical risks.

Because of our previous experience with inadvertent adrenal ablation in the patient with aldosteronism and the intentional adrenal ablation in the patient with Cushing's syndrome, we decided that we would attempt transcatheter adrenal ablation in a small group of patients with metastatic carcinoma of the breast. The patients would be closely followed to determine the efficacy of the procedure. If reliable, this would certainly be associated with a lower morbidity and mortality than surgical bilateral adrenalectomy, as suggested by Lecky and Plotkin<sup>10</sup> in their initial report. It would also save patients with an increased surgical risk from a major anesthetic procedure and prolonged convalescence. It might also allow temporizing in patients with Cushing's disease who are particularly weak or debilitated from hypercortisolism.

### Patients and methods

Eight women with metastatic breast cancer were referred for transvenous adrenal ablation when bilateral adrenalectomy was indicated as the next treatment. They were prepared for the procedure with either cortisone acetate, 100 mg given intramuscu-

larly the night before, the morning of, and the afternoon following the procedure, or dexamethasone, 4 mg given intramuscularly at the same times. Those patients prepared with cortisone acetate were switched to dexamethasone by the second post-operative day. Following percutaneous puncture of the femoral vein, the catheter was introduced into the vena cava, and under fluoroscopic guidance the right and left adrenal veins were catheterized. Retrograde injection of contrast material into the adrenal veins was observed to confirm successful catheterization of the adrenal veins. The catheter was then advanced so that it completely occluded the lumen of the adrenal vein. One to 2 cc of contrast material was then injected to determine if venous rupture had occurred. If the position of the catheter was satisfactory, additional contrast material was injected until the adrenal capsule was fully distended as outlined by the contrast material.

In seven of the eight patients, nitrogen mustard was mixed with the contrast material to provoke a more sclerotic reaction within the adrenal gland and enhance adrenal destruction. The dose of nitrogen mustard was equal to a single intravenous injection; this dosage was varied according to the hematologic state of the patient, and the dose was divided and injected through the catheter into each of the adrenal glands.

The procedure was performed under moderately heavy sedation, since most patients experienced severe back pain and flank pain during the procedure. The moderate to severe back and flank pain produced at the time of the procedure subsided in most patients within 24 hours and

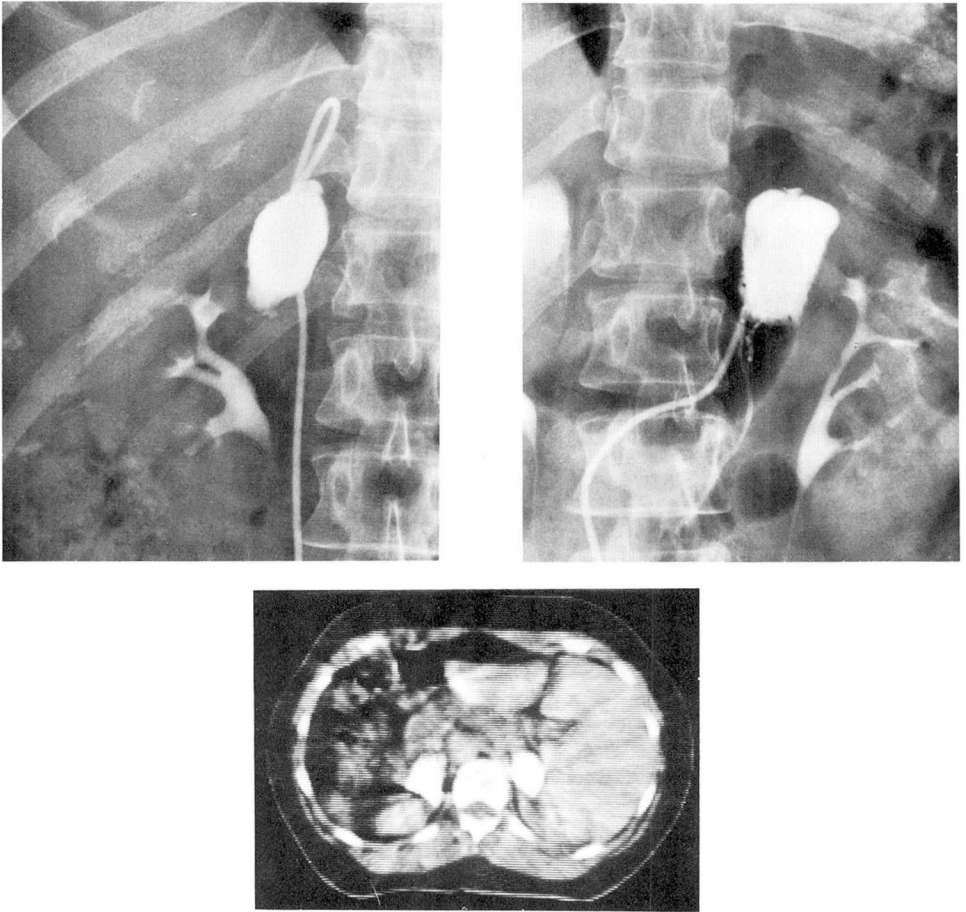
was well controlled by the periodic use of narcotics.

The site of the adrenal rupture was observed in all patients by angiographic films made at the time of the procedure. Because of the difficulty in accurately locating the site of the rupture by standard roentgenography, five patients were studied also by computed axial tomography as an additional localizing aid (*Fig. 1A-C*). From the radiologic standpoint, a technically successful result was observed in seven patients. No complications occurred.

The patients were discharged from the hospital on a regimen of cortisone acetate, 37.5 to 50.0 mg per day, in divided doses, and fluorocortisone acetate (Florinef acetate), 0.1 mg daily. Prior to subsequent testing, the cortisone dose was replaced by dexamethasone, 0.5 mg twice daily, for the week before the test. After a base line plasma cortisol was drawn, Cortrosyn, 0.25 mg, was injected intramuscularly and another plasma cortisol level was obtained 1 hour later. This procedure was performed at 1, 2, 3, and 6 months following the initial adrenal venography in the patients. If the patient was admitted to the hospital for any reason during the year after adrenal ablation, standard 48-hour ACTH infusion was performed. The one patient who was not hospitalized during the year was admitted specifically for the infusion.

## Results

The results of Cortrosyn testing and ACTH infusion are listed in the *Table*. Of the seven patients judged to be technical successes, three had complete ablation when tested with the prolonged ACTH infusion. One patient in whom the procedure was



**Fig. 1.** A, Roentgenogram showing successful rupture of the right adrenal gland. B, Roentgenogram showing successful rupture of the left adrenal gland. C, Computed tomography of the same patient demonstrating collections of contrast material within both adrenal glands.

technically successful was never tested with an ACTH infusion, but is presumed to be ablated as outlined in the discussion. Two patients judged to be technical successes were not ablated when tested with ACTH infusion. One patient with a response to ACTH infusion also was a technical failure due to the inability to rupture the right adrenal vein. The eighth patient died before follow-up testing.

## Discussion

One of the initial purposes of this study was to follow a large number of patients for a prolonged period to determine not only the reliability of transvenous adrenal ablation but also its permanency. The study was stopped with only eight patients because the first two to undergo ACTH infusion (not the first two patients ablated, however) had a significant

Table. Results of Cortrosyn testing and 48-hour ACTH infusion

Cases	Cortrosyn stimulation						ACTH infusion					Ablation		
	1 mo		2 mo		3 mo		6 mo		9 mo				2nd day	
	Pre µg/dl	Post µg/dl	Pre µg/dl	Post µg/dl	Pre µg/dl	Post µg/dl	Pre µg/dl	Post µg/dl	Pre µg/dl	Post µg/dl	17 OH mg/24 hr		Free Cor- tisol µg/24 hr	Procedure technically satisfactory
1	29	39*	...	...	...	...	1.6	13.5	...	...	...	3013	Yes	...
2	1.4	2.3	...	...	...	...	...	...	...	...	...	758	Yes	Yes
3	...	...	1.25	1.25	...	...	1.25	1.3	...	...	...	...	Yes	Yes
4	2.6	9.2	3.5	9.8	1.5	5.4	2.1	8.6	...	...	...	5412	Yes	...
5	1.25	1.7	1.3	1.5	1.25	1.25	1.25	1.3	...	...	...	68.6	Yes	Yes
6	2.1	9.0	...	...	...	...	...	...	...	...	...	3817	No	...
7	4.2	9.2	1.7	14.7	2.8	8.3	3.6	7.9	2.5	12.9	12	573	Yes	Yes
8	...	...	...	...	...	...	...	...	...	...	...	...	...	Yes†

\* Even though patient was receiving cortisone acetate instead of dexamethasone, there was still a demonstrable response to Cortrosyn.  
† Patient 8 died before testing.

response to exogenous ACTH (patients 1 and 6). However, the overall data indicate that three of the seven patients who could be followed did have complete adrenal ablation on the basis of failure to respond to exogenous ACTH infusion. Patient 3 had Cortrosyn stimulation tests similar to one of the three ablated patients (patient 5), and we presume she would have also had complete lack of response to ACTH had we been able to test her.

One of the nonablated patients (patient 1) was the only patient who had not had nitrogen mustard mixed with the radiographic contrast material, and whether this was significant in her failure as judged by ACTH testing can only be speculated.

With the exception of patient 7, patients who had even a modest response to Cortrosyn testing showed significant response to ACTH infusion. The patients with little or no response to Cortrosyn showed complete adrenal ablation when tested with ACTH. If we include patient 7 under these criteria, the error made would have been acceptable, since we would have assumed her to be nonablated and proceeded to substantiate that fact, only to find that she also had complete ablation.

Transcatheter ablation of the adrenal glands seems to offer an alternative to surgical adrenalectomy in selected patients with metastatic carcinoma of the breast. The limitation of the procedure in providing destruction of the adrenal gland is primarily technical. In the experience of one of the authors (T.F.M.), diagnostic adrenal venography is only successful in about 75% of the patients, primarily because of anatomic variation of the

right adrenal vein. Usually this vein drains into the vena cava above the right renal vein. However, in 5% to 10% of the patients, the right adrenal vein is a tributary of one of the inferior hepatic veins and, hence, cannot be selectively catheterized. In such instances, it is not possible to block the adrenal vein by the catheter to produce an adrenal hemorrhage by a retrograde injection. A second limitation of the procedure is possible variability in the extent of the adrenal hemorrhage and, therefore, adrenal gland destruction. The retrograde injection of nitrogen mustard into the adrenal veins during the time of rupture has been considered by Zimmerman et al<sup>13</sup> as a useful adjunct in achieving ablation and reducing the possibility of return of adrenal function.

We recommend performing Cortrosyn stimulation tests at one month. If there is no response to Cortrosyn, adrenal ablation can be assumed. If the patient has even a modest response to Cortrosyn, an ACTH infusion should be performed perhaps to select additional patients who may also undergo transvenous adrenal ablation. Patients with significant response to exogenous ACTH should have either surgical adrenalectomy or hypophysectomy.

### Summary

In four of seven patients with metastatic breast carcinoma in whom transvenous adrenal ablation was attempted, satisfactory ablation was obtained as judged by ACTH infusion. Because of the decreased morbidity and mortality associated with this procedure as compared to surgical bilateral adrenalectomy, we propose that patients with metastatic breast

cancer in whom adrenalectomy is indicated as the next treatment modality have adrenalectomy performed by transvenous adrenal ablation. A method for following the patients is outlined. It is also suggested that the data might be extrapolated to include patients with severe hypercortisolism with Cushing's disease to allow temporizing before proceeding with the definitive procedure or, in fact, making the transvenous adrenal ablation the definitive procedure.

### References

1. Starer F: Percutaneous suprarenal venography. *Br J Radiol* **38**: 675-681, 1965.
2. Bayliss RI, Edwards OM, Starer F: Complications of adrenal venography. *Br J Radiol* **43**: 531-533, 1970.
3. Mitty HA, Nicholis GL, Gabrilove JL: Adrenal venography: clinical-roentgenographic correlation in 80 patients. *Am J Roentgenol Radium Ther Nucl Med* **119**: 564-575, 1973.
4. Eagan RT, Page MI: Adrenal insufficiency following bilateral adrenal venography. *JAMA* **215**: 115-116, 1971.
5. Fisher CE, Turner FA, Horton R: Remission of primary aldosteronism after adrenal venography. *N Engl J Med* **285**: 334-336, 1971.
6. Bookstein JJ, Conn J, Reuter SR: Intra-adrenal hemorrhage as a complication of adrenal venography in primary aldosteronism. *Radiology* **90**: 778-779, 1968.
7. Jorgensen H, Stiris G: Hypertensive crisis followed by adrenocortical insufficiency after unilateral adrenal phlebography in a patient with Cushing's syndrome. *Acta Med Scand* **196**: 141-143, 1974.
8. Von Knorring J: Remission of Cushing's syndrome after phlebography. *Ann Intern Med* **76**: 512-513, 1972.
9. Fellerman H, Dalakos TG, Streeten DH: Remission of Cushing's syndrome after unilateral adrenal phlebography; apparent destruction of adrenal adenoma. *Ann Intern Med* **73**: 585-589, 1970.
10. Lecky JW, Plotkin D: Adrenal function ablation using the angiographic catheter. *JAMA* **218**: 1438, 1971.
11. Eddy RL, McMurphy JF Jr, Best EB, et al:

- Adrenal ablation by venous catheter. *Ann Intern Med* **79**: 273-274, 1973.
12. Rogove HJ, Meaney TF, Schumacher OP: Cushing's syndrome successfully treated by transcatheter adrenal ablation. (Abstr) *Clin Res* **24**: 10A, 1976.
13. Zimmerman CE, Eisenberg H, Spark R, et al: Transvenous adrenal destruction; clinical trials in patients with metastatic malignancy. *Surgery* **75**: 550-556, 1974.
14. Moore FD, Woodrow SI, Aliapoulos MA, et al: Carcinoma of the breast; a decade of new results with old concepts. *N Engl J Med* **277**: 460-468, 1967.