

Definitive treatment of a large pyogenic liver abscess with CT guidance

John R. Haaga, M.D.
Ralph J. Alfidi, M.D.

Department of Radiology

Avram M. Cooperman, M.D.

Department of General Surgery

Thomas Havrilla, M.D.
Thomas F. Meaney, M.D.

Department of Radiology

Stephen A. Ockner, M.D.
Patrick Stiff, M.D.

Department of Internal Medicine

Steve Silver, M.D.

Department of General Surgery

Standard treatment of intraabdominal abscesses consists of drainage and antibiotic therapy.¹⁻³ Previously, open surgical drainage was essential, but recently several authors have treated abscesses by closed aspiration and antibiotics. Novy et al⁴ reported two cases treated by closed aspiration with catheter placement for irrigation. The purpose of the catheters was not for sustained open drainage but for irrigation. We previously performed and reported closed needle aspiration of abscesses guided by CT scan.⁵ We are reporting a case of a solitary hepatic abscess treated by an end-hole No. 14 French Foley catheter placed percutaneously by means of a trocar guided by CT scans.

Case report

A 68-year-old white man with diabetes had a herniorrhaphy performed in another institution and did well until the 10th postoperative day. Then he became hypotensive and acute renal failure developed, at which time he was transferred to the Cleveland Clinic.

On admission, the patient was noted to have an open draining wound in the right inguinal area. Four days later, pulmonary edema, hypotension, and tachycardia developed. Because the patient had had a vena caval plication 6 years previously (for pulmonary emboli) a vena caviagram was done to

rule out renal vein thrombosis. Caval thrombosis above the level of plication extended to T-12 and thrombi occluded both renal veins. Several days later, the patient became febrile (temperature, 104 F), hypotensive, and confused. A preliminary diagnosis of septic shock was made. Intravenous fluids and antibiotics were started. A gallium scan showed increased uptake over the liver (Fig. 1). A CT scan demonstrated a large area of decreased density in the right lobe of the liver (Fig. 2). Under CT guidance, a 22-gauge needle was introduced into the abscess cavity and sanguinous, malodorous, purulent material was aspirated. Following this, a cystostomy trocar with an end hole balloon No. 14 French catheter was introduced beneath the right costal margin into the area of the abscess cavity. Renografin was injected into the abscess cavity to outline the cavity (Fig. 3).

Over the next 3 days, 900 cc of puru-

lent material drained from the catheter cultured *Escherichia coli*, *Proteus mirabilis*, and *Enterococcus*. The patient became afebrile and mental confusion cleared. The tube was left in place for 14 days and at that time a mushroom catheter was replaced through the fistula tract. The mushroom catheter was removed 1 week later and the patient was discharged 30 days following initial tube placement.

Discussion

Efficacy of closed aspiration of abscesses and antibiotic treatments were reported by MacFadzean et al.⁶ A theoretical disadvantage of percutaneous aspiration is intraperitoneal contamination, reaccumulation of the abscess material which may then require repeated aspiration or open drainage. In this case, the large bore catheter provided adequate drainage

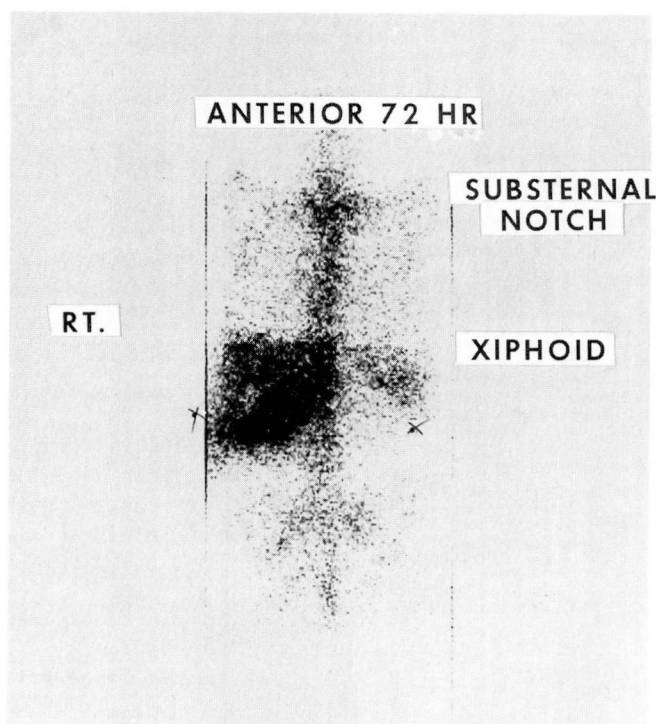


Fig. 1. Gallium scan at 72 hr has increased counts in hepatic area.

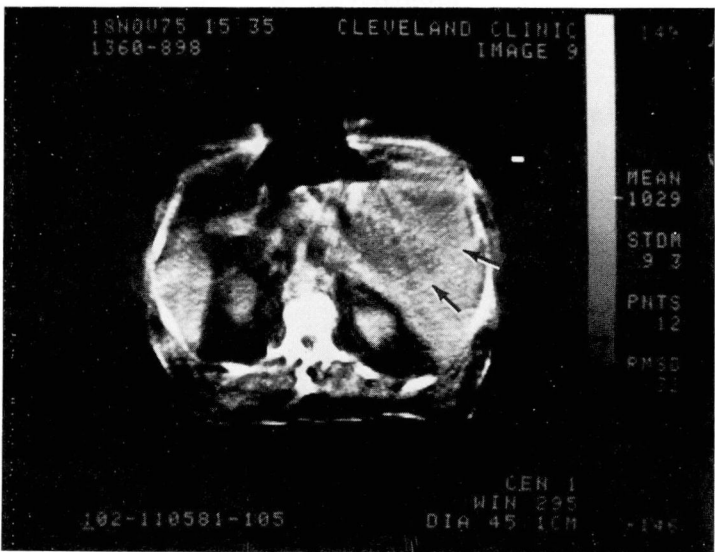


Fig. 2. CT scan shows area of decreased attenuation representing intrahepatic abscess (arrows).

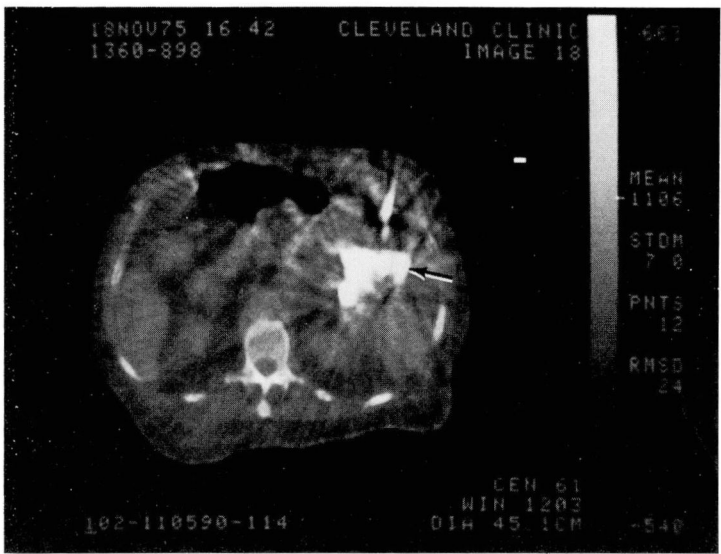


Fig. 3. CT scan demonstrating contrast layered in abscess cavity.

and prevented reaccumulation of the abscess. Percutaneous drainage was chosen for this patient because his cardiovascular and renal status made him a poor surgical risk. Although the CT scanner is useful in guiding needle aspiration for culture and

biopsy, it may also provide definitive treatment of abscesses in selected cases.

Acknowledgment

We thank Miss Linda Kreeger, who provided considerable technical

assistance in the performance of this study.

References

1. Ochsner A, Debaeky M, Murray S: Pyogenic abscess of the liver. II. An analysis of 47 cases with review of the literature. *Am J Surg* **40**: 292-319, 1938.
2. Lee JF, Block GE: The changing clinical pattern of hepatic abscesses. *Arch Surg* **104**: 465-470, 1972.
3. Ariel IM, Kazarian KK: Classification, diagnosis, treatment of subphrenic abscess. *Rev Surg* **28**: 1-21, 1971.
4. Novy SB, Wallace S, Goldman AM, et al: Pyogenic liver abscess; angiographic diagnosis and treatment by closed aspiration. *Am J Roentgenol Radium Ther Nucl Med* **121**: 388-395, 1974.
5. Haaga JR, Alfidi RJ: Precise biopsy localization by computed tomography. *Radiology*. In press.
6. McFadzean AJS, Chang KPS, Wong CC: Solitary pyogenic abscess of liver treated by closed aspiration and antibiotics; a report of 14 consecutive cases with recovery. *Br J Surg* **41**: 141-152, 1953.