

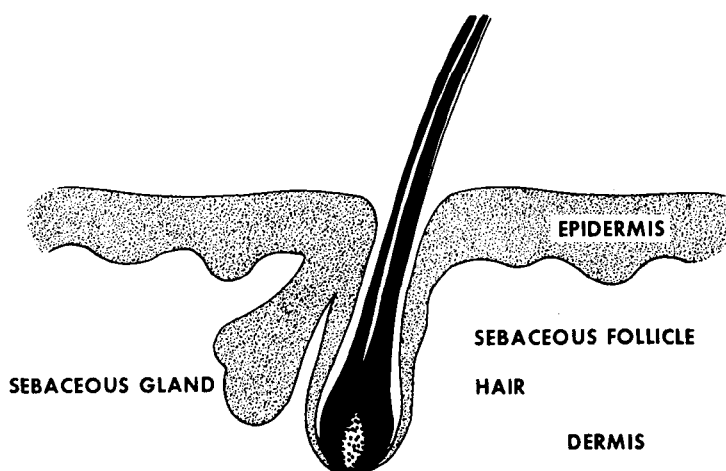
Scientific approach to the treatment of acne vulgaris

Wilma F. Bergfeld, M.D.

Department of Dermatology
Department of Pathology

Acne vulgaris is a dermatosis which involves the pilosebaceous apparatus of the skin; namely, the sebaceous gland and hair follicle (*Fig. 1*). Clinically, the skin changes are those of increased numbers of comedones (blackheads), milia (whiteheads or closed comedones), inflammatory papulopustular lesions, cysts, and atrophic or hypertrophic scars. These acne lesions are most frequently observed on the face and less frequently on the chest and back. This distribution follows the embryonic development of the sebaceous gland with the greater number of glands being distributed over the face and lesser number and smaller glands distributed over the scalp, chest, and trunk. Acneform lesions may involve other areas such as arms, legs, and intertriginous skin. Acne vulgaris has been associated with other diseases of the pilosebaceous apparatus such as seborrheic dermatitis of the face and scalp, dissecting folliculitis of the scalp, and hidradenitis suppurativa predominately of the axilla and groin.¹ Recognition and treatment of these associated entities result in concomitantly good response to therapy.

The onset of acne vulgaris is usually associated with the increased androgen stimulation of the sebaceous follicle which occurs either prepubertally or at puberty. Acneform lesions develop in



PILOSEBACEOUS APPARATUS

Fig. 1. Drawing shows pilosebaceous apparatus of the skin.

42% of girls and 36% of boys between the ages of 8 and 10 years,² and in the remainder of the adolescent group acneform lesions develop between the ages of 10 and 15 years. Acne vulgaris, a disease of the adolescent, is relatively self-limited, but on occasion it will continue into adulthood.

Clinically, acne vulgaris can be divided into two major types: inflammatory and noninflammatory. The noninflammatory lesions, the comedone and milium, are primary lesions of acne from which the inflammatory

lesions develop.³ The inflammatory lesions, papulopustular and cystic, produce moderate to severe destruction of the dermis of the skin which eventuates in scarring of the involved area (*Table 1*). Both the inflammatory lesion and the scar are unacceptable to the young adolescent. Good results can be obtained by removing the primary lesions by mechanical extraction and acne surgery, which prevent the formation of the more severe inflammatory acne lesions.

Pathogenesis of acne

The pathogenesis of an acne lesion is influenced by many factors. However, the major, local etiologic factors involve the pilosebaceous apparatus. These are (1) abnormal keratinization of the sebaceous follicle,⁴⁻⁶ (2) the presence of microflora,⁷⁻¹¹ which produce a lipase capable of breaking down the normally secreted sebum into a short-chain fatty acid, C₁₀ to C₁₈.^{11, 12}

Table 1. Classification of acne

Type of acne	Severity
Noninflammatory	Minor
Comedones	
Milia	
Inflammatory	Intermediate
Papulopustular	Moderate
Cystic	Moderate-severe
Cystic-erosive	

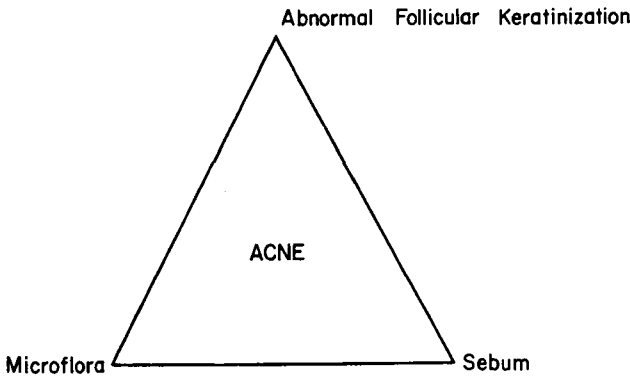


Fig. 2. Diagram shows factors that influence the pathogenesis of acne.

(Fig. 2). This fatty acid is extremely irritating to the surface of the skin and has been known to cause an irritant reaction when released into the dermis, resulting in an inflammatory acne lesion (Table 1).

The keratinizing epithelium of the sebaceous follicle demonstrates increased rate of keratinization of cohesion of the horn cells. This cohesive-ness reduces normal shedding and forms an impaction (open or closed) comedone. The impaction can be exaggerated by stomal edema which is frequently seen in the premenstrual female.

The microflora cultured from the keratogenous debri (horn) are *Corynebacterium acnes*, the most prominent and important organism, staphylococci (12 varieties), and *Pityrosporum ovale* and *orbicularis*. The latter two aerobes are found in superficial portions of the infundibulum of the follicle; the an-aerobic diphtheroid, *C. acnes*, is found colonized between the lamellar concentric rings of the horny material within the comedone. All of these organisms demonstrate a lipase activity which is capable of splitting the lipid sebum into short-chain fatty acids,

triglycerides, and less important squalene.

The inflammatory lesions observed under light microscopy develop from the leakage of horny materials, fatty acids, and microflora into the supporting connective tissue and dermis, with a resulting intense inflammatory reaction composed of polymorphic leukocytes, macrophages, giant cells, tissue necrosis, and later fibrosis. The greatest amount of fibrosis and necrosis is in the acne vulgaris major type and results in atrophic or hypertrophic scars on healing.

Therapeutic approaches

The therapy of acne vulgaris is directed toward the known etiologic factors and occasionally to the lesser contributing factors. The major factors are again abnormal keratinization and microflora with lipase activities which produce an irritating short-chain sebum lipid (Table 2).

The primary acne lesions, comedone and milium, result from abnormal keratinization of sebaceous follicle and can easily be removed by mechanical extraction. This technique can be taught to patients so that it can be

Table 2. Treatment of acne vulgaris

Acne minor
Topical agents
Lipid surfactants
Vitamin A acid 0.05% to 0.1% cream, 0.25% gel
Acne surgery
Ultraviolet light
Drying-oxidizing agents: benzoyl peroxide
Antiseborrheic shampoo
Acne intermediate
Minor +
Topical antibiotic solution
Parenteral maintenance antibiotics (TCN)
Cryotherapy
Acne major
Minor + intermediate +
Corticosteroids, parenteral
Cryotherapy—selected cases
Avoidance of ultraviolet light

done at home. By eliminating the primary lesion one prevents the formation of an inflammatory acne lesion, papulopustular or cystic.¹³ Another topical agent that removes the primary lesion is vitamin A acid (0.05% to 0.1%) in an alcohol wipe or cream. This agent, when applied to the skin daily, reduces the abnormal keratinization occurring in the sebaceous follicle, and thus prevents the formation of comedones and milia.¹⁴ It is not particularly effective against the inflammatory lesions. Vitamin A has long been used parenterally in doses of 50,000 to 100,000 I.U. daily for treatment of acne vulgaris minor type. This has been clinically helpful, but double-blind studies have not supported the clinical impression.²

Irritating acnegenic surface lipids of the skin may be removed by topical use of lipid solvents; cleansing agents, in the form of soaps, detergents, astringents, nonionic solutions, abrasive

agents; and salicylic acid preparations.¹⁵ Precipitated sulfur solutions should be avoided since they are mildly comedogenic.¹⁶

The reduction of the normal microflora and the lipase activity of these organisms is extremely helpful in controlling inflammatory acne, intermediate and major types. This can be done by topical and systemic therapy. Topical therapy includes antibiotic solution, 2% erythromycin alcohol solution, which has been clinically effective in reducing the inflammatory lesion;¹⁷ benzoyl peroxide, an oxidizing agent, has also been a successful topical agent. The action of the latter appears to dry and oxidize the inflammatory lesion and destroys the anaerobic lipase producer or *C. acnes*. Since the *C. acnes* is the most significant lipase producer in the inflammatory lesion, control of the number and the lipase activity of this diphtheroid definitely improves the acneform eruption.

Tetracyclines, erythromycin, and minocycline administered parenterally are also effective agents in treating the inflammatory acne of intermediate to major types.¹⁸⁻²⁰ These antibiotics reduce the lipase activity and colonization of the microflora even when administered in 50- to 250-mg maintenance doses daily.¹⁹ Tetracyclines administered to adolescents younger than age 11 is contraindicated because of permanent discoloration of the secondary teeth.

Since the evolution of the acneform lesion is indirectly related to the size and function of the sebaceous gland and its production of sebum, it is possible to control acne vulgaris by controlling the sebaceous gland and its sebum production. This has been

done effectively by the use of estrogen products parenterally, which appear to inhibit the androgen stimulation of the sebaceous gland.²¹⁻²³ The most commonly used estrogen products are easily obtained as birth control pills, diethylstilbestrol and Premarin. In selecting a particular estrogen product, one should avoid those with moderate amounts of progesterone²⁴ or androgen derivatives, since these two agents appear to have acnegenic properties. Diuretics can be used as adjunctive therapy for girls and young women if moderate premenstrual tension and tissue edema are noted. By reducing the tissue edema one indirectly reduces the impaction of the sebaceous follicles.

Corticosteroids given parenterally have been especially helpful in controlling the major types of inflammatory acne. The mechanism of action is their anti-inflammatory qualities rather than a direct action on the sebaceous gland or its follicle or both. Systemic steroids are effective under the equivalent dose of 20 mg/day of prednisone. A larger dose results in abnormal keratinization of the sebaceous follicle, comedone formation, and steroid acne.²⁵ Topical steroids, especially the hydrocortisone hydrophilic creams, are effective as anti-inflammatory agents and can be used sparingly and infrequently. The fluorinated topical corticosteroids often produce a resistant acneform eruption which is extremely difficult to treat.

A variety of physical agents have been used in treating and controlling acne vulgaris of minor, intermediate, and major types. These agents have been mainly ultraviolet light, cryotherapy, and roentgen therapy. Roent-

Table 3. Precipitating factors, agents

Hormones (androgen)
Hereditary
Topical irritants, soaps, precipitated sulfur coal tar, chlorinated hydrocarbons
Systemic drugs, halogens, high dose steroids
Physical agents, cobalt therapy
Tissue edema
Anxiety-tension state
Diet (controversial)

gen therapy is seldom used today because of severe postradiation changes that occur some 20 years after treatment. It was an effective agent mainly in treating cystic acne vulgaris.²⁶ Today, however, ultraviolet light of suberythema dosage is effective in reducing comedone and inflammatory acne. It appears to decrease the synthesis of DNA in the keratinizing epithelium and inhibits vascular leakage and stomal inflammation. Cryotherapy, carbon dioxide slush, or liquid nitrogen have been used in treating the intermediate and major types of pustular and cystic acne. Clinically, this treatment reduces the cutaneous inflammation, hastens the healing of the larger acneform lesions, and reduces the late fibrosis and scarring of the skin (*Table 3*).

Summary

Acne vulgaris, a common dermatosis of the adolescent, is initiated by androgen stimulation of the pilosebaceous apparatus; namely, the sebaceous gland and sebaceous follicle. The major etiologic, acnegenic changes are the abnormal keratinization of the sebaceous follicle, and aerobic and anaerobic microflora which produce a lipase capable of breaking down sebum into irritating acnegenic surface lipids.

By directing treatment of acne vulgaris toward these specific entities, the patient can be greatly improved if not totally cleared of the acneform eruption. By attempting treatment of these adolescents at an early age, one reduces the development of inflammatory lesions and subsequent scarring.

References

1. Kligman AM: An overview of acne. *J Invest Dermatol* 62: 268-287, 1974.
2. Burton JL, Cunliffe WJ, Stafford I, et al: The prevalence of acne in adolescence. *Br J Dermatol* 85: 119-126, 1971.
3. Smith MA, Waterworth PM: The role of comedones in acne vulgaris. *Br J Dermatol* 54: 337-338, 1962.
4. Vaserinsh P: Keratinization of pilar structures in acne vulgaris and normal skin. *Br J Dermatol* 81: 517-524, 1969.
5. Knirlson DD: Ultrastructural observations in acne vulgaris; the normal sebaceous follicle and acne lesions. *J Invest Dermatol* 62: 288-307, 1974.
6. Plewig G: Follicular keratinization. *J Invest Dermatol* 62: 308-315, 1974.
7. Marples RR, McGinley KJ, Mills OH: Microbiology of comedones in acne vulgaris. *J Invest Dermatol* 60: 80-83, 1973.
8. Weary PE: Comedogenics potential of the lipid extract of pityrosporum ovale. *Arch Dermatol* 102: 84-91, 1970.
9. Marples RR, Izumi AK: Bacteriology of pustular acne. *J Invest Dermatol* 54: 252-255, 1970.
10. Marples RR, Kligman AM, Lantis LR, et al: The role of the aerobic microflora in the genesis of fatty acids in human surface lipids. *J Invest Dermatol* 55: 173-178, 1970.
11. Kellum RE: Short chain fatty acids (below C₁₂) of human skin surface lipids. *J Invest Dermatol* 48: 364-371, 1967.
12. Kligman AM, Wheatley VR, Mills OH: Comedogenicity of human sebum. *Arch Dermatol* 102: 267-275, 1970.
13. Lowney ED, Witkowski J, Simons HM, et al: Value of comedo extraction in treatment of acne vulgaris. *JAMA* 189: 1000-1002, 1964.
14. Kligman AM, Fulton JE Jr, Plewig G: Topical vitamin A acid in acne vulgaris. *Arch Dermatol* 99: 469-476, 1969.
15. Mills OH Jr, Kligman AM, Stewart K: The clinical effectiveness of topical erythromycin in acne vulgaris. *Cutis* 15: 93-96, 1975.
16. Mills OH Jr, Kligman AM: Is sulphur helpful or harmful in acne vulgaris? *Br J Dermatol* 86: 620-627, 1972.
17. Cunliffe WJ, Forster RA, Greenwood ND, et al: Tetracycline and acne vulgaris; a clinical and laboratory investigation. *Br Med J* 4: 332-335, 1973.
18. Crounse RG: The response of acne to placebos and antibiotics. *JAMA* 193: 906-910, 1956.
19. Mills OH Jr, Marples RR, Kligman AM: Acne vulgaris; oral therapy with tetracycline and topical therapy with vitamin A. *Arch Dermatol* 106: 200-203, 1972.
20. Hassing GS: Inhibition of *Corynebacterium acnes* lipase by tetracycline. *J Invest Dermatol* 56: 189-192, 1971.
21. Jarrett A: The effects of stilboestrol on the surface sebum and upon acne vulgaris. *Br J Dermatol* 67: 166-179, 1955.
22. Pochi PE, Strauss JS: Effect of cyclic administration of conjugated equine estrogens on sebum production in women. *J Invest Dermatol* 47: 582-585, 1966.
23. Strauss JS, Kligman AM, Pochi PE: The effect of androgens and estrogens on human sebaceous glands. *J Invest Dermatol* 39: 139-155, 1962.
24. Strauss JS, Kligman AM: The effect of progesterone and progesterone-like compounds on the human sebaceous gland. *J Invest Dermatol* 36: 309-319, 1961.
25. Strauss JS, Pochi PE: The human sebaceous gland; its regulation by steroidal hormones and its use as an end-organ for assaying androgenicity in vivo. *Recent Prog Horm Res* 19: 385-444, 1963.
26. Strauss JS, Kligman AM: Effect of x-rays on sebaceous glands of the human face; radiation therapy of acne. *J Invest Dermatol* 33: 347-356, 1959.

Additional references

- Robinson HM Jr: Role of antibiotics in therapy of acne. *Arch Dermatol* 69: 414-417, 1954.
- Wallman IS, Hilton HB: Teeth pigmentation by tetracycline. *Lancet* 1: 827-829, 1962.
- Marples RR, Dorning DT, Kligman AM: In-

- fluence of pityrosporum species in generation of free fatty acids in human surface lipids. *J Invest Dermatol* **58**: 158-159, 1972.
- Marples RR: The microflora of the face and acne lesions. *J Invest Dermatol* **62**: 326-331, 1974.
- Emerson GW, Strauss JS: Acne and acne care. *Arch Dermatol* **105**: 407-411, 1972.
- Freinkel RK: Current concepts; pathogenesis of acne vulgaris. *N Engl J Med* **280**: 1161-1163, 1969.
- Fulton JE Jr, Plewig G, Kligman AM: Effect of chocolate on acne vulgaris. *JAMA* **210**: 2071-2074, 1969.
- Hecht H: Hereditary trends in acne vulgaris. *Dermatologica* **121**: 297-307, 1960.