

Conjoined arterial anastomosis; an aid in revascularizing donor kidneys with multiple renal arteries

Lynn H. W. Banowsky, M.D.

Department of Urology

James Kilpak, B.S.*

Stefan Loening, M.D.

Bruce H. Stewart, M.D.

Ralph A. Straffon, M.D.

Department of Urology

Magnus O. Magnusson, M.D.

Department of Urology

*Department of Hypertension and
Nephrology*

William E. Braun, M.D.

Department of Immunopathology

*Department of Hypertension and
Nephrology*

Many transplant centers have reported numerous techniques for the successful revascularization of donor kidneys that have multiple vessels. Several early reports from major centers have not included the technique of conjoining two vessels to form a common ostium.¹⁻³ Conjoined anastomosis for joining multiple tubular structures into a single functioning unit has been helpful to vascular and urologic surgeons.⁴⁻⁷

At the Cleveland Clinic, when the Carrel patch cannot be used, the conjoined anastomosis has become the preferred technique for revascularizing donor kidneys with multiple vessels. The facility with which this anastomosis can be performed technically and its associated theoretically favorable flow characteristics⁵ have been the basis for this preference. This report focuses special attention on the unique advantages provided by conjoining two small vessels and also presents preliminary laboratory data which indicate that the theoretically favorable flow characteristics are in fact real.

Materials and methods

The technique for performing the conjoined vascular anastomosis has been described⁴ and is illustrated in *Figure 1*. With small vessels (1-2 ml) the initial side-to-side anastomosis should be done with interrupted 6-0 or 7-0 vascular silk

* Case Western Reserve University
School of Medicine.

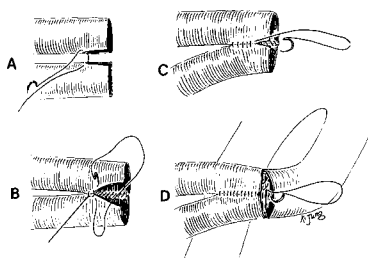


Fig. 1. Illustration of the technical steps in performing the conjoint arterial anastomosis.

rather than with the continuous suture shown in *Figure 1*. Unless both vessels are very small, optical magnification and microvascular instruments are not necessary.

Laboratory flow rates measured in excised canine arteries. The renal arteries and common iliac arteries in sacrificed mongrel dogs were dissected bilaterally, and suitable segments were excised. The renal arteries varied from 1.5 to 4.0 ml in diameter, and were divided into two groups. Group I had nine pairs of arteries of approximately equal diameter. Group II had seven pairs of arteries of unequal diameter, each pair consisting of one large and one smaller artery. The difference in arterial diameter within each pair in group II varied from a minimum discrepancy of 25% to a maximum discrepancy of 50%. The internal diameter of each artery was established metrically by direct measurement.

Each artery within a pair was then separately connected to a gravity flow system and the flow was measured and recorded. The gravity flow system consisted of a large flask containing 5 liters of normal saline solution that was placed on a shelf 122 cm above the artery. The flask was connected to a 1-ml cannula by plastic tubing which could be inserted into the arterial

lumen. A rubber shod clamp was used to start and stop flow through the system.

Flow rate was measured directly in graduate cylinders. The flow rate through each artery was measured five times for 15-second intervals. The average of the five values was multiplied by four and expressed as cubic centimeters per minute. Before and after measurement of each flow rate, maximum flow through the system was determined to be certain that there had been no variation. In each instance flow through an artery was measured with the kidney removed from the system so that intrarenal vascular resistance would not be an uncontrolled variable.

After the initial flow rate through each artery of a pair had been determined, the paired arteries were united with a conjoint anastomosis, and the anastomosis was performed with interrupted sutures of 6-0 cardiovascular silk. The common ostium of the two arteries was then anastomosed end-to-end with a 1.0- to 1.5-cm segment of iliac artery. The proximal end of the iliac artery was connected to the gravity flow system, and individual flow rates for each artery were again measured through the conjoint anastomosis. The artery not measured was occluded with a small Bulldog clamp. Anastomotic leaks were repaired prior to any flow measurement.

The initial flow recorded through an artery prior to anastomosis was presumed to be a theoretical maximum for that artery. Flow rates recorded after anastomosis were expressed as a percentage of the theoretical maximum for that vessel.

Clinical experience. From 1963 through 1974, a total of 23 donor

organs with multiple arteries had a conjoined arterial anastomosis. The conjoined anastomosis was placed end-to-end with the hypogastric artery of the recipient; no end-to-side anastomoses were necessary. The criteria for performing the conjoined anastomoses were as follows: (1) cadaver kidneys with multiple arteries harvested without a Carrel patch, (2) any live donor kidney with multiple arteries (a Carrel patch being contraindicated in live donors), (3) the two vessels had to be situated so that they could be brought together easily for the conjoined anastomosis to be free of angulation or tension, and (4) the two vessels had to be of approximately the same internal diameter.

For cadaver kidneys that were to undergo a period of pulsatile perfusion, the conjoined anastomosis was always performed in the recipient just prior to revascularization. This was done so that repeat cannulation of the artery would not cause intimal damage to the newly formed anastomosis. To minimize ischemic injury the allograft was placed in a basin of iced saline solution, and the conjoined anastomosis was performed under hypothermic conditions. As soon as the conjoined anastomosis was completed, the allograft was placed in the previously prepared iliac fossa and standard revascularization was accomplished.

An additional donor kidney was found to have a renal artery aneurysm located at the bifurcation of the main renal artery. Excision of the aneurysm required division of the anterior and posterior branches from the main renal artery and from each other. The anterior and posterior branches were sutured together to form a common

ostium. The common ostium was sutured to the normal free stump of the donor renal artery (*Fig. 2*). Anastomotic leaks were repaired after the kidney was placed back on pulsatile perfusion. Approximately 12 hours

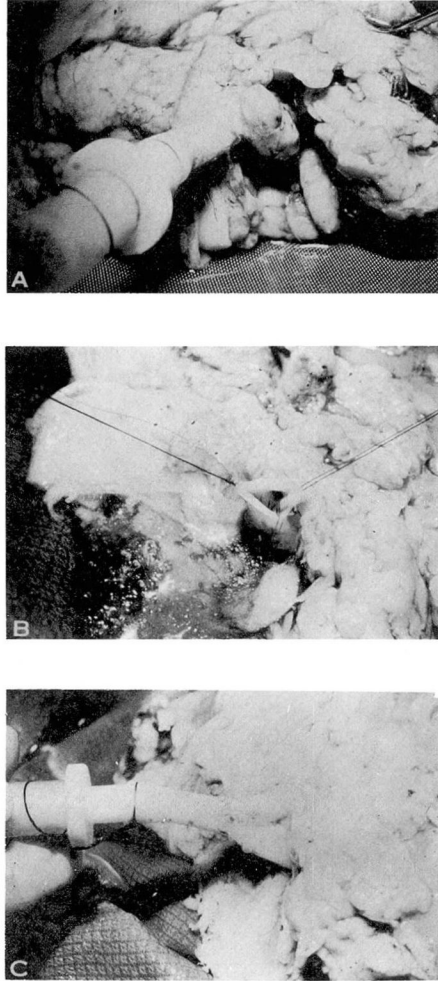


Fig. 2. A, Renal artery aneurysm in donor kidney on pulsatile perfusion. B, Aneurysm has been excised and anterior and posterior divisions of the renal artery have been conjoined to form a common ostium. C, Repair is completed by suturing the normal main renal artery stump to new common ostium; the kidney is placed back on pulsatile perfusion.

later the kidney was transplanted into an acceptable recipient. A standard arterial anastomosis was possible between the renal artery and the hypogastric artery.

Results

Canine arterial anastomosis. The results of the flow studies after conjoined anastomosis are shown in *Tables 1 and 2*, and graphically demonstrated in *Figure 3*. All results are expressed as a percentage of the initial flow; thus values of more than 100% represent a higher flow in an artery after conjoined anastomosis. In group I, each pair of arteries was approximately the same diameter; flow increased after conjoined anastomosis in 10 of the 18 arteries. The ranges of postanastomotic flow rates ranged from a high of 138% to a low of 91% of the original flow rate through the

Table 1. Common ostium anastomosis; vessels of equal diameter; 9 anastomoses

Experiment no.	Lumen diameter mm	O/O initial flow
1	3.0	94
	3.0	91
2	3.0	102
	3.0	105
3	4.0	93
	4.0	93
4	1.5	114
	1.5	114
5	3.0	95
	2.5	95
6	2.0	117
	2.0	138
7	1.5	112
	1.5	118
8	2.0	111
	2.0	116
9	2.0	95
	2.0	93

Table 2. Common ostium anastomosis; vessels of unequal diameter

Experiment no.	Lumen diameter mm	O/O initial flow
1	2.0	93
	1.5	98
2	2.0	90
	3.0	94
3	1.5	96
	3.0	97
4	1.5	93
	3.5	101
5	1.5	108
	3.0	98
6	1.5	118
	3.0	97

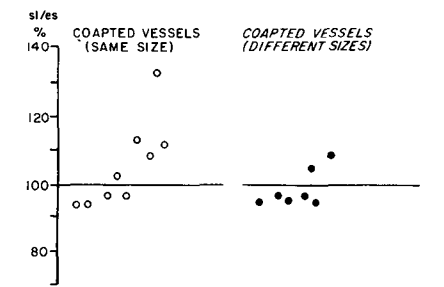


Fig. 3. A graphic representation of post-anastomotic flow rates in groups I and II expressed as a percentage of preanastomotic values.

artery. The average postanastomotic flow rate was 105.5%. In no instance was postanastomotic flow significantly decreased.

In group II, arteries of unequal size were joined; 3 of 14 arteries had flow rates higher than preanastomotic values. Postanastomotic flow rates ranged from a low of 88% to a high of 118% with an average of 97.4%. Although flow rates were lower when arteries of unequal size were conjoined, they were still acceptable, and in no instance did a significant reduction in flow occur.

Clinical results. The immediate and 1-year function of renal allografts with a conjoined anastomosis has been reported.⁶ To summarize these results, the postoperative incidence of acute renal failure was higher than in donor organs having a single artery, but the 1-month and 1-year levels of function were comparable.

In none of the 24 patients did renal artery thrombosis result in loss of an allograft, nor did bleeding from the multiple suture lines require reoperation. In one patient clinically significant hypertension developed as a result of stenosis of one of the two conjoined arteries. This patient did not require reoperation, since his blood pressure was adequately controlled with medication and there was no deterioration in allograft function. A urine leak developed postoperatively in one patient, but this was caused by a technical problem at the ureteroneocystostomy, not ureteral devascularization and sloughing.

The patient who received the donor organ that originally had a renal artery aneurysm has done very well. In the postoperative period the allograft functioned immediately. The patient is now 26 months posttransplantation and has satisfactory function of the allograft (serum creatinine <2.0 mg/100 ml).

Discussion

Results of preliminary laboratory studies indicated that no significant reduction in flow occurred in any vessel after conjoined anastomosis. In group I, when vessels of comparable size were joined, flow in 10 of the 18 arteries was actually higher after the anastomosis. The predicted theoretical

flow advantages of this anastomosis appear to be real.

In group II, when vessels of unequal size were joined, only 3 of 14 arteries showed an increase in flow; however, none of the vessels had a significant reduction in flow. Flow rates were quite acceptable averaging 97.4% of preanastomotic values.

Previously, it was thought that disparity in vessel size was a contraindication to performing a conjoined anastomosis. These data would indicate that conjoined anastomosis is effective when discrepancy in vessel size is not greater than 50%.

The clinical experience gained in 24 renal transplant recipients demonstrates that the conjoined vascular anastomosis is an extremely reliable technique for the revascularization of donor kidneys having multiple arteries. This anastomotic technique resulted in a high degree of vessel patency (100%). A normal postoperative renal angiogram is shown in

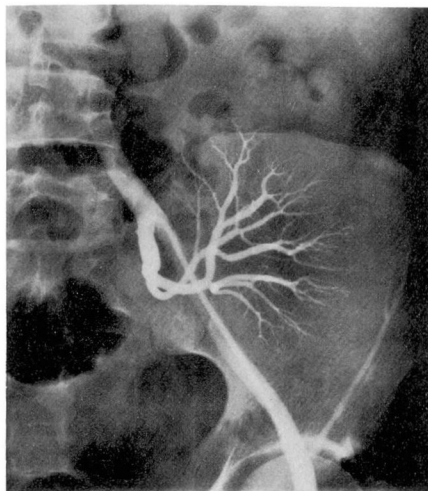


Fig. 4. Normal postoperative renal angiogram demonstrating the conjoined arterial anastomosis.

Figure 4. Only one of the 48 arterial segments that were conjoined developed a clinically significant stenosis. Although this patient became hypertensive, medical control was achieved and reoperation avoided. The surgical correction of other renal vascular problems, e.g., renal artery aneurysms and fibrous lesions extending to the renal artery bifurcation has also been facilitated by use of the conjoined technique.

The reliability of any surgical technique is in a large part determined by the ease with which it can be performed. The conjoined anastomosis offers a relatively simple technical alternative to other procedures available for revascularizing donor kidneys with multiple arteries. Several factors contribute to this relatively technical simplicity. The initial conjoining of the vessels is performed *ex vivo* where exposure and illumination are optimal. By forming a common ostium of larger diameter, an end-to-end anastomosis with the hypogastric artery is usually possible in the recipient. This eliminates three potential technical problems: (1) when two renal arteries are present, the larger of the two may still be significantly smaller than the hypogastric artery, and due to this discrepancy in size an end-to-end discrepancy anastomosis may not be feasible; (2) the need to perform a technically more lengthy and difficult end-to-side anastomosis of one or both renal arteries is avoided; and (3) there is no chance of compromising the circulation to the ipsilateral lower extremity.

The conjoined arterial anastomosis not only offers the above mentioned technical advantages, but also has favorable hemodynamic characteris-

tics. The union of two vessels forms a common ostium whose cross sectional area may be two times greater than the sum of the cross sectional area of the two separate vessels. Since resistance to flow in a vessel is inversely related to the fourth power of the vessel's radius, the coapted vessels have a lower resistance and theoretically higher flow than a comparable length of either vessel prior to their union.

By anastomosing the common renal artery ostium end-to-end with the hypogastric artery, revascularization has been accomplished without any anastomosis being end-to-side. Avoiding an end-to-side anastomosis with its inevitable right angle energy loss is desirable in obtaining maximum flow to the allograft. Szilagyi et al⁸ have demonstrated that an end-to-end anastomosis always provides flow rates that are superior to comparable vessels joined by an end-to-side anastomosis.

The conjoining of multiple renal arteries followed by an end-to-end anastomosis with the hypogastric artery offers the attractive combination of technical facility, no increase in warm revascularization time, high patency rates, and optimal flow characteristics through each anastomosis. Although at times neglected in previous reports, this technique should be recommended to renal transplant surgeons as a relatively uncomplicated alternative in revascularizing donor kidneys that have multiple arteries.

Summary

At the Cleveland Clinic the conjoined arterial anastomosis is the preferred technique for revascularizing multiple artery donor kidneys that have been harvested without a Carrel patch. This technique has been used

successfully in 24 renal transplant recipients. The technical simplicity and theoretical hemodynamic advantages are stressed. Preliminary laboratory data suggest that disparity in vessels of 50% or less need not be a contraindication to performing a conjoined anastomosis.

References

1. Belzer FO, Schweizer RT, Kountz SL: Management of multiple vessels in renal transplantation. *Transplant Proc* 4: 639-644, 1972.
2. Simmons RL, Tallent MB, Kjellstrand CM, et al: Kidney transplantation from living donors with bilateral double renal arteries. *Surgery* 69: 201-207, 1971.
3. Starzl TE: Experience in Renal Transplantation. Philadelphia, WB Saunders Co, 1964.
4. Banowsky LH, Braun WE, Magnusson MO, et al: Current status in adult renal transplantation at the Cleveland Clinic. *J Urol* 111: 578-581, 1974.
5. Mendez R, Mendez RG, Payne JE, et al: Management of multiple renal arteries in renal transplantation. *Urology* 3: 409-412, 1974.
6. Banowsky LH, Siegel DF, Hewitt CB, et al: Renal transplantation. I. Use of donor organs with multiple vessels. *Urology* 4: 643-649, 1974.
7. Albert D, Persky L: Conjoined end-to-end uretero-intestinal anastomosis. *J Urol* 105: 201-204, 1971.
8. Szilagyi E, Whitcomb JG, Schenker W, et al: The laws of fluid flow and arterial grafting. *Surgery* 47: 55-73, 1960.