

Selective, conservative operations for cancer of the breast

Robert E. Hermann, M.D.

Department of General Surgery

One of the common questions that surgeons are asking one another is, "What operation are you doing now for breast cancer?" The answer usually is, "I'm still doing radical mastectomies," or, "I've switched to the modified radical mastectomy." Rarely do surgeons admit that one can be selective in choosing an operation for breast cancer. The following quote from a paper by Urban and Castro summarizes our view at the Cleveland Clinic: "The scope of the primary operative procedure should be correlated with the extent of the clinical pathologic setting of disease in each individual patient with the aim of removing all disease present while interfering least with appearance and function."¹ We believe that surgeons have a choice in operative procedures for the potential cure of breast cancer based on the extent of the disease, the location and size of the primary lesion, and their own knowledge and philosophy about the treatment of primary breast cancer.

The operations available for the treatment of breast cancer include the extended radical mastectomy, the standard radical mastectomy, modified radical mastectomy, total mastectomy with axillary biopsy and, finally, partial mastectomy with or without axillary biopsy. All of these operative procedures have the capacity to remove all local and regional disease. If the tumor has metastasized and become systemic, then adjuvant therapy is advisable.

There are two aspects to the surgeon's choice of operation. First, concerning the breast, is it always necessary to remove all of it, or are there small, "early" lesions which may be cured by removing only part of it? And second, what about the axillary nodes? How are they best treated? Is it more beneficial to do a complete axillary nodal dissection, or is it better to leave the nodes intact for fear of destroying some aspect of host resistance? After much reflection and discussion, I believe that the major value of taking out the axillary nodes is for staging purposes. If the nodes look and feel normal to the surgeon at operation, I believe one or two nodes should be removed for biopsy

to prove that the nodes are normal. If the nodes are not involved by metastases, I do not think it is necessary to do a complete axillary dissection. However, if the axillary nodes appear to be involved, either by preoperative clinical staging or by intraoperative staging, by palpation or by biopsy, then the entire group of axillary nodes should be removed to determine the extent of the disease as well as to remove all evidence of regional metastatic disease, if only to reduce the total tumor burden in the body. If there is advanced axillary involvement, one should consider additional adjuvant therapy.

A number of prognostic factors in breast cancer have been identified (Table 1). Certainly, the most important factor is the stage of the disease at the time the woman is examined by a physician. Obviously, if she has clinical Stage I, pathologic Stage I disease, there is an excellent chance of cure. If she has Stage III or Stage IV, the disease is beyond the hope of local or regional control and is a systemic problem. The histologic type of the tumor is of some significance; some histologic types are known to behave more aggressively than others. The immunochemistry of breast tumors and the presence of estrogen-binding protein in the tumor, which we are just now beginning to study, may be important. We are now beginning to study the effect of other hormones and chemicals in the body which may stimulate breast cell growth. Another factor is that of host resistance and the immunopathology of the regional nodes; if there is evidence of an inflammatory response in the regional lymph nodes or in the breast tissue itself, there may be a

Table 1. Breast cancer

Prognostic factors
1. Stage of the disease
2. Histologic type of tumor
3. Immunochemistry of tumor
4. Immunopathology of regional nodes
5. Age and menstrual status of patient
6. Size of the primary lesion
7. Location in the breast
8. Duration of the mass
9. Extent of operation
10. Effect of adjuvant therapy

greater degree of host resistance to the tumor. The age of the patient may be of importance. It has been observed that some young, actively menstruating women with breast cancer have either a more aggressive cancer or decreased host resistance. The size of the primary lesion is important. Lesions less than 4 cm are more favorable than lesions larger than 4 cm. The location of the tumor in the breast may be of importance. A lesion in the axillary tail of the breast, which would metastasize first to axillary nodes, is a more favorable tumor than one that is central or in the medial portion of the breast, which may metastasize to internal mammary nodes.

Finally, how important is the extent of the operation? This is the factor that all surgeons discuss, and this is what a number of prospective study groups are now trying to determine.

With the advent of xeromammography, we are now finding lesions in the breast that cannot be palpated. We now have the capability of detecting small, early lesions prior to any clinical evidence of a mass. *Figure 1* shows a breast with a very small lesion which could not be palpated. This is the only lesion seen in the breast tissue. When biopsy of the lesion was performed, a specimen radiogram was obtained to be certain that the lesion had been removed (*Fig. 2*). This small carcinoma is one that could be treated by a partial mastectomy.

A word about biopsy techniques. More and more frequently we are using needle aspiration cytology in patients, especially those with an obvious carcinoma of the breast, to make the diagnosis by a cytologic smear in advance of the patient's admission to

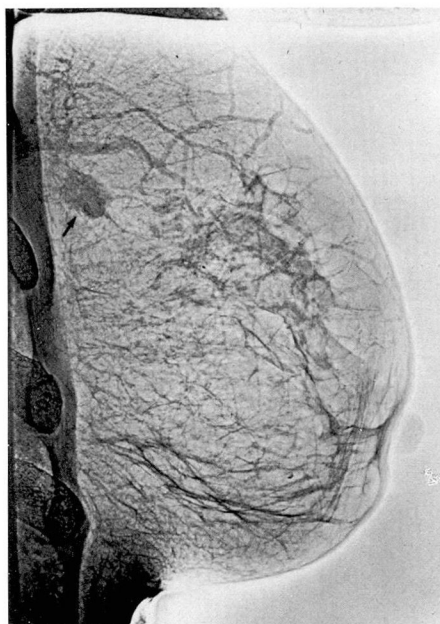

Fig. 1. Xeromammogram showing a small lesion not clinically palpable.

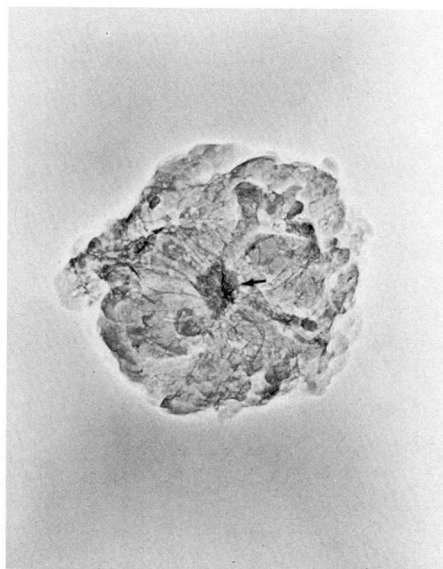


Fig. 2. Xerogram showing the biopsy specimen.

Table 2. Operations for breast cancer, Cleveland Clinic, 1957-1968

	No. of patients	%
Radical mastectomy	4	1
Modified radical mastectomy	303	49
Total mastectomy	247	39
Partial mastectomy	70	11
Total	624	100

the hospital. For many patients, in whom the cytologic slide shows obvious carcinoma cells and in whom the clinical examination and xeromammogram both confirm the presence of cancer, we have performed some form of mastectomy without a formal biopsy. If the cytologic smear is equivocal or if the clinical or roentgenographic examination does not support the diagnosis of carcinoma, then a formal biopsy is performed prior to mastectomy.

When the patient has a small or benign appearing lesion, we frequently perform a biopsy under local anesthesia, as an ambulatory surgical procedure. The patient comes in the morning as an outpatient, goes into the operating room, and under local anesthesia has the small lesion excised. If the lesion is benign, she can go home. The woman is less frightened by the biopsy procedure and is not subjected to hospitalization or to a major anesthetic. If the lesion is a carcinoma, we will plan to admit the patient for mastectomy 2 to 10 days later. This gives us the opportunity to get fixed pathologic sections of the lesion and to classify the histologic type. If a xeromammogram has not been obtained previously, it is now

obtained in all patients. We discuss with the woman and her husband the choice of operation. At the time of mastectomy, one has a sealed wound which is not draining and possibly spreading cancer cells.

The operations performed at the Cleveland Clinic during the 11-year period from 1957 to 1968 are listed in *Table 2*. During that time, 765 patients were examined; 624 patients (82%) were in operable Stages I and II. We have now essentially abandoned the standard radical mastectomy, although if the patient has a deep lesion in the breast, we may remove some of the pectoralis major along with the tumor to be certain that there is good clearance around a deep-seated lesion. Forty-nine percent of our patients had modified radical mastectomies, 39% had complete mastectomies, and 11% had partial mastectomies. In recent years, the number of partial mastectomies has increased slightly because more women have heard about partial mastectomies and are requesting a breast sparing operation for cancer if at all possible.

How do we decide on the operative procedure? I recommend a modified radical mastectomy for any woman in whom the lesion is larger than 4 cm or in whom axillary nodes are positive either by clinical or by intraoperative staging. I recommend a total mastectomy for patients in whom the lesion is less than 4 cm, in whom the axillary nodes are negative by palpation and biopsy at the time of surgery, and in whom the lesion is either central in the breast or of a histologic type associated with a high degree of multicentricity, such as lobular or intraductal carcinoma. Finally, a partial mastectomy can be performed in

women who have peripheral lesions, smaller than 2 cm, and not multifocal by either xerographic study or by histologic type. We perform a partial mastectomy only after explaining and discussing the procedure with the patient and her husband; they must both wish to have a breast sparing operation and must understand that it has not been as widely tested as the standard mastectomies.

Both the modified radical and total mastectomies remove all of the breast; the procedure and cosmetic results are similar. We prefer transverse incisions because the results are more cosmetic. We advise healthy, reasonably thick skin flaps with a good blood flow. We do not like flaps that turn blue during the postoperative period, not only because of the delayed healing and potential necrosis of the skin, but also because of the evidence from the studies of Fisher and Fisher² and Fisher et al³ that an ischemic area will take up implantation of circulating tumor cells more rapidly than healthy tissue.

When we divide the clavipectoral fascia, we palpate the axilla and biopsy the nodes adjacent to the breast. If the nodes are negative histologically, we leave the axilla intact and perform a total mastectomy. If the nodes are positive, we perform a modified radical mastectomy, removing both the breast and the entire axillary contents. The cosmetic results of a modified radical mastectomy or a total mastectomy are superior to a standard radical mastectomy (Figs. 3 and 4).

Figure 5 shows the incisions which can be used for partial mastectomy. With an upper outer quadrant lesion, we have occasionally performed an axillary dissection if axillary nodes

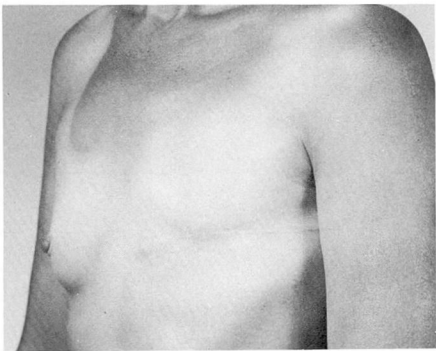


Fig. 3. A patient after a left modified radical mastectomy.

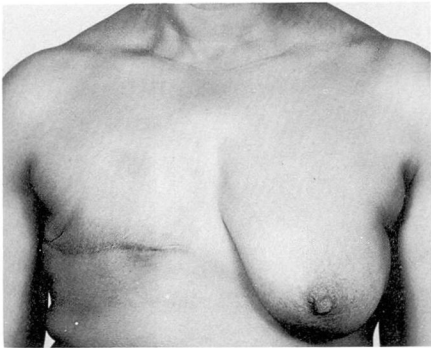


Fig. 4. A patient after a right total mastectomy.

were involved, even though the primary lesion in the breast appeared to be small and favorable. We remove about 30% of the breast tissue when we do a partial mastectomy. The cosmetic results of partial mastectomy can be excellent (Figs. 6 and 7).

Our 5- and 10-year survival results are listed in Table 3 and are compared to the follow-up results of the Cancer Registry in End Results in Cancer, no. 4, which records results during a time period comparable to ours, 1955 to 1964.⁴ This Cancer Registry included six university hospitals and three state registries in the United States. Most of the patients in the Cancer Registry

had the standard radical mastectomy. In comparing this report with ours, we found that the survival statistics of

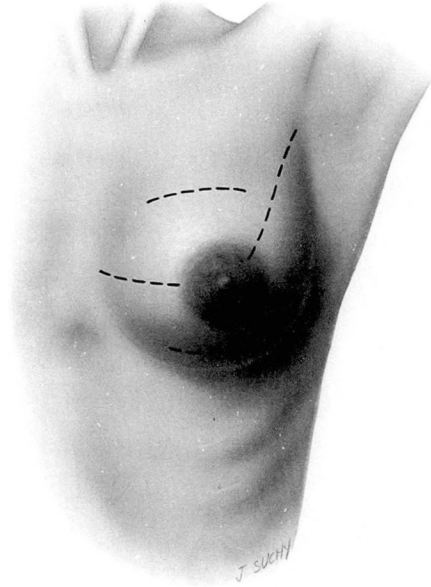


Fig. 5. Drawing which shows the incisions used for partial mastectomy.

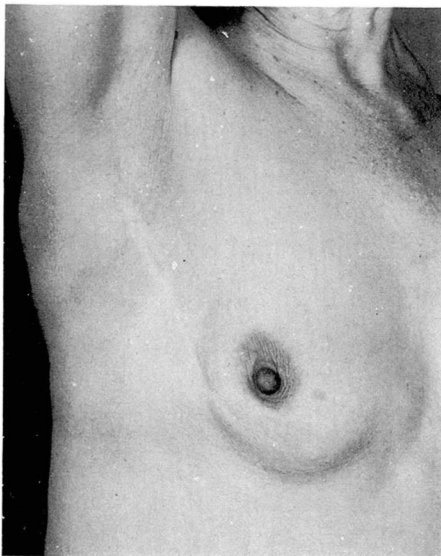


Fig. 6. A patient after a right partial mastectomy of the upper outer breast.

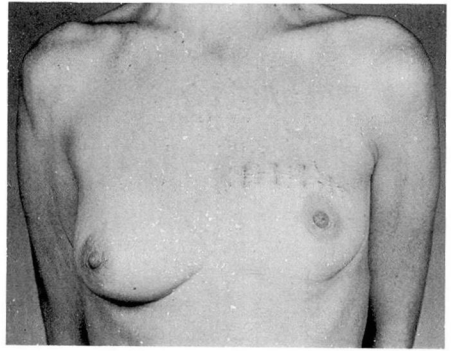


Fig. 7. A patient after a left partial mastectomy of the upper central breast.

patients at 5 and 10 years were very comparable; but more important, the proportion of patients in Stages I and II was identical.

The follow-up on patients who have had partial mastectomies so far is good (Table 4).^{5, 6} Although limited in number, this group is being followed closely. The incidence of recurrent cancer in the treated breast as compared to new cancers in the opposite breast will be watched carefully, because of the incidence of multicentricity which has been reported by some; this incidence is about 7% at the present time. Because of the cosmetic advantage, we continue to think that there is a place for partial mastectomy in highly selected patients.

Summary

We believe that surgeons can be selective in their choice of operative procedures for breast cancer with the aim of removing all local and regional disease, yet preserving cosmetic appearance and function. Our 5- and 10-year survival results with selective, conservative operations for breast cancer are equal to those reported by the Cancer Registry of the National Cancer Institute in patients treated pre-

Table 3. Comparison of survival and staging, Cleveland Clinic, 1957–1963; Cancer Registry, 1955–1964^a

Survival	Cleveland Clinic		Cancer Registry	
	5 yr %	10 yr %	5 yr %	10 yr %
Clinical Stage I	79	56	73	55
Clinical Stage II	61	25	47	29
Clinical Stages I and II	71	42	61	43
Clinical Stages III and IV	14	0	12	0
Proportion Stage I	53		53	
Proportion Stage II	47		47	

Table 4. Results of partial mastectomy, 1957–1963 (42 patients)

	5 yr		10 yr	
	No. of patients	%	No. of patients	%
Survival	31/42	74	17/42	40
Recurrent carcinoma; same breast	3/42	7		
Carcinoma; opposite breast	2/42	5		

dominantly by standard radical mastectomy. The cosmetic results of conservative operations are superior to those of the more radical mastectomies.

References

1. Urban JA, Castro EB: Selecting variations in extent of surgical procedure for breast cancer. *Cancer* 28: 1615–1623, 1971.

2. Fisher B, Fisher ER: Experimental studies of factors influencing hepatic metastases. III. Effect of surgical trauma with special reference to liver injury. *Ann Surg* 150: 731–744, 1959.

3. Fisher B, Fisher ER, Feduska N: Trauma and the localization of tumor cells. *Cancer* 20: 23–30, 1967.

4. Axtell LM, Cutler SJ, Myers MH, eds: Female breast. End results in cancer, report no. 4. DHEW Publication No. (NIH) 73-272, pp 99–103. Bethesda, Md. US Department of Health, Education, and Welfare, Public Health Service, National Institutes of Health, National Cancer Institute, 1972.

5. Crile G Jr: Results of conservative treatment of breast cancer at ten and 15 years. *Ann Surg* 181: 26–30, 1975.

6. Crile G Jr, Esselstyn CB Jr, Hermann RE, et al: Partial mastectomy for carcinoma of the breast. *Surg Gynecol Obstet* 136: 929–933, 1973.