

# Hematogenous osteomyelitis

## *A changing disease*

Martin C. McHenry, M.D.

*Department of Infectious Diseases*

Ralph J. Alfidi, M.D.

*Department of Radiology*

Alan H. Wilde, M.D.

*Department of Orthopaedic Surgery*

William A. Hawk, M.D.

*Department of Pathology*

Despite the availability of potent antimicrobial drugs, improved diagnostic techniques, and effective surgical procedures, hematogenous osteomyelitis continues to provide difficulties in diagnosis, complex problems in management, serious morbidity and even mortality. In recent years, changes have occurred in the clinical setting, presenting manifestations and the types of causative microorganisms.<sup>1, 2</sup> Microorganisms that rarely caused infection in the past have emerged as significant bone pathogens. New clinical syndromes, unusual locations of bone infection, and additional pathogenetic mechanisms have been documented. Although chronic osteomyelitis has long been known to be a difficult lesion to produce in laboratory animals, recent experimental models of chronic osteomyelitis that mimic human disease have been devised.<sup>3-7</sup> New information is available concerning defects in host resistance which may predispose to some forms of osteomyelitis. Furthermore, knowledge of some of the microbial factors related to virulence of certain bone pathogens is increasing. The purpose of this report is to review briefly, in view of current developments, selected aspects of the problem of hematogenous osteomyelitis.

### **General considerations**

Given the appropriate predisposing factors, osteomyelitis may develop in any bone of the body. In the human skeleton, at least 206 bones develop

which vary in location, size, shape, structure, and function. In general, bones are composed of a cortex of compact (lamellar) bone and a medulla of spongy or cancellous bone. With respect to general architecture, Jaffe<sup>8</sup> has grouped bones into four categories: (1) tubular (long and short), (2) short (cuboidal), (3) flat, and (4) irregular. The tubular bones include the humerus, radius, ulna, femur, tibia, fibula (the long tubular bones), metacarpals, metatarsals and phalanges (short tubular bones). The shaft of a tubular bone consists of a cortex of compact osseous tissue surrounding loosely meshed cancellous tissue of the bone marrow cavity; in the midportion of the shaft (diaphysis), the cortex is thickest and there is the least amount of cancellous osseous tissue. The short (cuboidal) bones comprise the carpals, tarsals, sesamoids, and certain anomalous bones. The bulk of the short bones is composed of spongy osseous tissue, and where they are not covered by articular cartilage they are enclosed only by a thin cortical shell. The flat bones comprise the ribs, sternum, scapulae, and many of the bones of the skull. These bones are thin in part or throughout, are composed primarily of cortical bone, and contain relatively little spongy bone. The irregular bones include the innominate (ilium, ischium, pubis), the vertebrae, and some of the bones of the skull. These bones are classified as irregular because they do not qualify for inclusion in the first three categories. Some of the irregular bones may have the characteristics of more than one of those in the first three categories. For example, the body of a vertebra resembles that of a short

bone, while much of the arch has the configuration of a flat bone.<sup>8</sup>

Although bone is the most solid of the organs of the body, it is permeated with a system of channels that may provide a reservoir for pathogenic microorganisms—lacunae, canaliculae, Haversian or Volkmann's canals, and the medullary cavity.<sup>9-11</sup>

### Pathogenesis

Microorganisms may reach bone by one of three mechanisms: (1) direct inoculation secondary to trauma or surgery, (2) contiguous spread from an adjacent soft-tissue infection, or (3) hematogenous spread from a distant focus of infection. We will confine our remarks to the latter mechanism.

Collins<sup>9</sup> and Kahn and Pritzker<sup>10</sup> have emphasized some special characteristics of bone relevant to pyogenic bacterial infection. These include a relatively small volume of tissue space surrounded by a rigid wall favoring the accumulation of exudate under increased tension; an anatomical arrangement of blood vessels that favors massive bone necrosis in association with increased tissue pressure; an inadequate mechanism for resorption of necrotic bone, which can lead to incomplete healing and recurrent infection; and the capacity for reactive ossification which may take place readily in fibroblastic granulation tissue of walls of abscesses.

### Acute hematogenous osteomyelitis

*Table 1* lists the site of bone involvement in 1,865 patients with acute hematogenous osteomyelitis gathered from several reports of studies conducted in the preantimicrobial,<sup>12-14</sup> and in the antimicrobial era.<sup>14-22</sup> The

**Table 1.** Site of bone involvement in acute hematogenous osteomyelitis based on review of studies conducted at various time periods<sup>12–22</sup>

Time of studies	1919–1937	1924–1954	1948–1968
Number of patients	846	99*	911
Bones involved			
Femur	207 (24.4%)	29 (29.3%)	323 (35.5%)
Tibia	214 (25.3%)	28 (28.2%)	293 (32.2%)
Humerus	76 (8.9%)	20 (20.2%)	95 (10.4%)
Foot	61 (7.2%)	17 (17.1%)	52 (5.7%)
Calcaneous	29	4	24
Other tarsals	19	3	7
Metatarsals	13	6	6
Phalanges			
Unspecified			
Skull	59 (7%)	6 (6%)	3 (0.3%)
Mandible	18		2
Frontal	13	4	
Maxilla	12		
Temporal	5		
Cranium	4		1
Nasal	2		
Sphenoid	2		
Malar	1		
Basiooccipital	1		
Parietooccipital	1		
Occipital		1	
Parietal		1	
Pelvis	58 (6.9%)	11 (11.1%)	38 (4.2%)
Ilium		7	16
Ischium		2	8
Pubis		2	7
Unspecified	58		7
Fibula	51 (6%)	10 (10.1%)	61 (6.7%)
Radius	29 (3.4%)	5 (5%)	29 (3.2%)
Ulna	19 (2.2%)	9 (9.1%)	22 (2.4%)
Clavicle	11 (1.3%)	5 (5%)	8 (0.9%)
Rib	11 (1.3%)	6 (6.1%)	7 (0.8%)
Patella	6		4
Scapula	6	3	1
Metacarpal	6		
Carpal	3		
Sternum	1		2
Phalanx-hand		5 (5%)	1
Phalanges unspecified	31 (3.7%)		
Unspecified bones			10 (1.1%)
Multiple bony involvement	45 (5.3%)	24 (24%)	45 (4.9%)

\* Of the 99 patients, in 57, osteomyelitis was diagnosed before 1939.

data are arbitrarily arranged into three time periods because one of the studies<sup>14</sup> overlapped the preantimicro-

bial and antimicrobial era. *Table 2* lists other data from these studies. Acute hematogenous osteomyelitis is

**Table 2.** Selected features of acute hematogenous osteomyelitis based on review of studies conducted at various time periods<sup>12-22</sup>

Time of studies	1919-1937	1924-1954	1948-1968
Number of patients	846	99*	911
Age of patients	<21 yr (75%)	<15 yr (100%)	<21 yr (81-100%)†
Male/female‡	584/262	58/41	503/253
Pathogens§			
<i>Staphylococcus aureus</i>	418/560 (75%)	62/86 (72%)	567/672 (84%)
<i>Streptococcus pyogenes</i>	75/560 (13.4%)	18/86 (20.9%)	28/672 (4.2%)
Gram-negative bacilli	7/560 (1.3%)	3/86 (3.4%)	16/672 (2.4%)
Mortality	12%-25.4%	21.2%	1%
Some complications (survivors)			
Relapse or chronic osteomyelitis	23%-46%	28.2%	20%
Adjacent pyoarthrosis	18.7%	1%	5.7%
Pathologic fracture	0.4%	? 2%	1%
Amyloidosis	0.4%		

\* Of the 99 patients, in 57, osteomyelitis was diagnosed before 1939.

† Ages not reported in one study of 110 patients.

‡ Sex not reported in two studies (155 patients).

§ Based upon the number of cases in which the infecting organism was determined.

caused most frequently by *Staphylococcus aureus* or by Group A streptococci. It occurs most frequently in long tubular bones, but no bone is exempt. The majority of cases of acute hematogenous osteomyelitis occur in children before the age of puberty; the initial lesion is usually located in the metaphyseal sinusoidal veins of the red bone marrow of long bones.<sup>9, 13, 23-25</sup> The term metaphysis was first used by Kocher to denote the broad cancellous end of the bone shaft which is adjacent to the epiphyseal growth plate.<sup>26</sup> Branches of the nutrient artery end in the metaphysis as narrow capillaries, which turn back on themselves in acute loops at the growth plate, and enter a system of large sinusoidal veins leading to the sinusoids of the bone marrow.<sup>23, 25</sup> At this point, blood flow slows,<sup>25</sup> presumably allowing bacterial emboli to settle and initiate the inflammatory process. The sinusoids of the metaphyseal bone marrow are said to have a paucity of

phagocytes which may also favor development of infection in that region.<sup>26</sup>

Initially, the acute inflammatory process behaves as a cellulitis of the bone marrow; it may be amenable to appropriate antimicrobial chemotherapy and resolve with minimal or no destruction of bone. When the infection is uncontrolled, there is necrosis of marrow, osteocytes, and trabecular bone. Abscesses form, and tiny sequestra of necrotic trabeculae remain in a pool of purulent exudate.<sup>9</sup>

Accumulation of exudate under pressure results in spread of the infection in the medullary cavity and into the cortex through the Haversian and Volkmann's canals. In infants less than 1 year of age, nutrient metaphyseal capillaries may still perforate the epiphyseal growth plate; the infection may spread to affect the epiphysis and the adjacent joint. In children more than 1 year of age, the epiphyseal circulation is separated from the vascular

system of the metaphysis by an avascular barrier, the epiphyseal growth plate.<sup>25, 26</sup> The epiphyseal growth plate acts as a barrier to spread of infection, preventing epiphysitis and infection of the adjacent joint.<sup>25</sup> The infection spreads laterally through the cortical canals; this causes ischemia and focal necrosis of cortical bone nourished by blood vessels in the Haversian and Volkmann canals. Subperiosteal infection follows escape of the exudate through the cortex in the region of the metaphysis, probably because the cortical bone of the metaphysis is thinner than that of the diaphysis.<sup>27</sup> In children, the periosteum is loosely attached to bone and may become elevated by subperiosteal abscesses. This, in turn, may cause disruption of periosteal blood vessels that supply the underlying cortical bone and infarction of large portions of the cortex, resulting in the formation of very large bony sequestra. Eventually these sequestra become separated from viable bone and are surrounded by purulent exudate. If the patient survives, fibrous tissue and new bone may be produced in the medullary cavity and subperiosteal new bone (involucrum) will be formed.<sup>10</sup>

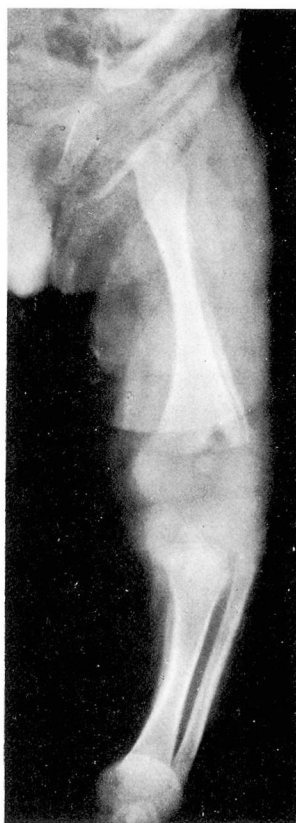Bacteria invade the bony substance of nearly all sequestra and remain there as long as the sequestra persist.<sup>28</sup> Sequestra serve as a potential source for reinfection because they have no blood supply, and neither antimicrobial drugs nor antibodies penetrate well into them.<sup>10, 29</sup>

When exudate perforates through the periosteum, subcutaneous abscesses and chronic draining sinuses develop. In joints such as the hip or shoulder, where the joint capsule surrounds a portion of the metaphysis,

direct involvement of the joint may develop from extension of the metaphyseal infection through the periosteum without passage through the epiphyseal cartilage.<sup>27</sup>

Pyoarthrosis of an adjacent joint is a relatively frequent complication of acute hematogenous osteomyelitis even in the antimicrobial era (*Table 2*). It most frequently involves the hip, shoulder, or knee; but other joints may be involved.

*Figure 1* is a roentgenogram of the



**Fig. 1.** Roentgenogram of the left femur and tibia-fibula of a 5-week-old infant, revealing soft tissue swelling about the knee, a radiolucent defect in the metaphyseal region of the distal femur, and periosteal elevation and new bone formation on the lateral aspect of the femur and medial aspect of the tibia.

left femur and tibia-fibula of a 5-week-old infant taken on the day of admission for acute hematogenous osteomyelitis. This infant had evidence of osteomyelitis of the femur and tibia as well as infection of the knee joint. A hemolytic streptococcus was isolated from the knee joint. This patient illustrated many of the unique features of neonatal hematogenous osteomyelitis.<sup>27, 30-32</sup> Pyoarthrosis and multiple bone involvement are more common in hematogenous osteomyelitis in neonates than in older infants and children.<sup>25, 27, 30</sup> Although the long tubular bones are most frequently involved in neonates,<sup>33</sup> there is an increased incidence of involvement of membranous bones such as the maxilla.<sup>31, 32</sup> Systemic manifestations frequently are minimal or absent despite multiple bony involvement. The most common presenting problem is swelling and pain or loss of movement of an extremity. If the epiphysis and joints are not involved in the neonate and bacteremia is controlled, prognosis for recovery without sequestrae is unusually good. Sequestra, chronic infection, and draining sinuses rarely develop after hematogenous neonatal osteomyelitis.<sup>27, 31</sup> Although there is considerable roentgenographic evidence of periosteal reaction, infarction of the bony cortex does not occur.<sup>25, 34</sup>

Certain anatomic factors appear to contribute to the different nature of the disease in neonates.<sup>27</sup> The cancellous spaces of the metaphysis are larger, the bone is of a more spongy texture, the cortex is thinner, and the periosteum is more loosely attached to bone of neonates than in older infants and children.<sup>25, 27</sup> This allows the infection to pass more easily from the medulla to the cortex and to the sub-

periosteal space. The periosteum may rupture early with the formation of soft tissue abscesses. This rapid decompression prevents the vascular phenomena which are responsible for bony infarction and sequestra formation in older infants and children.

Qureshi and Puri<sup>35</sup> reported the occurrence of hematogenous osteomyelitis in two infants after umbilical catheterization for exchange transfusion and were unable to find similar cases reported in the literature. On the other hand, umbilical infection has appeared to be an important predisposing factor to neonatal osteomyelitis in some series,<sup>34</sup> but not in others.<sup>30</sup> Respiratory and cutaneous infections have also been found to be important predisposing factors in many cases. In some series, group A streptococci have been the most frequent causative organisms,<sup>27, 34</sup> whereas in others staphylococci predominate.<sup>30, 32, 33</sup>

In the preantimicrobial era, acute hematogenous osteomyelitis was uncommon in adults.<sup>24</sup> When it occurred, it usually involved the vertebrae, presumably because they are one of the most active sites of hematopoiesis in adults.<sup>36</sup> Acute hematogenous osteomyelitis of long bones in adults appears to be extremely rare,<sup>36, 37</sup> probably because the marrow cavities of the limbs in adults are filled with adipose tissue, with the exception of tiny foci of red marrow in the extreme proximal portions of the humeri and femora. Zadek<sup>37</sup> and Wiley and Trueta<sup>36</sup> reported a total of 22 cases of acute hematogenous osteomyelitis in long bones of adults. Recently King and Mayo<sup>38</sup> described the findings in six additional cases. The lesion usually begins around the nutrient artery

in the diaphysis of long bone.<sup>38</sup> The pathologic changes are principally periosteal and central.<sup>37</sup> When the infection is uncontrolled, the suppurative process spreads primarily through marrow cavity. Because the periosteum is more firmly adherent to the adult bone, subperiosteal abscess formation occurs less frequently than in children; the large cortical sequestra of osteomyelitis in children do not develop in the long bones of adults. When the infection progresses to the end of the long bone of adults, neighboring joints may become involved.

Figure 2 shows the excretory urogram of a diabetic woman with a solitary, mildly hydronephrotic kidney and a functioning uretersigmoidostomy. A Charnley-Mueller prosthesis had been inserted in the right hip because of disabling osteoarthritis. Several days postoperatively, a rectal tube was required and severe rectal bleeding developed. This was followed by bacteremia due to *Klebsiella* type 32, probably arising from infection of the urinary tract. This in turn, was complicated by *Klebsiella* type 32 infection of the hip and femur, which progressed to involve the entire femur and the right knee joint (despite appropriate therapy). Figure 3 shows the lateral roentgenogram of the femur taken 24 days after the onset of bacteremia and before pyoarthrosis of the knee was evident clinically. There was gas in the tissues of the thigh and evidence of extensive osteomyelitis of the femur.

In 1966, Smith<sup>39</sup> reported a case of acute hematogenous *Klebsiella* osteomyelitis of the femur in an adult; his search of the literature produced only nine other reported cases of acute hematogenous osteomyelitis caused by

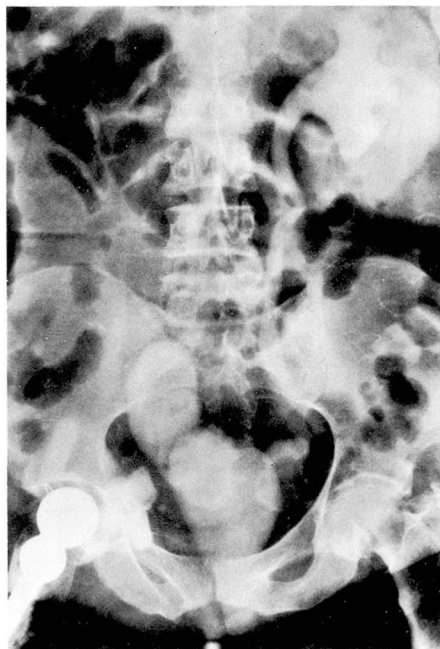


Fig. 2. Intravenous urogram revealing a solitary, mildly hydronephrotic kidney and a functioning uretersigmoidostomy; a Charnley-Mueller prosthesis is present in the right hip.

*Klebsiella*. In each of the cases, the femur was involved. The association of this type of hematogenous osteomyelitis with urologic procedures or pelvic operations was emphasized.<sup>39</sup> Recently, Irvine et al<sup>40</sup> and Hall<sup>41</sup> have noted an association between genitourinary tract infections and deep infections after total hip or knee replacements. All of the serious infections reported by those physicians were caused by enteric gram-negative bacilli.

Since 1944, the incidence of acute hematogenous osteomyelitis of children has been decreasing.<sup>1</sup> In some medical centers, the relative proportion of cases caused by *S. aureus* has diminished;<sup>1</sup> however, the staphylococci that cause disease have become

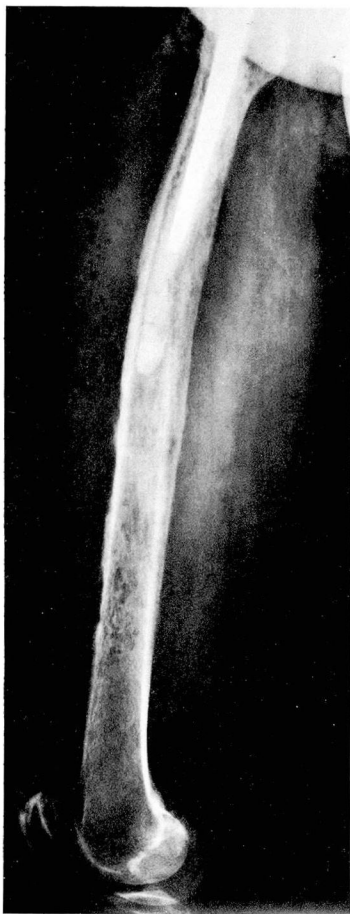

Fig. 3. Lateral roentgenographic view of the right femur from the same patient as in *Figure 2*, taken 24 days after the onset of *Klebsiella* type 32 bacteremia. There is gas in soft tissues. The bony cortex is thinned and eroded and there are focal areas of periosteal reaction.

increasingly resistant to antibiotics.<sup>42</sup> Gram-negative bacilli have been cited more frequently as being bone pathogens.<sup>1, 43</sup> In a recent study from Australia,<sup>44</sup> gram-negative bacilli accounted for 8% of cases of acute hematogenous osteomyelitis, which is considerably higher than that recorded in previous years (*Table 2*).

There are also indications that the type of clinical illness associated with

acute hematogenous osteomyelitis of children has changed since the advent of antibiotics.<sup>1, 2, 38, 45-47</sup> More severe forms of the disease were observed in the preantimicrobial era when the mortality rate was as high as 25% (*Table 2*). Severe shaking chills, fever, and bone pain were characteristic; death usually could be attributed to septicemia and, in about two thirds of the patients, occurred within 2 weeks of the onset of the illness.<sup>13</sup> After 1944, the mortality fell to 1% or less. Furthermore, the fulminating type of infection is now rarely seen and the incidence of acute systemic illness with the disease has diminished.<sup>1, 2, 38, 45-47</sup> The onset of the illness is more frequently gradual and insidious, bone lesions remain localized and may be mistaken for benign or malignant tumors or other conditions.

Before the introduction and use of antimicrobial drugs, hematogenous osteomyelitis of the spine was considered an uncommon condition.<sup>13</sup> In the last 3 decades, the incidence appears to have increased.<sup>1</sup> Hematogenous spinal osteomyelitis is a disease primarily of adults; the majority of cases occur after the third decade of life, when the spine is completely formed.<sup>48</sup> According to Kulowski,<sup>48</sup> the predilection for hematogenous osteomyelitis to involve vertebrae of adults (in contrast to osteomyelitic involvement of long tubular bones in children) may be attributed in part to lack of true epiphyseal growth of vertebrae, persistence of rich, cellular, red bone marrow, and a sluggish voluminous blood supply. The latter condition might favor localization of bacteria in the vertebral body.

*Table 3* lists some of the pertinent features of hematogenous osteomyelitis

**Table 3.** Nontuberculous hematogenous osteomyelitis of the spine of adults: selected features based on review of reported cases<sup>36, 49-57</sup>

Number of patients	86	
Age range, yr	26-79	(mean 58.6 yr, ±11.3 SD)
Men/women	56/30	
Antecedent urinary tract or pelvic infection	38	44.2%
Pathogen*		
<i>Staphylococcus aureus</i>	28/55	50.9%
Gram-negative bacilli	17/55	30.9%
Streptococci	4/55	7.3%
Mortality from infection	5/86	5.8%
Complications		
Paralysis	7/86	8.1%
Temporary	5	
Permanent	2	
Paravertebral abscess	6/86	6.9%
Epidural abscess or granuloma	5/86	5.8%
Retropharyngeal abscess	2/86	2.3%
Endocarditis	2/86	2.3%
Vertebra involved		
Cervical	8	
Thoracic	35	
Thoracolumbar	2	
Lumbar	35	
Lumbosacral	7	
> 1 interspace	9	

\* Based upon the number of cases in which a pathogen was isolated from the involved bone or blood or both.

of the spine in 86 adult cases gathered from several reports in the literature.<sup>36, 49-57</sup> Data from other reports<sup>1, 48, 58-60</sup> were not included because it was not always possible to separate adult from childhood cases, to differentiate between cases caused by hematogenous spread from those produced by other mechanisms, or to tabulate all the bones involved.

*S. aureus*, various enteric gram-negative bacilli, and streptococci are most frequently responsible for hematogenous spinal osteomyelitis in the adult (Table 3). Infections of the urinary tract or pelvis, particularly those developing after a surgical or instrumental procedure, appear to be im-

portant predisposing factors in more than 40% of the cases. Organisms may reach the spine directly through the nutrient branches of the posterior spinal artery during bacteremia<sup>36</sup> or by retrograde spread through the paravertebral venous plexus of Batson. According to Wiley and Trueta,<sup>36</sup> the earliest lesion is in the body of the vertebrae close to the anterior longitudinal ligament. The lesion spreads across the periphery of the intervertebral disc in a system of freely anastomosing venous channels to involve the body of the adjacent vertebrae. More than one vertebral body is involved as a rule, at least in the later stages of the disease. Extension to the contigu-

ous disc and vertebral body is abetted by the absence of a circumferential cartilaginous plate and the lack of definite protective subchondral layer of compact bone.<sup>48</sup> Rapid progression of the infection in the spongy vertebral bone and in the intervertebral disc may cause significant destruction of these structures.

The lumbar vertebrae are involved most commonly by hematogenous osteomyelitis, followed in order of frequency by the thoracic and cervical vertebrae. Extension of infection anteriorly to the spine occurred commonly in the preantibiotic era.<sup>48</sup> Depending upon the location, anterior extension of infection may cause a retropharyngeal abscess, mediastinitis with pleural or pericardial involvement, subphrenic and retroperitoneal abscess, or a psoas abscess. The tendency of these abscesses to gravitate or migrate is well known.

The infection may also extend posteriorly and invade the spinal canal causing an extradural abscess or granuloma; this may lead to compression of the spinal cord and paralysis. When the infection perforates the dura, meningitis results. There were no examples of meningitis in the 86 cases included in *Table 3*, but meningitis developed in four patients in Kulowski's<sup>48</sup> series and in one patient in the series of Waldvogel et al.<sup>1</sup> One of the goals of antimicrobial chemotherapy for vertebral osteomyelitis is to try to prevent extension of the process and associated complications.

Because vertebral osteomyelitis may be produced by a wide variety of organisms, we routinely recommend obtaining material from the involved bone or interspace for smears and cultures for aerobes, anaerobes, acid-fast

bacilli, and fungi. This can be accomplished either by percutaneous (Craig needle) biopsy under fluoroscopic control or by open surgical biopsy when this seems indicated. It is extremely important to remember to obtain cultures for acid-fast bacilli because it may be difficult or impossible to differentiate tuberculous from pyogenic infection of the spine (*Fig. 4A, B*).

Positive blood cultures usually establish the cause of hematogenous vertebral osteomyelitis, but rarely they may be misleading. For example, during our study of gram-negative bacteremia,<sup>72</sup> we treated a patient with recurrent urinary tract infection and *Proteus mirabilis* bacteremia at the time when signs, symptoms, and roentgenographic changes of vertebral osteomyelitis and disc-space infection were evolving. Culture of the affected vertebral interspace yielded *Mycobacterium tuberculosis* rather than *P. mirabilis*. Thus, whenever possible, culture of the involved bone or interspace should be obtained.

More recently, new pathogenic mechanisms for acute hematogenous osteomyelitis in adults have been described. Since 1971, 59 cases of acute hematogenous osteomyelitis have been reported in adults who are addicted to or abuse drugs by taking them intravenously.<sup>61-69</sup> Pertinent clinical and microbiologic data from those 59 patients are summarized in *Table 4*. Most of the patients were heroin addicts who took the drug intravenously. Each of the patients complained of pain, but most were remarkably free of systemic illness. Vertebrae and pelvic bones were most frequently affected, but a wide variety of other bones and joints were involved in some patients. Diagnosis frequently was

delayed and initially mistaken for other conditions. *Pseudomonas aeruginosa* and other gram-negative bacilli were the pathogens in the majority of cases. Of the 59 patients, only two had endocarditis and there were no deaths reported.

Leonard et al<sup>70</sup> reported the development of acute hematogenous osteomyelitis in five patients receiving intermittent hemodialysis for chronic renal failure. Of the five patients, in four, repeated intravenous cannula infections occurred and *Staphylococcus epidermidis* and *S. aureus* were cultured from the blood on different occasions. The fifth patient had a subcutaneous arteriovenous fistula and the source of osteomyelitis was not defined. Staphylococci were the most common etiologic organisms, but *P. aeruginosa* was the pathogen in one patient. The thoracic spine and ribs were the bones most commonly involved, but the tibia, toes, and clavicle were affected in some patients. One patient had bacterial endocarditis. The overall mortality was 60%.

In 1974, we treated a patient with chronic renal failure (who was being maintained on intermittent hemodialysis) for an infected subcutaneous arteriovenous fistula and bacteremia caused by *S. aureus*. Bacteremia was eradicated promptly and appropriate antimicrobial therapy was administered for an extended period of time. Figures 5 to 7 are roentgenograms of the thoracic spine taken 50, 63, and 83 days after the day of staphylococcal bacteremia. Needle biopsy and aspiration of the interspace between the 11th and 12th thoracic vertebrae was performed on the 74th day after the day of bacteremia; the culture yielded *S. aureus*, despite the fact that therapeutic

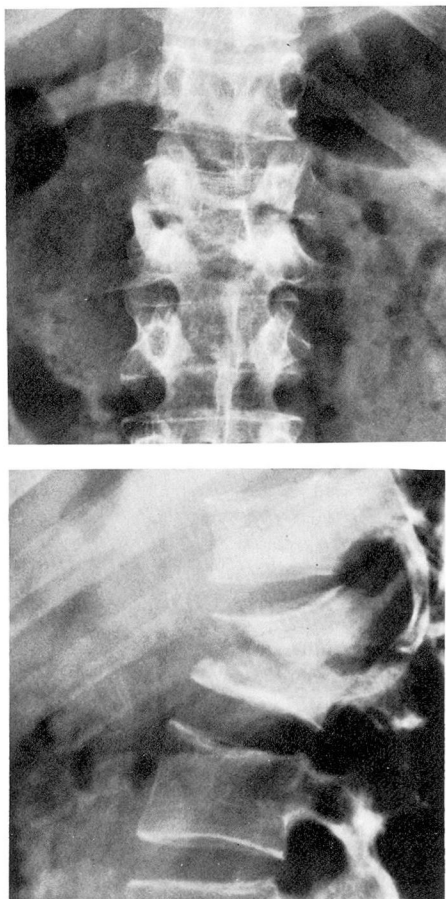


Fig. 4A, B. Posteroanterior and lateral roentgenograms of the thoracolumbar region showing evidence of destruction of large portions of the bodies of the first and second lumbar vertebrae and collapse of the intervertebral disk space. *Mycobacterium tuberculosis* was cultured from specimens obtained by aspiration biopsy of the affected area. The patient recovered after a long course of antituberculous therapy.

tic levels of vancomycin had been present in the blood for several weeks. Because of the patient's cachectic state and hopeless prognosis, surgery to relieve the spinal cord compression was not undertaken and hemodialysis was discontinued at the request of his family. The patient died from his under-

**Table 4.** Selected features of acute hematogenous osteomyelitis in drug addicts or abusers based on review of reported cases (1971–1974)<sup>61-69 \*</sup>

Number of patients	59
Age	18–50 yr (mean 33 yr ± 8.9 SD)
Sex	Man/woman = 50/9
Pathogen(s)†	
<i>Pseudomonas aeruginosa</i>	47
<i>Pseudomonas aeruginosa</i> and other pathogen(s)‡	3
Klebsiella (3)—Enterobacter (1)	4
<i>Pseudomonas</i> sp	2
<i>Candida stellatoidea</i>	1
<i>Candida guilliermondi</i>	1
<i>Staphylococcus aureus</i>	1
Bone and joints involved	
Vertebra	40
Cervical	7
Thoracic	2
Lumbar	22
Lumbosacral	8
Nonspecified	1
Sacroiliac	5
Symphysis pubis	4
Radial styloid	4
Sternoclavicular	4
Ischium	2
Humerus	2
Rib(s)	2
Hip	2
Femur	1
Clavicle	1
Scapula	1
Knee	1
Shoulder	1
Acromioclavicular	1
Costochondrals	1
Pain	59/59
Systemic illness	5/59§
Endocarditis	2/59
Mortality reported	0

\* Heroin addicts (57) or abusers (2); pentazocine and methalphenidate hydrochloride (1); all patients took drugs intravenously.

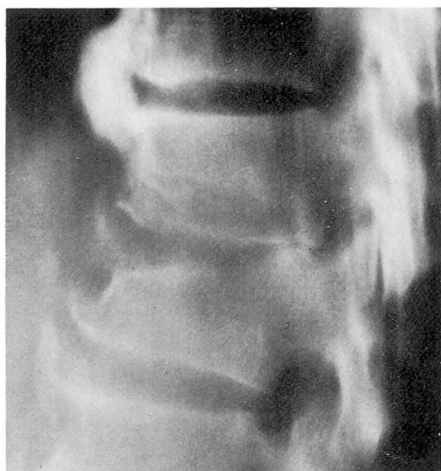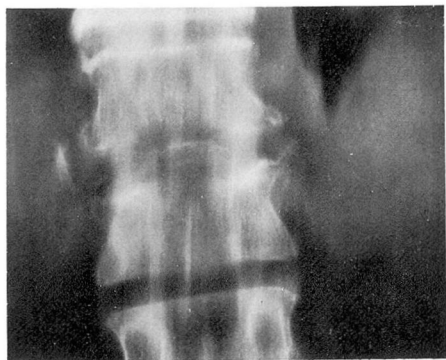
† Diagnosis was established by culture of the bony lesion, interspace, or joint in 57 patients and by blood culture alone in 2 patients.

‡ Klebsiella (1), *Staphylococcus aureus* (1), *Enterobacter cloacae* and *Streptococcus fecalis* (1).

§ Fever, chills, and other symptoms or signs of acute infection were absent in most cases.

lying renal disease. At autopsy, there was no evidence of endocarditis. *Figure 8* is a photomicrograph of a histologic section of the skeletal infection obtained at autopsy.

Baker et al<sup>71</sup> reported the development of acute hematogenous osteomyelitis in three adults with severe neutropenia and were unable to find reports of similar cases in the literature.



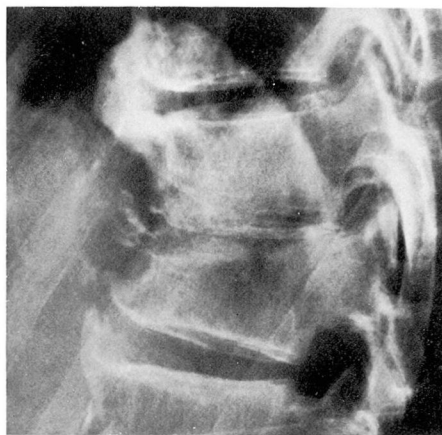**Figs. 5A, B.** Posteroanterior and lateral tomograms showing decrease in vertical height of the 11th thoracic vertebra, narrowing of the subjacent vertebral interspace, and loss of the normal architecture of the vertebral end plates of the 11th and 12th thoracic vertebrae. (Tomograms taken 50 days after the day of staphylococcal bacteremia).

Recently, during a study of gram-negative bacteremia,<sup>72</sup> members of our group treated an adult patient with neutropenic leukemia for hematogenous pyoarthrosis of the hip and osteomyelitis of the femur due to *E. coli*.

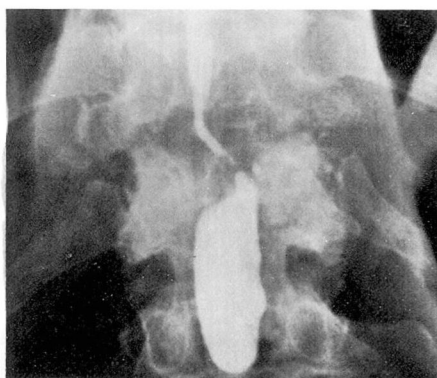
#### **Hematogenous osteomyelitis in sickle cell disease and related anemias**

*Salmonella* osteomyelitis is uncommon, occurring in less than 1% of pa-

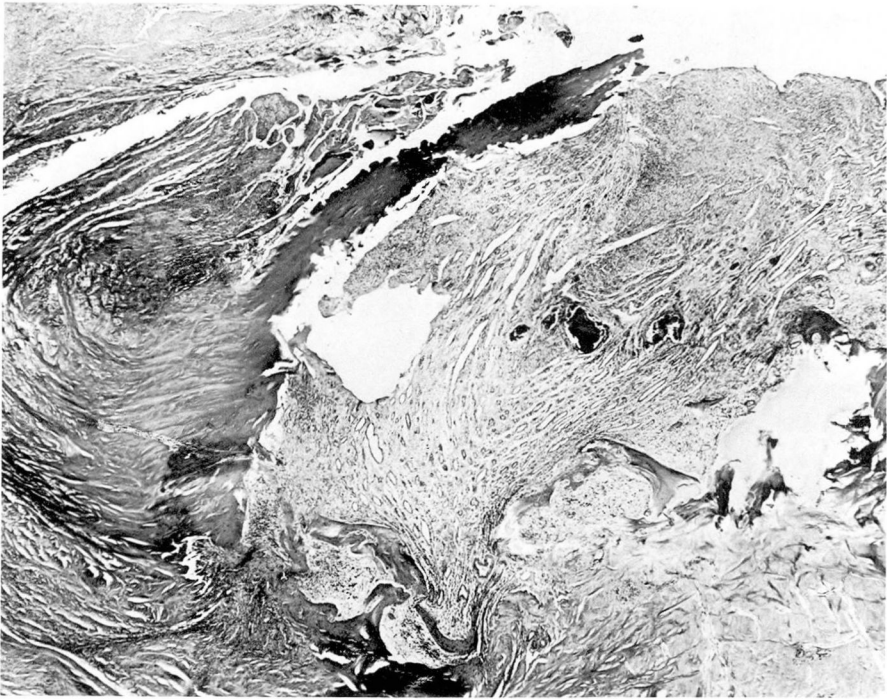
tients with *Salmonella* septicemia.<sup>73, 74</sup> The risk for hematogenous *Salmonella* osteomyelitis in patients with sickle cell disease and related hemoglobinopathies is several hundred times that seen in the normal population.<sup>74-76</sup> This complication occurs primarily in infants and young chil-



**Fig. 6.** Lateral roentgenogram of the involved thoracic region taken 63 days after the day of bacteremia. This shows further progression of the disease with obliteration of the interspace.



**Fig. 7.** Thoracic myelogram with patient in the head-down position showing marked extradural constriction behind the T11-T12 disk space. (Myelogram was done 83 days after the day of staphylococcal bacteremia. *Staphylococcus aureus* was isolated from the involved spinal interspace on the 74th day after the onset of bacteremia.)



**Fig. 8.** This photomicrograph was prepared from the T11-12 lesion demonstrated in *Figure 7*. The process appears to be in a subsidiary phase and formed largely of granulation tissue containing fragments of necrotic bone and modest numbers of inflammatory cells. At autopsy, there was considerable destruction of interspace tissues with encroachment on the spinal cord by the process (hematoxylin-eosin,  $\times 10$ ).

dren, but cases in adults have been reported.<sup>76</sup>

The infection begins in the medulla of the diaphysis of long and short tubular bones.<sup>76, 77</sup> Multiple bony involvement is common. The phalanges of the hands and feet may become involved<sup>78</sup> producing an illness resembling the "hand-foot" syndrome of sickle cell disease.<sup>79</sup> The clinical and roentgenographic features of *Salmonella* osteomyelitis may be very difficult or impossible to differentiate from those of a sickle cell crisis, especially in the earliest stages of the illness; therefore, blood cultures should be obtained from all patients with sickle

cell crisis. Eventually the diagnosis may become apparent, particularly in those patients who have persistent fever, continued leukocytosis, and roentgenographic changes that are far more severe than those secondary to bone marrow thromboses in sickle cell disease.<sup>74, 77</sup> According to Engh et al,<sup>77</sup> the most frequent distinguishing roentgenographic findings are longitudinal intracortical diaphyseal fissuring, overabundant involucrum formation, and involvement of multiple and often symmetrical diaphyseal sites. The linear structures in the cortical diaphysis have been termed "cortical fissuring," but probably represent a

layer of purulent exudate beneath the involucrum and between it and the dead bone.<sup>74</sup>

The pathogenesis of hematogenous *Salmonella* osteomyelitis is a complex phenomenon and may be related to several factors. *Salmonella* organisms are widely present in the environment,<sup>80</sup> providing ample opportunity for exposure and colonization of the intestinal tract with or without producing overt illness. Some strains of *Salmonella* have the capacity *per se* to cross the intestinal mucosal barrier and gain access to the systemic circulation.<sup>81, 82</sup> However, injuries to the intestinal mucosa from localized thrombosis in sickle-hemoglobinopathies and impairment of the hepatic reticuloendothelial system may facilitate invasion of the bloodstream by those organisms.<sup>73</sup> Hemolytic crises of sickle cell disease and related hemoglobinopathies may decrease the ability of macrophages of the spleen and other sites to phagocytize circulating bacteria because of engorgement of reticuloendothelial cells with hemolyzed erythrocytes.<sup>83</sup> Bone marrow thromboses and infarction that occur in sickle cell crises may favor localization of circulating bacteria in bone. Increased concentrations of bilirubin or other breakdown products of erythrocytes in the bone marrow may provide an environment favorable to *Salmonella* organisms.<sup>77, 84</sup>

*Shigella* and certain strains of *E. coli* may also invade the intestinal mucosal barrier<sup>81</sup> and occasionally cause bacteremia.<sup>85, 86</sup> In patients with sickle cell disease, hematogenous osteomyelitis has been produced by *E. coli*,<sup>85</sup> *Shigella sonnei*,<sup>86</sup> *Serratia marcescens*,<sup>87</sup> and *Arizona hinshawii*.<sup>88</sup>

Staphylococci and other gram-positive cocci have caused hematogenous osteomyelitis less frequently in patients with sickle cell disease than in other children,<sup>74</sup> and the reasons for this are not clear.

Studies of antibacterial host factors in patients with sickle cell disease failed to reveal immunoglobulin deficiencies, and the response to *Salmonella* vaccine in those patients was the same as that in normal controls.<sup>89</sup> Paradoxically, although pneumococcal osteomyelitis is quite rare in patients with sickle cell anemia,<sup>90</sup> a wide variety of abnormalities have been determined which may help to explain the significantly increased incidence of serious pneumococcal infections in patients with sickle cell anemia. These include functional asplenia,<sup>91</sup> impaired antibody response to intravenous immunization,<sup>92</sup> a defect in serum opsonizing activity against the pneumococcus,<sup>93</sup> and an abnormality in the alternate pathway of complement activation.<sup>94</sup> The apparent rarity of pneumococcal osteomyelitis in patients with sickle cell disease may be due to the frequent, rapidly lethal nature of pneumococcal infections in patients with this hemoglobinopathy.<sup>90</sup>

#### **Osteomyelitis in chronic granulomatous disease of childhood**

Of 28 patients with chronic granulomatous disease of childhood reported by Wolfson et al.,<sup>95</sup> eight patients had evidence of osteomyelitis involving 19 bones. Some of these lesions may have been the result of hematogenous spread of infection and others from contiguous spread of an adjacent focus of soft tissue infection;

the authors did not specify. Members of the family Enterobacteriaceae, *S. aureus*, and *Aspergillus fumigatus* were the offending organisms. These organisms produce catalase, are phagocytized normally by the patient's polymorphonuclear leukocytes, but they survive and persist within the abnormal phagocytes. Osteomyelitis in the patients with chronic granulomatous disease was manifested by granulomatous inflammation and did not present with pain, fever, or local signs of inflammation. The most frequent sites of involvement were the metatarsals, tarsals, and metacarpals; but the tibia, fibula, humerus, femur, ribs, and thoracic vertebrae were involved in some patients. Roentgenographic changes in some small bones (increased breadth and lack of acute destruction) simulated tuberculous dactylitis. In other small bones, there was marked destruction and widening concomitantly. Abscesses and sequestra rarely occurred. Long-term antimicrobial therapy without surgical intervention usually was all that was required for cure. Of the eight patients, a surgical procedure was required for cure in two.

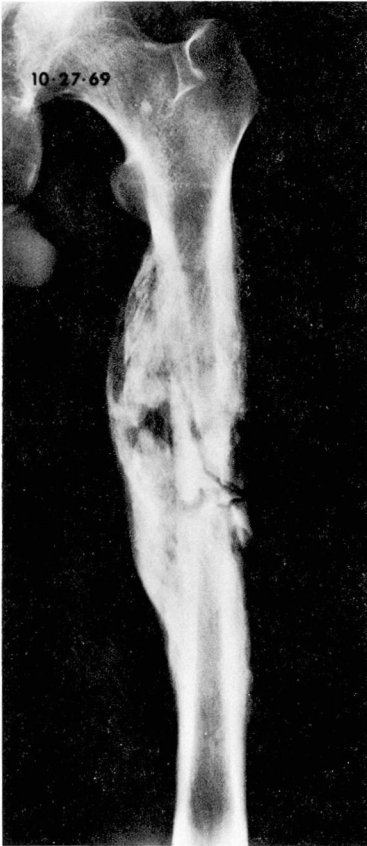
### Diagnostic considerations

One of the major problems in establishing an early diagnosis of acute hematogenous osteomyelitis is that roentgenographic examination is normal in the early stages of the disease. Bone changes may be demonstrated earlier in acute osteomyelitis by means of radioisotope scanning than by conventional roentgenography,<sup>63, 65</sup> and should be used when indicated.

Available data indicate that persistence of infection, sequestra formation, and chronic osteomyelitis rarely develop when appropriate antimicrobial therapy is initiated within 3 days

of the onset of the illness.<sup>15</sup> When the patient presents with a typical history of chills, fever, pain in one site in a limb, and localized tenderness to palpation, a provisional diagnosis can be made and therapy started after appropriate pretreatment cultures are obtained. Detection of localized tenderness is the most significant early clinical finding and indicates that the periosteum has been involved.<sup>14</sup> When therapy is started more than 3 days after the onset of the illness, persistence of infection, sequestra formation, and chronic osteomyelitis is much more likely. It is somewhat discouraging to note that approximately 20% of patients with acute hematogenous osteomyelitis in the antibiotic era have relapses or progress to chronic osteomyelitis (Table 2). The roentgenographic changes of chronic osteomyelitis are shown in Figures 9 to 12. Although the changes were observed on the roentgenograms of a patient in whom osteomyelitis developed after internal fixation of a comminuted fracture, the changes are illustrative of severe chronic osteomyelitis: sequestration in a radiolucent cavity, periosteal elevation with extensive subperiosteal new bone formation.

Patients who have hematogenous osteomyelitis in certain locations may present unusual diagnostic difficulties. For example, patients with osteomyelitis of the pelvis may be misdiagnosed as having acute appendicitis on the right, paracolic abscess on the left, pyelonephritis, arthritis of the hip, pelvic tumor, sciatica, or other conditions.<sup>96</sup> Some patients with hematogenous osteomyelitis of the ilium have had a normal appendix removed because of a mistake in diagnosis.<sup>97</sup> Hematogenous osteomyelitis of the metatarsal sesamoids may masquerade



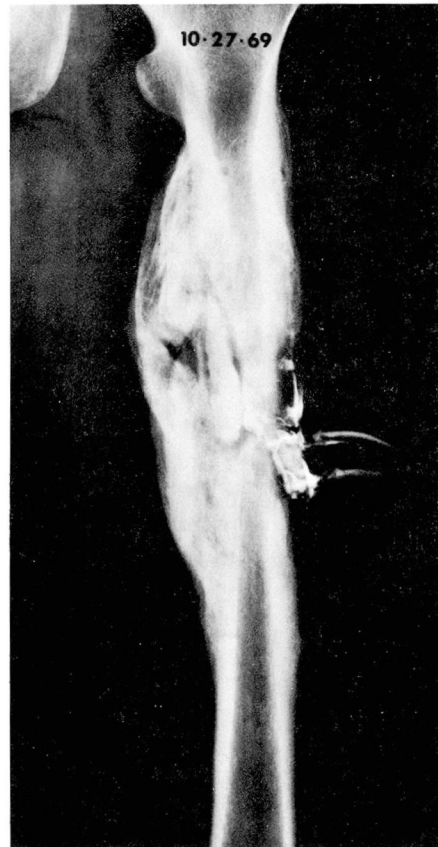
**Fig. 9.** Roentgenogram of the left femur, October 27, 1969, showing marked periosteal reaction, four radioopaque sequestra and a radiolucent area of cortical destruction lateral to the largest of the sequestra.

under the guise of cellulitis, trauma, or gout.<sup>98</sup> Hematogenous sternal osteomyelitis may present as a mass lesion with the differential diagnosis including perforating aneurysm, tuberculosis, carcinoma, and mediastinal abscess.<sup>99</sup> Osteomyelitis of a rib may be mistaken for bone tumor, particularly Ewing's sarcoma.<sup>100</sup>

#### Microbiologic considerations

Since hematogenous osteomyelitis may be produced by a wide variety of pathogens, adequate pretreatment cultures of blood and accessible sites of

osseous infection are essential for optimal therapy. In patients with chronic draining sinuses, care must be taken to avoid contamination of specimens with members of the normal body flora. After cleansing the surrounding skin with isopropyl alcohol, material should be obtained for culture by aspiration or with a swab under aseptic technique. Whenever possible, necrotic or infected tissue from the depth of the wound should be obtained. Often this can be best accomplished at the time of surgery. The material should be placed in a suitable container and transported to the laboratory with an



**Fig. 10.** Sinogram of the left femur on October 27, 1969. The contrast material outlines the lateral and central sequestrum and partially outlines the large medial sequestrum.

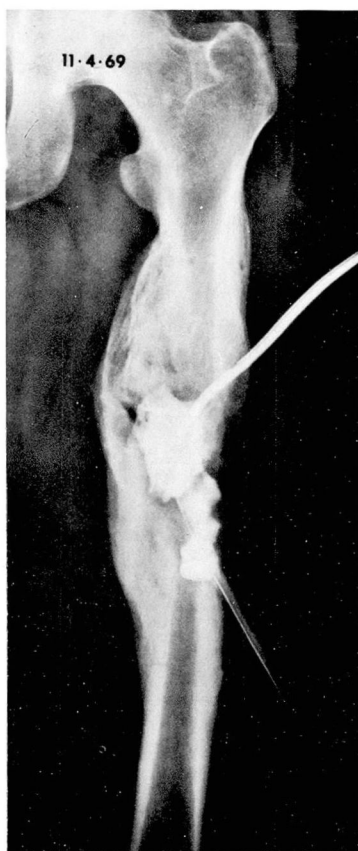

Fig. 11. Sinogram on November 4, 1969, after sequestrectomy, showing contrast material in the surgical space.

informative requisition without delay. Special techniques are required for isolation of anaerobes<sup>101</sup> and other fastidious organisms. Gram-stained smears of exudates, abscesses, or infected tissues should always be obtained simultaneously with the cultures. They may be extremely helpful in evaluating the results of cultures.<sup>102</sup>

When routine aerobic cultures of bone are sterile in cases of osteomyelitis, anaerobic bacteria,<sup>101, 103</sup> acid-fast bacilli,<sup>104, 105</sup> actinomyces, fungi, or other unusual pathogens<sup>106</sup> should be considered. In cases of recurrent or

chronic osteomyelitis, L-form variants<sup>107</sup> or protoplasts<sup>108</sup> have been recovered from lesions using special hypertonic media.

In recent years, anaerobic bacteria have received increased attention as being causes of bone infection.<sup>101, 103</sup> It is of interest in this regard, that before 1920, Taylor and Davies<sup>28</sup> regularly cultured anaerobic bacteria from sequestra of patients with chronic osteomyelitis secondary to trauma. Anaerobic bacteria frequently participate in mixed infections with other organisms and usually occur in cases of os-

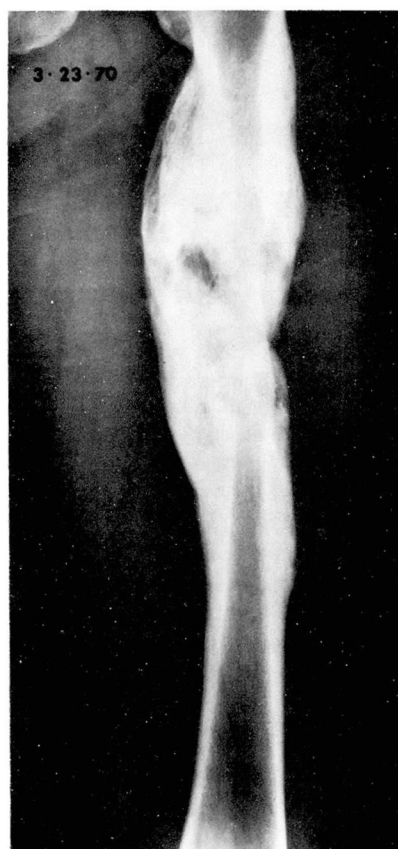

Fig. 12. Roentgenogram of the femur taken in the healing phases of the chronic osteomyelitis.

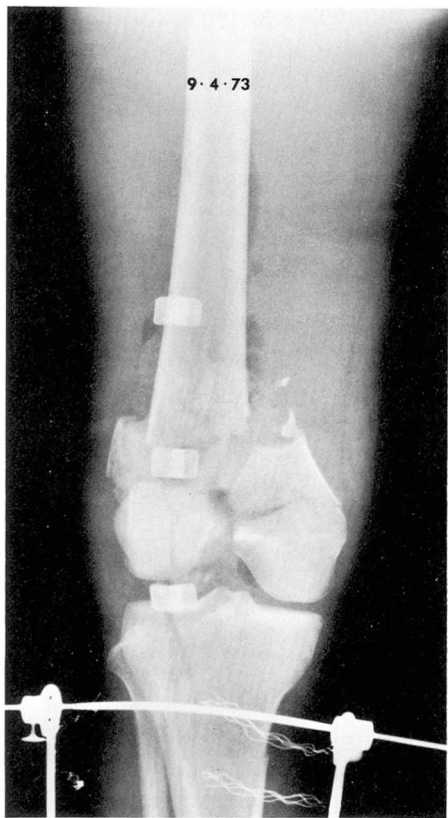


Fig. 13. Roentgenogram of right femur and upper tibia-fibula, showing compound fracture of distal femur and gas in soft tissues. The roentgenogram was taken before the onset of *Bacteroides fragilis* bacteremia which lasted 24 days.

teomyelitis resulting from trauma or spread of contiguous soft tissue infection.<sup>101, 103</sup>

However, cases of hematogenous osteomyelitis due to anaerobic bacteria have been reported. *Figures 13 to 15* are roentgenograms of the femur from a patient with osteomyelitis due to *Bacteroides fragilis*. This patient had abdominal and skeletal trauma, abdominal infection, and *B. fragilis* bacteremia that persisted for 24 days despite parenteral clindamycin therapy. It was not possible to determine with

certainty in this case whether *Bacteroides* osteomyelitis resulted directly from trauma or from hematogenous spread from a focus of infection in the abdomen.

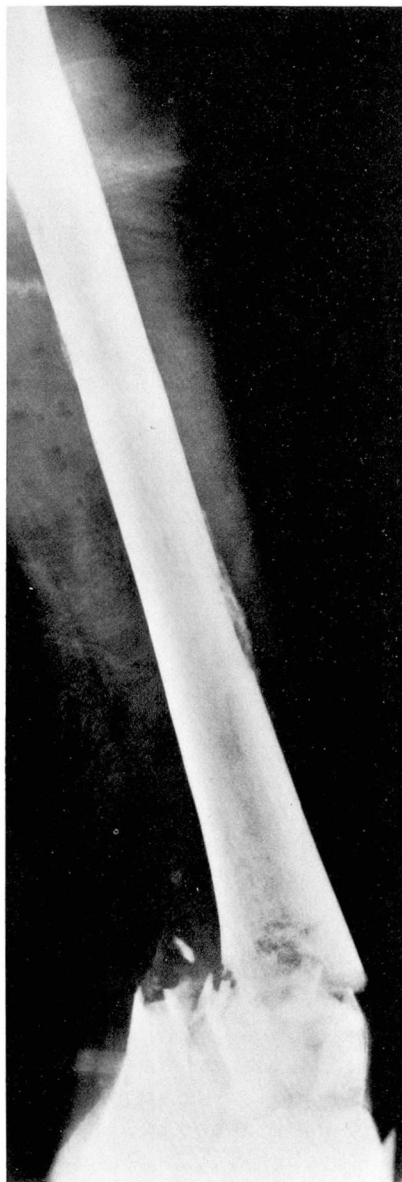

Fig. 14. Roentgenogram taken later in clinical course shows area of cortical destruction and periosteal reaction in the diaphysis of femur laterally and medially.

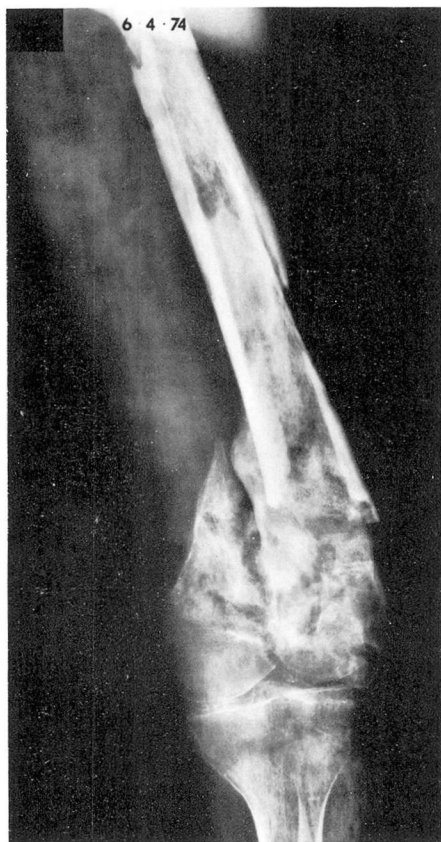

Fig. 15. Roentgenogram of the femur on June 4, 1974, showing further evidence of osteomyelitis.

With the increased use of prolonged intravenous therapy and immunosuppressive drugs, unusual organisms such as fungi<sup>109, 110</sup> or atypical acid-fast bacilli<sup>111</sup> may cause hematogenous osteomyelitis. Figure 16 is the roentgenogram of a patient with hematogenous osteomyelitis of the phalanx. This patient was receiving therapy for Hodgkin's disease when pulmonary infiltrates and pain and swelling of the finger developed. Material aspirated directly from the lung yielded *Mycobacterium kansasii* and *Cryptococcus neoformans*. Material aspirated from

the infected joint space yielded the same organisms.

Hematogenous osteomyelitis has resulted rarely from smallpox<sup>112</sup> and BCG vaccination.<sup>113, 114</sup> Hematogenous skeletal tuberculosis does not occur as frequently as in the past, but still causes significant diagnostic and therapeutic problems.<sup>104</sup>

### Microbial determinants

The properties of microorganisms which determine their ability to cause disease of bone are not well defined. Some of the properties of gram-negative bacilli relevant to their pathogenicity have been reviewed elsewhere<sup>115, 116</sup> and will not be repeated here. We will confine ourselves to some brief remarks about the *Staphylococcus*, since it is still the organism most commonly responsible for hematogenous osteomyelitis.

Recent studies indicate that a mucopeptide of the cell wall of virulent

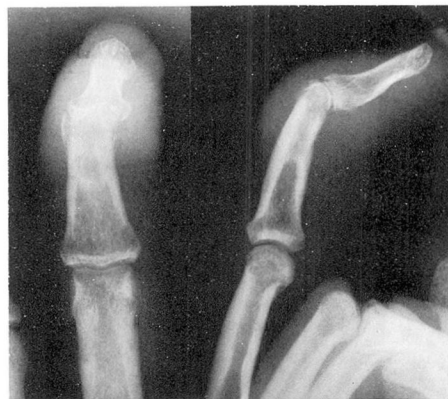

Fig. 16. Roentgenograms of the right middle finger of a patient with Hodgkin's disease. They show soft tissue swelling, periosteal reaction, and erosion of the bony cortex of the middle phalanx with narrowing of the joint space. Material aspirated from the infected joint space yielded *Mycobacterium kansasii* and *Cryptococcus neoformans*.

strains of *S. aureus* inhibits chemotaxis of polymorphonuclear leukocytes, suppresses inflammatory edema formation, and enables the bacteria to produce more severe lesions presumably as a result of their unbridled multiplication in the early stages of established infection.<sup>117</sup> Another constituent of the cell wall of *S. aureus*, protein A, reacts with the Fc fragment of normal and immune IgG immunoglobulin.<sup>118</sup> The main opsonic site of the immunoglobulin G is located on the Fc region.<sup>119, 120</sup> Evidence suggests that protein A of staphylococci inhibits phagocytosis by competing with polymorphonuclear leukocytes for the Fc sites.<sup>119</sup> Thus, it is possible that protein A may enhance survival of staphylococci in tissues and may be another virulence factor, along with leukocidins, hemolysins, coagulase, and penicillinase.<sup>119</sup> It also has been shown that a considerable number of staphylococci isolated from human sources are capable of producing capsules which may enhance their virulence.<sup>120</sup> It is known that extracellular staphylococcal toxins may cause capillary vasospasm with thrombosis,<sup>121</sup> which might contribute to the development of the acute lesion in staphylococcal osteomyelitis.

An attribute of osteomyelitis caused by *S. aureus* is its tendency to recur, often at some time remote from the initial episode.<sup>11, 13</sup> Cases are on record in which recurrences occurred after quiescent periods of 40 to 70 years.<sup>11, 13</sup> The ability of staphylococci to persist in bone remains unexplained. Recently, Hedstrom and Kronvall<sup>122</sup> showed that strains of staphylococci responsible for chronic hematogenous osteomyelitis belonged

predominantly to phage groups I and II; most were lipase-positive and all produced protein A. They suggested that a possible host-parasite interaction takes place in the bone marrow in which lipids and staphylococcal lipases may play a role analogous to that suggested for furunculosis.

### Therapeutic considerations

Patients with acute hematogenous osteomyelitis should be on bed rest with immobilization of the affected part. Appropriate antimicrobial therapy alone may be sufficient to cure this infection if treatment is started within 72 hours after the onset of the disease.<sup>15</sup> Whenever possible, a Gram-stained smear of an aspirate from the affected area should be used as a guide to initial therapy. When this is not possible, initial therapy must be based upon an educated guess as to what is the most likely etiologic organism. Knowledge of the age of the patient, the location of the infection, the presence of underlying predisposing diseases and circumstances involved in development of the infection may permit an educated guess as to the etiologic organism. For example, in an otherwise healthy child with a history of a recent furuncle and a presumptive clinical diagnosis of acute hematogenous osteomyelitis of the distal femur, parenteral antistaphylococcal therapy with therapeutic doses of a penicillinase-resistant penicillin should be administered after appropriate pretreatment cultures are obtained (provided there is no history of penicillin allergy). Definitive antimicrobial chemotherapy depends upon the identity of the pathogen, its in vitro susceptibility and the patient's ability

**Table 5.** Currently preferred antimicrobial drugs for initial presumptive therapy of acute hematogenous osteomyelitis\*

Suspected etiologic organism	Currently preferred drugs†
<i>Staphylococcus aureus</i>	1) Oxacillin, methicillin, or nafcillin 2) A cephalosporin 3) Vancomycin 4) Clindamycin
<i>Streptococcus pyogenes</i>	1) Penicillin G 2) A cephalosporin 3) Erythromycin 4) Clindamycin
Salmonellae	1) Chloramphenicol 2) Ampicillin 3) Trimethoprim-sulfamethoxazole
<i>Pseudomonas aeruginosa</i>	1) Carbenicillin‡ and gentamicin§
<i>E. coli</i> , Klebsiella-Enterobacter, Proteus, Ser- ratia	1) Gentamicin
Bacteroides	1) Clindamycin 2) Chloramphenicol

\* Definitive antimicrobial therapy is determined subsequently from the results of in vitro susceptibility tests and the patient's response to treatment. Initial therapy of acute hematogenous osteomyelitis is administered by the parenteral route.

† Numeral 1 represents the drug(s) of first choice, numerals after 1 represent alternative drugs that may be used when circumstances indicate.

‡ Should not be used in penicillin-allergic patients.

§ Tobramycin, amikacin, or sisomicin are investigational aminoglycoside antibiotics that may be effective against gentamicin-resistant strains of *Pseudomonas aeruginosa*.

to tolerate the drug. Table 5 lists some of the preferred antimicrobial drugs for initial presumptive therapy of acute hematogenous osteomyelitis for various suspected pathogens. We believe that antimicrobial therapy should be administered for at least 4 to 6 weeks in cases of uncomplicated acute hematogenous osteomyelitis.

When the patient with acute hematogenous osteomyelitis does not respond to treatment within 48 to 72 hours (lysis of fever, decreased pain, increased appetite and sense of well-being, sterile blood cultures), surgery becomes mandatory. When the roentgenogram and bone scan reveal no diagnostic changes, the surgeon has to rely on his judgment as to the probable location of the lesion. Under aseptic

technique in the operating room, an incision of the skin is made over the area of maximum tenderness. The periosteum is incised in order to drain the subperiosteal abscess. In some instances, it may be necessary to drill one or more small holes in the bony cortex to decompress the medullary cavity, allowing an abscess to drain and prevent infarction of the bony cortex. We now prefer to close the operative wound to prevent secondary infection. Suction drainage tubes are utilized for a short period of time.

When hematogenous osteomyelitis in the neck of the femur is strongly suspected, arthrotomy for decompression and for culture is mandatory. The neck of the femur lies within the synovial capsule of the hip joint. A sub-

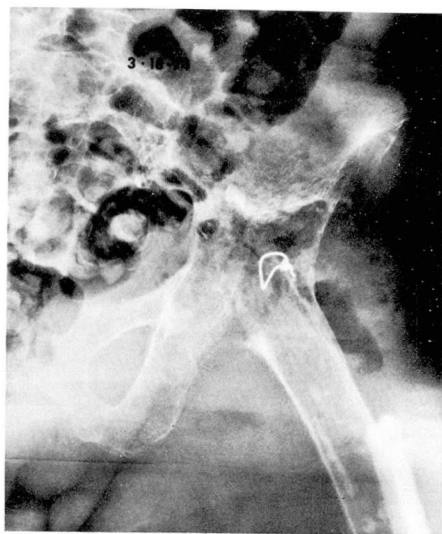
periosteal abscess in that region may rupture into the joint causing septic arthritis. This can be complicated by necrosis of the head of the femur and dislocation of the hip—a disaster for a young child.

The therapy of chronic hematogenous osteomyelitis is a complex subject and will be considered only briefly. Bed rest, immobilization of the affected part, and administration of specific antimicrobial chemotherapeutic agents are extremely important. However, because of the nature of the lesion itself, surgical procedures are mandatory in order to accomplish the following: excise sinus tracts down to the involved bone, culture and biopsy the infected bone, remove all sequestra, drain abscesses, and debride all infected granulation tissue and bone if feasible. The surgeon attempts to remove all ischemic bone and soft tissue leaving a well-vascularized wound bed.<sup>123-125</sup> Other more complicated measures such as insertion of autogenous bone grafts and application of split thickness skin grafts may be required in some patients.

Under ideal conditions, postoperative treatment of patients with chronic osteomyelitis with the closed suction-irrigation technique serves to eliminate dead space by allowing healthy granulation tissue to obliterate the cavity occasioned by the infection and the surgical procedure.<sup>126</sup> This has been responsible for improved results of surgical therapy of chronic osteomyelitis.<sup>124, 126</sup> However, optimal use of the suction-irrigation apparatus requires meticulous nursing care to maintain continuous flow and to avoid contamination of the system. Even with the best technique, contamination may occur, but usually it

is of little consequence. However, occasionally it may give rise to serious gram-negative bacillary infection. *Figures 17 and 18* are roentgenograms of the hip region of a patient who required suction-irrigation after removal of an infected total hip prosthesis (staphylococcal pyoarthrosis). The postoperative hip wound became contaminated with gram-negative bacilli, leading to recurrent episodes of gram-negative bacteremia. Fortunately, with appropriate surgical and medical management, the patient survived. It is our policy to utilize the suction-irrigation apparatus for less than 10 days whenever possible, and to obtain cultures of the effluent solutions at frequent intervals.

Recently, Hedstrom<sup>127</sup> showed that prolonged antibiotic treatment of chronic staphylococcal osteomyelitis for at least 6 months, significantly lowered the frequency of recurrences during the first year after the end of treatment than did shorter courses of



**Fig. 17.** Film taken following removal of infected Charnley-Mueller prosthesis, showing suction-irrigation tube and gas in soft tissues.

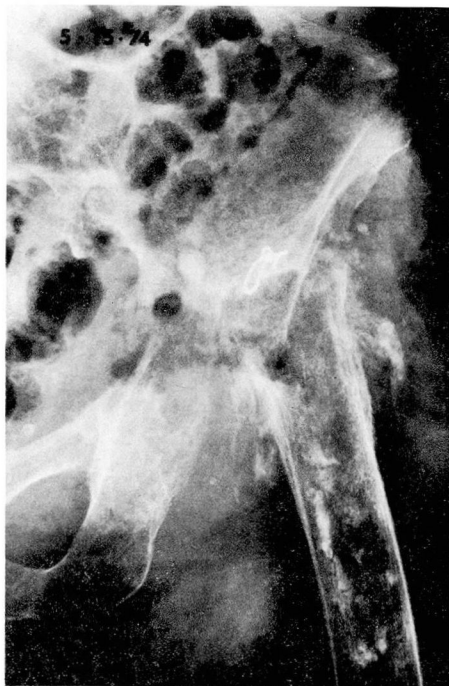


Fig. 18. Same patient as in *Figure 17*. Film taken approximately 2 months later, showing periosteal elevation and subperiosteal new bone formation indicative of osteomyelitis.

therapy. We routinely treat such patients with an initial course of parenteral oxacillin therapy for from 4 to 6 weeks, followed by oral administration of cloxacillin or dicloxacillin for 1 to 2 years. We monitor them at periodic intervals to make sure that they are tolerating the drug without side effects.

Vertebral osteomyelitis is treated with bed rest, analgesics, appropriate antibiotics based upon the results of susceptibility tests of isolates from the affected intervertebral disc space or bone (or blood cultures when the latter are unavailable). Therapy is administered for 4 to 6 weeks. Spontaneous intervertebral fusion usually occurs. Surgery is not indicated unless a complication intervenes. We agree

with Jordan and Kirby<sup>52</sup> that immobilization in a body cast is not necessary for treatment of vertebral osteomyelitis.

### Summary and conclusions

Hematogenous osteomyelitis is a disease with protean manifestations. The presenting illness and location of bone infection vary with the age of the patient, the nature of predisposing factors, and the pathogen. Data indicate that the incidence of acute hematogenous osteomyelitis of children is decreasing, that in neonates it may be increasing, and that in adults, it is increasing. The clinical picture of the condition has been modified from a frequently fulminating or acute illness with high mortality in the preantimicrobial era to a more insidious disease with a considerably lower mortality. Hematogenous osteomyelitis now presents considerable diagnostic difficulties and often is mistaken initially for a wide variety of unrelated illnesses. New mechanisms for hematogenous osteomyelitis include intravenous heroin abuse, infections of intravenous cannulas or subcutaneous arteriovenous fistulas in hemodialysis patients, parenteral hyperalimentation, and umbilical catheterization. It occurs with unusual frequency in patients with sickle cell hemoglobinopathies and chronic granulomatous disease of childhood. It has been reported in leukopenic patients and in those with other disorders of leukocytes. Although staphylococci are still the most common causative organisms, an expanding number of cases are being caused by gram-negative bacilli and more unusual pathogens. Despite the availability of potent antimicrobial drugs, 20% of children with acute

hematogenous osteomyelitis contract chronic or recurrent disease.

Hematogenous osteomyelitis is not yet a disease of the past. Although it accounts for only one fifth of all the cases of osteomyelitis in the United States, there is an urgent need for additional studies of pathogenesis and improved methods of management.

## References

1. Waldvogel FA, Medhoff G, Swartz MN: Osteomyelitis; a review of clinical features, therapeutic considerations and unusual aspects. *N Engl J Med* 282: 198-206, 260-266, 316-322, 1970.
2. Leading article: Changed character of osteomyelitis. *Br Med J* 3: 255-256, 1967.
3. Norden CW: Experimental osteomyelitis I. A description of the model. *J Infect Dis* 122: 410-418, 1970.
4. Norden CW: Experimental osteomyelitis II. Therapeutic trials and measurement of antibiotic levels in bone. *J Infect Dis* 124: 565-571, 1971.
5. Norden CW, Dickens DR: Experimental osteomyelitis III. Treatment with cephaloridine. *J Infect Dis* 127: 525-528, 1973.
6. Andriole VT, Nagel DA, Southwick WO: A paradigm for human chronic osteomyelitis. *J Bone Joint Surg* 55-A: 1511-1515, 1973.
7. Andriole VT, Nagel DA, Southwick WO: Chronic staphylococcal osteomyelitis; an experimental model. *Yale J Biol Med* 47: 33-39, 1974.
8. Jaffe HL: *Metabolic, Degenerative and Inflammatory Diseases of Bones and Joints*. Philadelphia, Lea & Febiger, 1972.
9. Collins DH: *Pathology of Bone*. London, Butterworths, 1966, pp 209-227.
10. Kahn DS, Pritzker KPH: The pathophysiology of bone infection. *Clin Orthop* 96: 12-20, 1973.
11. Frost HM: Pyogenic osteomyelitis; the normal bone spaces as a bacterial reservoir. *Henry Ford Hosp Med Bull* 8: 263-266, 1960.
12. Butler ECB: The treatment, complications and late results of acute haematogenous osteomyelitis based on a study of 500 cases admitted to the London Hospital during the years 1919-37. *Br J Surg* 28: 261-274, 1940.
13. Wilensky AO: *Osteomyelitis; Its Pathogenesis, Symptomatology and Treatment*. New York, MacMillan Co, 1934.
14. Green M, Nyhan WL Jr, Fousek MD: Acute hematogenous osteomyelitis. *Pediatrics* 17: 368-382, 1956.
15. Harris NH: Some problems in the diagnosis and treatment of acute osteomyelitis. *J Bone Joint Surg* 42-B: 535-541, 1960.
16. Trueta J, Morgan JD: Late results in the treatment of one hundred cases of acute haematogenous osteomyelitis. *Br J Surg* 41: 449-456, 1954.
17. Winters JL, Cahen I: Acute hematogenous osteomyelitis; a review of sixty-six cases. *J Bone Joint Surg* 42-A: 691-704, 1960.
18. Lowe RW, Brooks AL: Hematogenous osteomyelitis. *South Med J* 63: 1183-1189, 1970.
19. Caldwell GA, Wickstrom J: The closed treatment of acute hematogenous osteomyelitis; results in 67 cases. *Ann Surg* 131: 734-742, 1950.
20. Altemeier WA, Largent T: Antibiotic and chemotherapeutic agents in infections of the skeletal system. *JAMA* 150: 1462-1468, 1952.
21. Blockley NJ, Watson JT: Acute osteomyelitis in children. *J Bone Joint Surg* 52-B: 77-87, 1970.
22. Shandling B: Acute hematogenous osteomyelitis; a review of 300 cases treated during 1952-1959. *S Afr Med J* 34: 520-524, 1960.
23. Hobo T: Zur pathogenese der akuten haematogenen Osteomyelitis mit Berücksichtigung der Valfarbnungslehre. *Acta Sch Med Univ Kioto* 4: 1-29, 1921-1922.
24. Starr CL: Acute hematogenous osteomyelitis. *Arch Surg* 4: 567-587, 1922.
25. Trueta J: The three types of acute hematogenous osteomyelitis. *J Bone Joint Surg* 41-B: 671-680, 1959.
26. Hart VL: Acute osteomyelitis in children. *JAMA* 108: 524-528, 1937.
27. Green WT, Shannon JG: Osteomyelitis of infants; a disease different from osteomyelitis of older children. *Arch Surg* 32: 462-493, 1936.
28. Taylor K, Davies M: Persistence of bacteria within sequestra. *Ann Surg* 66: 522-528, 1917.

29. Frost HM, Villaneuva AR, Roth H: Pyogenic osteomyelitis; diffusion in live and dead bone with particular reference to the tetracycline antibiotics. *Henry Ford Hosp Med Bull* 8: 255-262, 1960.
30. Weissberg ED, Smith, AL, Smith DH: Clinical features of neonatal osteomyelitis. *Pediatrics* 53: 505-510, 1974.
31. Fardon DF: Osteomyelitis of the scapula in an infant. *Mo Med* 67: 299-302, 1970.
32. Ek J: Acute hematogenous osteomyelitis in infancy and childhood; early clinical diagnosis and effect of treatment. *Clin Pediatr* 10: 377-379, 1971.
33. Lindblad B, Ekengren K, Aurelius G: The prognosis of acute hematogenous osteomyelitis and its complications during early infancy after the advent of antibiotics. *Acta Paediatr Scand* 54: 24-32, 1965.
34. Einstein RAJ, Thomas CG Jr: Osteomyelitis in infants. *Am J Roentgenol Radium Ther Nucl Med* 55: 299-314, 1946.
35. Qureshi ME, Puri SP: Osteomyelitis after exchange transfusion. *Br Med J* 2: 28-29, 1971.
36. Wiley AM, Trueta J: The vascular anatomy of the spine and its relationship to pyogenic vertebral osteomyelitis. *J Bone Joint Surg* 41-B: 796-809, 1959.
37. Zadek I: Acute osteomyelitis of the long bones of adults. *Arch Surg* 37: 531-545, 1938.
38. King DM, Mayo KM: Subacute hematogenous osteomyelitis. *J Bone Joint Surg* 51-B: 458-463, 1969.
39. Smith AG: Hematogenous Friedlander's bacillus osteomyelitis. *JAMA* 195: 1060-1061, 1966.
40. Irvine R, Johnson BL Jr, Amstutz HC: The relationship of genitourinary tract procedures and deep sepsis after total hip replacements. *Surg Gynecol Obstet* 139: 701-706, 1974.
41. Hall AJ: Late infection about a total knee prosthesis; report of a case secondary to urinary tract infection. *J Bone Joint Surg* 56-B: 144-147, 1974.
42. Some problems of acute osteomyelitis. *Br Med J* 4: 317-318, 1972.
43. Gerszten E, Allison MJ, Dalton HP: An epidemiologic study of 100 consecutive cases of osteomyelitis. *South Med J* 63: 365-367, 1970.
44. Nade S, Robertson FW, Taylor TKF: Antibiotics in the treatment of acute osteomyelitis and acute septic arthritis in children. *Med J Aust* 2: 703-705, 1974.
45. Harris NH, Kirkaldy-Willis WH: Primary subacute pyogenic osteomyelitis. *J Bone Joint Surg* 47-B: 526-532, 1965.
46. Robertson DE: Primary acute and subacute localized osteomyelitis and osteochondritis in children. *Can J Surg* 10: 408-413, 1967.
47. Primary subacute hematogenous osteomyelitis. *Br Med J* 3: 728-729, 1969.
48. Kulowski J: Pyogenic osteomyelitis of the spine; an analysis and discussion of 102 cases. *J Bone Joint Surg* 18: 343-364, 1936.
49. Ambrose GB, Alpert M, Neer CS: Vertebral osteomyelitis; a diagnostic problem. *JAMA* 197: 619-622, 1966.
50. Stone DB, Bonfiglio M: Pyogenic vertebral osteomyelitis; a diagnostic pitfall for the internist. *Arch Intern Med* 112: 491-500, 1963.
51. Genster HG, Anderson MJF: Spinal osteomyelitis complicating urinary tract infection. *J Urol* 107: 109-111, 1972.
52. Jordan CM, Kirby WMM: Pyogenic vertebral osteomyelitis; treatment with antimicrobial agents and bed rest. *Arch Intern Med* 128: 405-410, 1971.
53. Freehafer AA, Furey JG, Pierce DS: Pyogenic osteomyelitis of the spine resulting in spinal paralysis. *J Bone Joint Surg* 44-A: 710-716, 1962.
54. Henriques CQ: Osteomyelitis as a complication in urology. *Br J Surg* 46: 19-28, 1958-59.
55. Bruno MS, Silverberg TN, Goldstein DH: Embolic osteomyelitis of the spine as a complication of infection of the urinary tract. *Am J Med* 29: 865-878, 1960.
56. Leigh TF, Kelly RP, Weens HS: Spinal osteomyelitis associated with urinary tract infections. *Radiology* 65: 334-342, 1955.
57. Henson SW Jr, Coventry MB: Osteomyelitis of the vertebrae as a result of infection of the urinary tract. *Surg Gynecol Obstet* 102: 207-214, 1956.
58. Guri JP: Pyogenic osteomyelitis of the spine; differential diagnosis through clinical and roentgenographic observations. *J Bone Joint Surg* 28: 29-39, 1946.
59. Wear JE, Baylin GJ, Martin TM: Pyogenic osteomyelitis of the spine. *Am J Roentgenol Radium Ther Nucl Med* 67: 90-94, 1952.

60. Griffiths HED, Jones DM: Pyogenic infection of the spine. *J Bone Joint Surg* 53-B: 383-391, 1971.
61. Holzman RS, Bishko F: Osteomyelitis in heroin addicts. *Ann Intern Med* 75: 693-696, 1971.
62. Lewis MA, Gorbach S, Altner P: Spinal pseudomonas chondro-osteomyelitis in heroin users. *N Engl J Med* 286: 1303, 1972.
63. Kido D, Bryan D, Halpern M: Hematogenous osteomyelitis in drug addicts. *Am J Roentgenol Radium Ther Nucl Med* 118: 356-363, 1973.
64. Selby RC, Pillay KV: Osteomyelitis and disc infection secondary to *Pseudomonas aeruginosa* in heroin addiction; case report. *J Neurosurg* 37: 463-466, 1972.
65. Salahuddin NI, Madhavan T, Fisher EJ, et al: *Pseudomonas osteomyelitis*; radiologic features. *Radiology* 109: 41-47, 1973.
66. Light RW: Vertebral osteomyelitis due to *Pseudomonas* in the occasional heroin user. *JAMA* 228: 1272, 1974.
67. Bryan V, Franks L, Torres H: *Pseudomonas aeruginosa* cervical diskitis with chondroosteomyelitis in an intravenous drug abuser. *Surg Neurol* 1: 142-144, 1973.
68. Wiesseman GJ, Wood VE, Kroll LL: *Pseudomonas* vertebral osteomyelitis in heroin addicts; report of 5 cases. *J Bone Joint Surg* 55-A: 1416-1424, 1973.
69. O'Connell CJ, Cherry AV, Zoll JG: Osteomyelitis of cervical spine; *Candida guilliermondii*. *Ann Intern Med* 79: 448, 1973.
70. Leonard A, Comty CM, Shapiro FL, et al: Osteomyelitis in hemodialysis patients. *Ann Intern Med* 78: 651-658, 1973.
71. Baker LRL, Brain MC, Miller JK, et al: Osteomyelitis; an unusual sequel to neutropenia. *Br Med J* 1: 722-725, 1967.
72. McHenry MC, Cavan TL, Hawk WA, et al: Gram-negative bacteremia; variable clinical course and useful prognostic factors. *Cleve Clin Q* 42: 15-32, 1975.
73. Widen AL, Cardon L: *Salmonella typhimurium* osteomyelitis with sickle cell-hemoglobin C disease; a review and case report. *Ann Intern Med* 54: 510-521, 1961.
74. Diggs LW: Bone and joint lesions in sickle-cell disease. *Clin Orthop* 52: 119-143, 1967.
75. Specht EE: Hemoglobinopathic salmonella osteomyelitis. *Clin Orthop* 79: 110-118, 1971.
76. Barrett-Connor E: Bacterial infection and sickle cell anemia; an analysis of 250 infections in 166 patients and a review of the literature. *Medicine* 50: 97-112, 1971.
77. Engh CA, Hughes JL, Abrams RC, et al: Osteomyelitis in the patient with sickle-cell disease. *J Bone Joint Surg* 53-A: 1-15, 1971.
78. Constant E, Green RL, Wagner DK: *Salmonella* osteomyelitis of both hands and the hand-foot syndrome. *Arch Surg* 102: 148-151, 1971.
79. Watson RJ, Burko H, Megas H, et al: The hand-foot syndrome in sickle-cell disease in young children. *Pediatrics* 31: 975-982, 1963.
80. Bowmer EJ: The challenge of salmonellosis; major public health problem. *Am J Med Sci* 247: 467-501, 1964.
81. Grady GF, Keusch GT: Pathogenesis of bacterial diarrheas. *N Engl J Med* 285: 831-841, 1971.
82. Hornick RB, Greisman SE, Woodward TE, et al: Typhoid fever; pathogenesis and immunologic control. *N Engl J Med* 283: 686-691, 1970.
83. Kaye D, Hook EW: The influence of hemolysis or blood loss on susceptibility to infection. *J Immunol* 91: 65-75, 1963.
84. Kaye D, Palmieri M, Rocha H: Effect of bile on the action of blood against *Salmonella*. *J Bacteriol* 91: 945-952, 1966.
85. Greenberg LW, Haynes RE: *Escherichia coli* osteomyelitis in an infant with sickle-cell disease. *Clin Pediatr* 9: 436-438, 1970.
86. Rubin HM, Eardley W, Nichols BL: *Shigella sonnei* osteomyelitis and sickle-cell anemia. *Am J Dis Child* 116: 83-87, 1968.
87. Fonk J, Coonrad DJ: *Serratia* osteomyelitis in sickle cell disease. *JAMA* 217: 80-81, 1971.
88. Hruby MA, Honig GR, Lolekha S, et al: *Arizona hinshawii* osteomyelitis in sickle cell anemia. *Am J Dis Child* 125: 867-868, 1973.
89. Robbins JB, Pearson HA: Normal response of sickle cell anemia patients to immunization with *Salmonella* vaccines. *Pediatrics* 66: 877-882, 1965.
90. Seeler RA, Reddi CU, Kittams D: *Diplococcus pneumoniae* osteomyelitis in an

- infant with sickle cell anemia. *Clin Pediatr* 13: 372-374, 1974.
91. Pearson HA, Cornelius EA, Schwartz AD, et al: Transfusion-reversible functional asplenia in young children with sickle-cell anemia. *N Engl J Med* 283: 334-337, 1970.
92. Schwartz AD, Pearson HA: Impaired antibody response to intravenous immunization in sickle cell anemia. *Pediatr Res* 6: 145-149, 1972.
93. Winkelstein JA, Drachman RH: Deficiency of pneumococcal serum opsonizing activity in sickle-cell disease. *N Engl J Med* 279: 459-466, 1968.
94. Johnston RB Jr, Newman SL, Struth AG: An abnormality of the alternate pathway of complement activation in sickle-cell disease. *N Engl J Med* 288: 803-808, 1973.
95. Wolfson JJ, Kane WJ, Laxdal SD, et al: Bone findings in chronic granulomatous disease of childhood. *J Bone Joint Surg* 51-A: 1573-1583, 1969.
96. Morgan A, Yates AK: The diagnosis of acute osteomyelitis of the pelvis. *Postgrad Med J* 42: 74-78, 1966.
97. Weld PW: Osteomyelitis of the ilium; masquerading as acute appendicitis. *JAMA* 173: 106-108, 1960.
98. Colwill M: Osteomyelitis of the metatarsal sesamoids. *J Bone Joint Surg* 51-B: 464-468, 1969.
99. Biesecker GL, Aaron BL, Mullen JT: Primary sternal osteomyelitis. *Chest* 63: 236-238, 1973.
100. Seashore JH, Touloukian RJ, Pickett LK: Acute hematogenous osteomyelitis of the rib; primary surgical treatment in two cases. *Clin Pediatr* 12: 379-380, 1973.
101. Ziment I, Miller LG, Finegold SM: Non-sporulating anaerobic bacteria in osteomyelitis. *Antimicrob Agents Chemother* 7: 77-85, 1967.
102. McHenry MC, Gavan TL: Selection and use of antimicrobial drugs. *Prog Clin Pathol* 6, 1975. In press.
103. Nettles JL, Kelly PJ, Martin WJ, et al: Musculoskeletal infections due to *Bacteroides*; a study of eleven cases. *J Bone Joint Surg* 51-A: 230-238, 1969.
104. Davidson PT, Horowitz I: Skeletal tuberculosis; a review with patient presentations and discussion. *Am J Med* 48: 77-84, 1970.
105. Watanakunakorn C, Trott A: Vertebral osteomyelitis due to *Mycobacterium kansasii*. *Am Rev Respir Dis* 107: 846-850, 1973.
106. Curtiss PJ Jr: Some uncommon forms of osteomyelitis. *Clin Orthop* 96: 84-87, 1973.
107. Gordon SL, Greer RB, Craig CP: Recurrent osteomyelitis; report of four cases culturing L-form variants of staphylococci. *J Bone Joint Surg* 53-A: 1150-1156, 1971.
108. Rosner R: Isolation of protoplasts of *Staphylococcus aureus* from a case of recurrent acute osteomyelitis. *Tech Bull Reg Med Tech* 38: 205-210, 1968.
109. Adler S, Randall J, Plotkin SA: Candidal osteomyelitis and arthritis in a neonate. *Am J Dis Child* 123: 595-596, 1972.
110. Freeman JB, Wienke JW, Soper RT: Candida osteomyelitis with intravenous alimentation. *J Pediatr Surg* 9: 783-784, 1974.
111. Dalinka MK, Hemming VG: Atypical mycobacterial osteomyelitis; report of a case associated with acute lymphoblastic leukemia. *J Can Assoc Radiol* 22: 173-175, 1971.
112. Singhal RK: Osteo-articular complications of smallpox vaccination. *J Indian Med Assoc* 55: 20-22, 1970.
113. Foucard T, Hjelmstedt A: BCG-osteomyelitis and -osteoarthritis as a complication following BCG-vaccination. *Acta Orthop Scand* 42: 142-151, 1971.
114. Erikson U, Hjelmstedt A: Roentgenologic aspects of BCG-osteomyelitis. *Radiology* 101: 575-578, 1971.
115. McHenry MC: Bacteremic shock due to gram-negative bacilli. *Geriatrics* 24: 101-111, 1969.
116. McHenry MC, Hawk WA: Bacteremia caused by gram-negative bacilli. *Med Clin North Am* 58: 623-638, 1974.
117. Glynn AA: Bacterial factors inhibiting host defense mechanisms, in *Microbial Pathogenicity in Man and Animals*. Smith H, Pearce JH, eds. London, Cambridge Univ Press, 1972, pp 75-112.
118. Ekstedt RD: Immunity to the staphylococci, in *The Staphylococci*. Cohen JO, ed. New York, Wiley & Sons Inc, 1972, pp 391-418.
119. Dossett JH, Kronvall G, Williams RC Jr,

- et al: Antiphagocytic effects of staphylococcal protein A. *J Immunol* **103**: 1405-1410, 1969.
120. Wiley BB, Maverakis NH: Capsule production and virulence among strains of *Staphylococcus aureus*. *Ann NY Acad Sci* **236**: 221-232, 1974.
121. Thal A, Egner W: Local effect of staphylococcal toxin. *AMA Arch Pathol* **57**: 392-404, 1954.
122. Hedström SA, Kronvall G: Phage group, lipase activity and protein A content of *Staphylococcus aureus* strains from cases of chronic osteomyelitis. *Scand J Infect Dis* **4**: 203-207, 1972.
123. West WF, Kelly PJ, Martin WJ: Chronic osteomyelitis I. Factors affecting the results of treatment in 186 patients. *JAMA* **213**: 1837-1842, 1970.
124. Kelly PJ, Martin WJ, Coventry MB: Chronic osteomyelitis II. Treatment with closed irrigation and suction. *JAMA* **213**: 1843-1848, 1970.
125. Overton LM, Tully WP: Surgical treatment of chronic osteomyelitis in long bones. *Am J Surg* **126**: 736-741, 1973.
126. Clawson DK, Davis FJ, Hansen ST Jr: Treatment of chronic osteomyelitis with emphasis on closed suction-irrigation technic. *Clin Orthop* **96**: 88-97, 1973.
127. Hedström SA: The prognosis of chronic staphylococcal osteomyelitis after long-term antibiotic treatment. *Scand J Infect Dis* **6**: 33-38, 1974.