

# Delayed cardiac tamponade following open-heart surgery

Jorge M. Garcia, M.D.\*  
Elmore Reyes, M.D.\*  
Chalit Cheanvechai, M.D.  
Donald B. Effler, M.D.

*Department of Thoracic and Cardiovascular Surgery*

Two types of cardiac tamponade can occur following open-heart surgery. (1) The early type is seen during the first 48 hours after an open-heart procedure. (2) The delayed or latent type, which is the subject of this report, usually occurs after the 5th postoperative day and may occur as late as 30 days postoperatively.

In our experience, early cardiac tamponade has been less serious than the delayed type. Early tamponade is often promptly diagnosed for the simple reason that it occurs during the period in which the patient is closely monitored in the cardiac intensive care unit. Furthermore, we have considerably reduced the occurrence of early tamponade because mediastinal exploration is done as soon as there is any sign of excessive bleeding in the immediate postoperative period.

Delayed or latent cardiac tamponade may occur after the patient has been transferred to a regular nursing floor or after discharge from the hospital. Recognition of delayed cardiac tamponade is extremely difficult because the signs and symptoms are often confused with other causes of a "low output state." We report our experience in the management of this challenging problem.

\*Fellow, Department of Thoracic and Cardiovascular Surgery.

### Clinical material

From January 1971 through December 1973, approximately 6,000 open-heart procedures were performed at the Cleveland Clinic Hospital. All operations were done through a median sternotomy incision. Routine cannulation included both cavae for venous drainage, aorta for arterial return, and the left atrium for decompression and left heart pressure measurement at the time of operation. Heparin was antagonized with protamine sulfate in a 1:2 ratio at the time of decannulation and closure. The pericardium was left wide open and two mediastinal plastic chest tubes were left in place and removed 48 hours after surgery. The pleural cavities were not drained unless indicated, which usually followed internal mammary artery dissection.

Eighty-three percent of the procedures were done for coronary artery disease, 14% for valve repair or replacement, and 3% for congenital defects and miscellaneous conditions. Because of immediate postoperative bleeding, 5% of the patients were returned to the operating room for exploration.

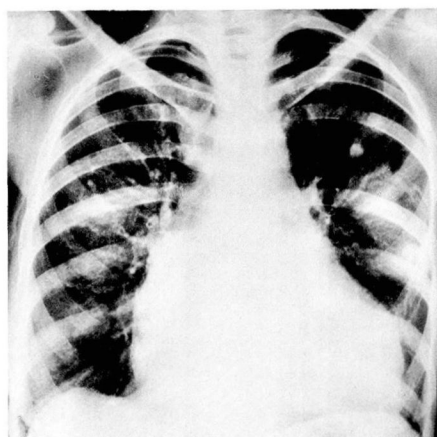
Six cases of delayed cardiac tamponade were encountered during this period. All six patients were reoperated on through the same incision, and the diagnosis of cardiac tamponade was confirmed. All survived and were subsequently discharged from the hospital.

### Case reports

**Case 1.** A 51-year-old woman with rheumatic heart disease underwent aortic and mitral valve replacements on October 21, 1971. Postoperatively, she did quite well. The chest tube drained 400 cc of

blood. Coumadin was given on the 5th postoperative day. On the 8th postoperative day, she became confused and febrile and complained of shortness of breath. Her neck veins were distended. She was given digitalis and diuretics and was treated for congestive heart failure. There was no improvement. On the 14th postoperative day, she was anemic, and an increase in the size of her cardiac silhouette was demonstrated by a roentgenogram of the chest (*Fig. 1*). Right and left cardiac catheterization was done the following day because of progressive deterioration. Central venous pressure was 22 cm H<sub>2</sub>O. A large hemopericardium with tamponade and moderate leakage around the mitral prosthesis were demonstrated. The patient underwent reoperation the following day. A large amount of serosanguineous fluid and blood clots were evacuated from the pericardium and prompt improvement in cardiac action was noted. The mitral periprosthetic leak was also repaired. Her postoperative recovery was unremarkable except for one episode of respiratory distress which was attributed to pulmonary embolism. She was treated with anticoagulants and was subsequently discharged from the hospital.

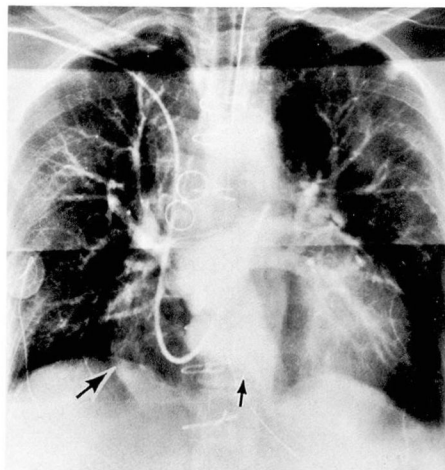
**Case 2.** A 27-year-old man with Mar-



**Fig. 1.** Chest x-ray film taken on the 14th postoperative day demonstrating an increase in the size of the cardiac silhouette.

fan's syndrome and an ascending aortic aneurysm underwent aortic valve replacement and wedge excision of an ascending aortic aneurysm on July 12, 1972. Postoperatively, the chest tube drained 1,210 cc of blood. He became febrile and complained of hoarseness, shortness of breath, and chest discomfort. He was anemic and had moderate leukocytosis. On the 4th postoperative day, a change in the size of his cardiac silhouette was observed. He was returned to the cardiac intensive care unit where his condition deteriorated. On the following day the mediastinum was explored through the same incision. Sero-sanguineous fluid gushed under pressure as soon as the sternum was reopened. Blood clots located around the root of the aorta were evacuated from the pericardial cavity. Immediate improvement in cardiac action was noticed after completion of the procedure. The patient had an uneventful postoperative convalescence and was subsequently discharged from the hospital.

**Case 3.** A 59-year-old woman with severe coronary artery disease and a history of thrombophlebitis received triple saphenous vein bypass grafts on August 28, 1972. Postoperatively, the chest tube drained 370 cc of blood. On the 2nd postoperative day, she complained of chest pain, shortness of breath, and leg tenderness. She was hypotensive and arterial blood gasses revealed moderate hypoxemia. A presumptive diagnosis of pulmonary emboli was made and heparin was administered. On the 4th postoperative day, she became febrile and had hemoptysis accompanied by a drop in hemoglobin level. This was attributed to pulmonary infarction; thus, heparin was continued. On the 10th postoperative day, she became hypotensive with marked tachycardia and elevated central venous pressure. Chest roentgenograms showed an increase in cardiac silhouette. An emergency pulmonary angiogram was performed which revealed an extensive pericardial effusion and no pulmonary emboli (*Fig. 2*). She was reoperated on through the same in-



**Fig. 2.** Pulmonary angiogram showing a large pericardial effusion (large arrow) and the left ventricle (small arrow).

cision and a large amount of liquid and clotted blood was evacuated from the pericardial cavity. Prompt improvement in cardiovascular hemodynamics resulted from this procedure. Her postoperative course was uneventful.

**Case 4.** A 63-year-old man with coronary artery disease received double saphenous vein bypass grafts on October 5, 1972. In the immediate postoperative period, excessive bleeding developed which required reoperation. The bleeding was found to be coming from the left internal mammary artery. The chest tube drained a total of 2,845 cc of blood before it was removed. On the 3rd postoperative day, the patient collapsed when going to the bathroom. He was unconscious, pulses were absent, and no blood pressure reading could be obtained. Prompt cardiac resuscitation restored his vital signs and he regained consciousness. His condition stabilized during the succeeding days; however, he was still anemic and hypotensive, and atrial flutter continued. On the 11th postoperative day, he was found without pulse or respiration. Resuscitative efforts were again successful in restoring consciousness and vital signs. Neurologic examination at this time revealed no signifi-

cant findings. He was transferred back to the cardiac intensive care unit and a central venous pressure line was inserted. It recorded a pressure of 13 cm H<sub>2</sub>O. Intravenous fluids were increased. Several hours later, mean arterial pressure dropped to 40 mm Hg and central venous pressure rose to 28 cm H<sub>2</sub>O. He was taken back to the operating room and was reoperated on through the same incision. A large amount of serosanguineous fluid and blood clots which were clearly restricting cardiac action were evacuated from the pericardial cavity. This was followed by prompt circulatory improvement. His postoperative course was unremarkable from a cardiac standpoint. He survived an acute gangrenous cholecystitis that required drainage, and massive upper gastrointestinal bleeding which responded well to conservative medical treatment. He was discharged and was doing quite well when last examined.

**Case 5.** A 38-year-old man with severe aortic regurgitation underwent aortic valve replacement on April 11, 1973. He did well in the immediate postoperative period. Drainage from the chest tube was minimal. On the 2nd and 3rd postoperative days, his temperature spiked to 103 F. This was attributed to atelectasis, since the temperature tended to drop after vigorous nasotracheal suctioning. Coumadin was begun on the 5th postoperative day. On the 9th postoperative day, a drop in hemoglobin level was noted. A roentgenogram of the chest taken at that time showed widening of the mediastinum with bilateral pleural effusion. However, his condition remained stable until the 14th postoperative day when 300 cc of old, dark blood suddenly drained from the sternal incision. A repeat chest roentgenogram showed progressive widening of the mediastinum. The patient appeared short of breath and had a rapid cardiac rate. Reoperation was performed on the same day and cardiac tamponade was found. His subsequent postoperative course was uneventful.

**Case 6.** A 58-year-old man with severe coronary artery disease received a left internal mammary artery graft to the anterior descending coronary artery and saphenous vein grafts to the circumflex and right coronary arteries on June 22, 1973. His immediate postoperative course was uneventful. On the 7th postoperative day, his temperature spiked to 101 F. This was accompanied by shortness of breath and left-sided pleuritic chest pain. A roentgenogram of the chest showed a left pleural effusion and arterial blood gasses showed severe hypoxemia. A diagnosis of pulmonary emboli was made, and heparin was begun. Four days later, there had been no improvement and a significant decrease in hemoglobin level was noted. The arterial mean pressure dropped to 50 mm Hg and the central venous pressure was recorded at 18 cm H<sub>2</sub>O. Reexploration was undertaken and cardiac tamponade was found. As soon as the bloody collection had been evacuated from the pericardial sac, the arterial mean pressure rose to 80 mm Hg and the central venous pressure dropped to 7 cm H<sub>2</sub>O. No active bleeding points were found. His recovery was uneventful.

## Discussion

Since the advent of open-heart surgery, 38 cases of delayed cardiac tamponade, including these six cases, have been reported (*Table 1*). Eighty-seven percent of these patients were receiving anticoagulants which were usually prescribed following valve surgery. The overall mortality is 18%. The mortality for the treated group is 9%; mortality of the untreated group is 100% (*Table 2*).

There is always a question of whether the administration of anticoagulants could have triggered the onset of this pathologic entity, since the majority of patients were receiving anticoagulants at the time cardiac tam-



**Table 1.** Delayed cardiac tamponade following open-heart surgery

Authors	Year	No. of cases	Anticoagulant	Mortality
Callaghan et al <sup>5</sup>	1961	2	not stated	2
Prewitt et al <sup>3</sup>	1968	2	2	1
Hill et al <sup>1</sup>	1969	7	6	1
Nelson et al <sup>6</sup>	1969	4	4	0
Engelman et al <sup>7</sup>	1970	8	8	2
Berger et al <sup>2</sup>	1971	6	6	0
Somerndike et al <sup>4</sup>	1971	3	3	1
Cleveland Clinic	1974	6	4	0
		—	—	—
Totals		38 (100%)	33 (87%)	7 (18%)

**Table 2.** Mortality of treated and untreated cases of delayed cardiac tamponade

	No. of cases	Mortality
Treated cases	34	3 (9%)
Untreated cases	4	4 (100%)

ponade occurred. Although no definite relationship exists between anticoagulation and the occurrence of delayed cardiac tamponade, the evidence seems to indicate that it does play a major role in many of the cases cited.

Diagnosis is delayed in more than half of the cases because of vague and nonspecific symptoms. Chest pain, which is very difficult to evaluate because of the presence of a surgical incision, is a frequent complaint and is probably due to pericardial irritation. Unexplained fever and anemia, with or without leukocytosis, are usually present and are probably caused by the accumulation of blood in the pericardial cavity, but clinicians tend to look for the presence of infection. Muffled heart sounds, paradoxical pulse, and electrocardiograms are not helpful. Muffled heart sounds are seldom present. Paradoxical pulse, when heard, has to be differentiated

from a paradoxical pulse of primary myocardial failure. They are never diagnostic of cardiac tamponade. Electrocardiograms are not reliable because the integrity of the pericardial sac has been violated by surgery. An expanding cardiac silhouette may be one of the early signs. Serial preoperative and postoperative chest films should be carefully reviewed when the diagnosis of delayed cardiac tamponade is suspected. Elevated central venous pressure, hypotension, tachycardia, mental disorientation, and oliguria are late manifestations of low cardiac output. The main problem lies in differentiation between the low output state of cardiac tamponade and the low output syndrome of primary myocardial failure and pulmonary embolism. This is impossible to accomplish based on symptomatology alone. Further diagnostic maneuvers are necessary to obtain the correct diagnosis.

Right and left heart catheterization and angiograms will usually rule out or establish pulmonary embolism and in many cases will demonstrate pericardial effusion and subtle intracardiac pathology. This proved helpful in two of our cases and in two cases

reported by Hill et al<sup>1</sup> where compression of the atrium and right ventricular outflow tract by blood clots were detected by this method. This diagnostic study is one of the most rewarding, especially in complicated cases.

Pericardiocentesis is often performed only to establish the diagnosis of delayed cardiac tamponade. However, Berger et al<sup>2</sup> and others<sup>3, 4</sup> have previously used this method as both diagnostic and therapeutic with some success. We feel that it should be reserved for diagnostic purposes only, and in emergency situations where the facilities for exploration are not available. In our experience, it is not only the fluid portion of the pericardial collection that causes restriction of cardiac motion, but also clots, which cannot be aspirated. Perhaps in tamponade secondary to pleuropericarditis where collection is mostly fluid, this could be primarily therapeutic.

Retrosternal exploration has been performed by Hill et al<sup>1</sup> as an emergency measure that can be done at bedside. This consists of reopening the lower part of the sternotomy incision in the subxyphoid area to explore the retrosternal space with a finger and establish drainage of the mediastinum through this route. However, this procedure, like pericardiocentesis, may miss a posterior cardiac tamponade and blood clots that accumulate in the superior portion of the mediastinum.

Formal mediastinal exploration is the safest and most effective treatment of delayed cardiac tamponade. We have had no mortality as a result of the exploration itself. The possibility of missing a posterior tamponade or

clots in the superior mediastinum is also alleviated by this method. This is the treatment we advocate and currently use.

### Summary

Delayed cardiac tamponade following open-heart surgery is usually associated with anticoagulant therapy. Differentiation from low output syndrome of primary myocardial failure and pulmonary embolism is often difficult. Constant awareness of the possibility and early use of right and left cardiac catheterization in complicated cases can lead to early diagnosis and successful therapy. If not diagnosed, the mortality is 100%. Formal mediastinal exploration is the treatment of choice.

### References

1. Hill JD, Johnson DC, Miller GE Jr, et al: Latent mediastinal tamponade after open-heart surgery. *Arch Surg* 99: 808-814, 1969.
2. Berger RL, Loveless G, Warner O: Delayed and latent postcardiotomy tamponade; recognition and nonoperative treatment. *Ann Thorac Surg* 12: 22-28, 1971.
3. Prewitt TA, Rackley CE, Wilcox BR, et al: Cardiac tamponade as a late complication of open heart surgery. *Am Heart J* 76: 139-141, 1968.
4. Somerndike JM, Hunter JA, Dye WS, et al: The late postoperative occurrence of cardiac tamponade in the open heart patient; report of three cases. *Vasc Surg* 5: 193-195, 1971.
5. Callaghan JC, Despres JP, Benvenuto R: A study of the causes of 60 deaths following total cardiopulmonary bypass. *J Thorac Cardiovasc Surg* 42: 489-496, 1961.
6. Nelson RM, Jenson CB, Smoot WM III: Pericardial tamponade following open-heart surgery. *J Thorac Cardiovasc Surg* 58: 510-516, 1969.
7. Engelman RM, Spencer FC, Reed GE, et al: Cardiac tamponade following open-heart surgery. *Circulation* 41: Suppl 11: 165-171, 1970.