

# Electrocardiographic changes during urography

Norbert E. Reich, D.O.\*

Frank E. Seidelmann, D.O.\*

Anthony F. Lalli, M.D.

*Department of Radiology*

Lon W. Castle, M.D.

*Department of Clinical Cardiology*

Ralph J. Alfidi, M.D.

*Department of Radiology*

Electrocardiographic changes have been recorded in patients undergoing a variety of roentgenographic procedures. The wide spectrum of the effects of contrast media is well known. Reports of electrocardiographic changes following the injection of the contrast medium during a urogram are surprisingly few.<sup>1, 2</sup> No large series using control groups has been reported. Berg et al<sup>2</sup> recently examined 30 patients who had urograms and found electrocardiographic changes in a significant number of these patients but no controls were studied.

We examined 115 unselected, consecutive outpatients in the Department of Radiology.

## Method

None of the patients we examined had chest pain or shortness of breath either prior to or during the examination which was performed with the patient in the supine position.

All patients had a 12-lead electrocardiogram, including a 30-second rhythm strip (lead 2), before the examination. Following the electrocardiogram, all patients were monitored up to 4½ minutes after injection or infusion of the contrast medium, at which time another

\* Fellow, Department of Radiology.

**Table 1.** Frequency of electrocardiographic changes in groups of patients studied

Group	Total no. of patients	No. of patients with history of heart disease (%)	Mean age, yr	ECG changes (%)
A—Conray bolus	27	7 (26)	56	4 (15)
B—Renografin bolus	25	10 (40)	55	7 (28)
C—Renografin infusion	13	3 (23)	56	9 (70)
D—Conray infusion	13	3 (23)	56	4 (38)
E—5% dextrose and water infusion	22	5 (23)	57	8 (36)
F—Normal saline infusion	15	5 (33)	53	0 (0)

12-lead electrocardiogram and a 30-second rhythm strip were taken. Two contrast media, Renografin-60\* and Conray 400,† and two dosage schedules were employed. Twenty-seven patients received 50 ml of Conray 400 as a bolus injection (Group A). Seven of these patients had a history of heart disease. Twenty-five patients, 10 of whom had a history of heart disease, were given a bolus injection of 50 ml of Renografin-60 (Group B). Thirteen patients received an infusion of Renografin 30% (150 ml Renografin-60 added to 150 ml sterile water; iodine content 14,376 mg/100 ml) (Group C). In this group three patients had a history of heart disease. Another 13 patients received an infusion of Conray 400 equilibrated to contain a similar iodine content as the Renografin group (110 ml Conray 400 added to 190 ml sterile water; iodine content 14,666 mg/100 ml) (Group D). This group also included three patients who had a history of heart disease. Twenty-two patients received an infusion of 300 ml of 5% dextrose and water

(Group E). Five of these patients had a history of heart disease. Our second control group comprised 15 patients who were given 300 ml of normal saline (Group F). Five patients had a history of heart disease in this group. All infusions were administered over a 5-minute period (Table 1). The osmolality of the Conray and the Renografin infusions measured 775 and 750 mOsm per liter respectively.

Electrocardiographic changes were described as minor or major using Eastwood's criteria.<sup>3</sup> All electrocardiograms were reviewed by one of the authors (L.W.C.). A complete physical examination, an electrocardiogram, and a chest roentgenogram were obtained in all cases. Some patients also had a coronary arteriogram. All patients were closely questioned about a history of heart disease. A history of rheumatic heart disease, hypertensive cardiovascular disease, and coronary artery disease were included under the heading of heart disease.

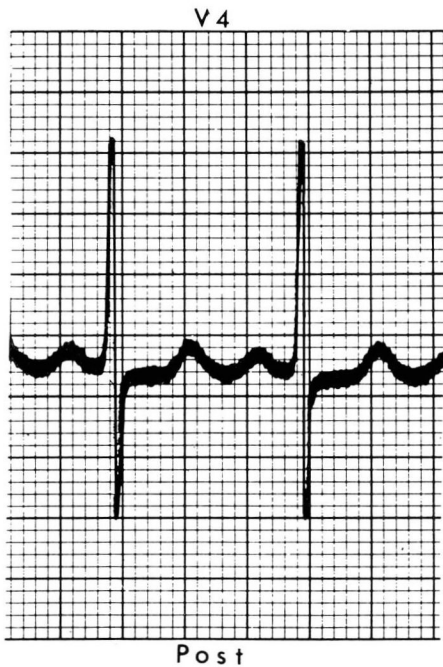
Data were analyzed by either the chi-square method or by the exact test for  $2 \times 2$  contingency table.

## Results

Major electrocardiographic changes were observed in only one patient, a

\* Renografin-60 (meglumine diatrizoate and sodium diatrizoate); Squibb, Princeton, New Jersey.

† Conray 400 (sodium iothalamate); Mallinckrodt, St. Louis, Missouri.



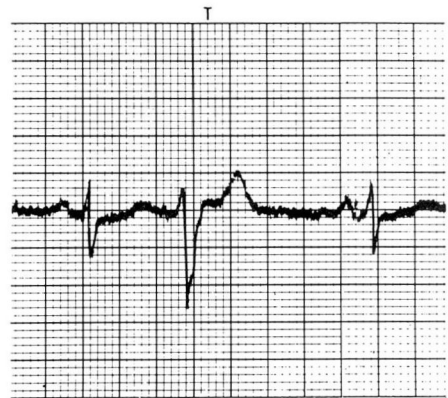
**Fig. 1.** Lead V4 shows ST segment depressions 4½ minutes after infusion of Conray 400. These changes were transient and had disappeared 10 minutes later.

67-year-old white woman with no history of heart disease. Her electrocardiogram showed ST segment depression 4½ minutes following the infusion of Conray 400 (*Fig. 1*). Electrocardiographic changes were not accompanied by chest pain. All other recorded abnormalities were minor (*Fig. 2*). No intraventricular conduction defects, bundle branch blocks, or arrhythmias, other than occasional premature atrial contractions or premature ventricular contractions were observed. Four patients experienced premature beats after application of the tourniquet, and each of three patients had a premature beat with the intravenous insertion of the needle. Thirteen of 26 patients who received infusions of contrast media showed

electrocardiographic changes; only 11 of 52 patients had changes when the bolus injection was used ( $p < 0.01$ ) (*Table 2*). Thirty-eight patients received Renografin, and 16 of these had electrocardiographic changes; only eight of 40 patients who received Conray 400 had electrocardiographic changes ( $p < 0.04$ ) (*Table 2*). Twelve of 26 patients over 60 years of age had changes; 11 of 22 patients less than 60 years showed no abnormal electrocardiographic findings. Seven of 23 patients with a known history of heart disease and 17 of 55 patients with no history of heart disease had electrocardiographic abnormalities. Thirteen patients received Conray infusions, and four of these patients had changes. Eight of 22 patients who received infusions of 5% dextrose and water had electrocardiographic changes, but no abnormalities were observed in 15 patients who were given infusions of normal saline (*Table 3*).

### Discussion

This study was undertaken because of the recent observation by Berg et al<sup>2</sup> that potentially serious electrocardio-



**Fig. 2.** Lead II shows a premature ventricular contraction that occurred with the application of the tourniquet.

**Table 2.** Frequency of electrocardiographic changes observed with different age groups, contrast media, dosages, and history of heart disease

	No. of patients	No. of patients with ECG changes (%)	Mean age, yr	Statistical significance p factor values
Infusion	26	13 (50)	55.4	p < 0.01
Bolus	52	11 (21)	55.7	
Renografin	38	16 (42)	53.8	p < 0.04
Conray	40	8 (20)	56.0	
≥60 yr	26	12 (46)	67.0	Not significant
<60 yr	22	11 (50)	48.3	
History of heart disease	23	7 (34)	59.6	Not significant
No history of heart disease	55	17 (40)	53.9	

**Table 3.** Comparison of the frequency of electrocardiographic changes with contrast agents and control solutions

Infusion	No. of patients	No. of patients with ECG changes (%)	Mean age, yr	Statistical significance p factor values
Renografin	13	9 (69)	55.1	p < 0.06
5% dextrose and water	22	8 (36)	56.5	
Conray	13	4 (38)	55.8	Not significant
5% dextrose and water	22	8 (36)	56.5	
Renografin	13	9 (69)	55.1	p < 0.0001
Normal saline	15	0 (0)	53.8	
Conray	13	4 (38)	55.8	p < 0.03
Normal saline	15	0 (0)	53.8	

graphic abnormalities may occur in patients undergoing urography, particularly with the triad of heart disease, advanced age, and infusion urography. We studied 23 patients with a history of heart disease and did not find more frequent electrocardiographic abnormalities in these patients when compared with a group of patients without a history of heart disease. We were also unable to detect more statistically significant changes in patients of advanced age. In our opinion advanced age and a history of

heart disease are not contraindications to urography.

That more electrocardiographic changes are observed during infusion urography than when a standard dose is used is borne out in our study. However, the significance of these electrocardiographic changes should be examined. We do not believe that an occasional premature ventricular or atrial contraction or transient ST segment depressions are contraindications to a roentgenographic procedure from which a great deal of informa-

tion can be obtained. Similar changes are observed daily during arteriography, in the cardiac catheterization laboratory, and in patients undergoing cardiac stress tests. These changes may not imply disease of the coronary arterial circulation; indeed, many of these patients have normal coronary arteriograms. It is possible that the electrocardiographic changes reflect a toxic effect on the myocardium. However, these changes are transient and not, in our opinion, contraindications to urography.

The mechanism by which these changes occur is not clear. Hypertonic volume load, myocardial toxicity, neurogenic stimulation, and transitory myocardial anoxia have been suggested as the possible factors responsible.<sup>4-7</sup>

We believe that the hypertonic volume load is *not* the causative factor, since similar electrocardiographic changes were observed with the use of contrast media as well as with 5% dextrose and water. In addition, the osmolality of the Conray infusion was slightly higher than that of Renografin, yet more changes occurred with the latter. Conray 400, Renografin, 5% dextrose and water, venipuncture, and the application of the tourniquet produced minor electrocardiographic changes. We, therefore, believe that myocardial toxicity cannot be implicated as the sole causative factor. Indeed, probably a combination of factors is responsible for the changes we recorded. The electrocardiographic abnormalities observed in seven of our patients with the application of the tourniquet and insertion of the needle might be explained on the basis of an increased level of anxiety in these patients. The reasonable explanation for the changes that occurred

during the infusion of the contrast media, as well as with the use of 5% dextrose and water, is an electrolyte shift at the cellular level. Five percent dextrose and water may be responsible for potassium shift into the cell which may change the membrane potential sufficiently to account for the arrhythmias. Similar electrolyte changes may occur with injections of Conray as well as Renografin. Becker et al<sup>8</sup> determined serum electrolyte values in a number of patients in renal failure and found no changes after the administration of urographic contrast material. However, these changes may be too subtle and too transient to be detected by serum analysis. They also found no rise in the serum sodium levels following the administration of pure sodium-based contrast medium. The sodium-based iothalamate contrast medium used in our study caused fewer electrocardiographic abnormalities than its methylglucamine diatrizoate counterpart.

It is our opinion that advanced age or a history of heart disease are definitely not contraindications to urography. We also believe that the electrocardiographic changes observed during urography are of no proven clinical significance.

### Summary

One hundred fifteen patients had electrocardiograms before and 4½ minutes after administration of contrast media, 5% dextrose and water, or saline. All patients were continuously monitored until the second electrocardiogram was taken. No statistically significant changes occurred when patients with a history of heart disease were compared with patients without a history of heart disease. Also, advanced age had no effect. More fre-

quent changes were recorded with infusion urography. Similar electrocardiographic changes were noted with 5% dextrose and water, Renografin-60, Conray 400, application of the tourniquet, and the intravenous insertion of the needle. We believe that the electrocardiographic changes observed are of no proven clinical significance. Heart disease and advanced age are not contraindications to urography.

### Acknowledgment

We thank J. N. Berrettoni, Ph.D., Professor of Statistics, Case Western Reserve University, for the statistical evaluation of our data.

### References

1. Klemm C, Dihlmann W: Über objektivierbare kardiotoxische sofortreaktionen nach intravenöser kontrastmittelinjektion. *Fortschr Roentgenstr* 106: 871-873, 1967.
2. Berg GR, Hutter AM Jr, Pfister RC: Electrocardiographic abnormalities and intravenous urography. *N Engl J Med* 289: 87-88, 1973.
3. Eastwood GL: ECG abnormalities associated with the barium enema. *JAMA* 219: 719-721, 1972.
4. Gensini CG, DiGiorgi S: Myocardial toxicity of contrast agents used in angiography. *Radiology* 82: 24-33, 1964.
5. Standen JR, Nogrady MB, Dunbar JS, et al: The osmotic effects of methylglucamine diatrizoate (Renografin-60) in intravenous urography in infants. *Am J Roentgenol* 93: 473-478, 1965.
6. Horger EL, Dotter CT, Steinberg I: Electrocardiographic changes during angiography. *Am Heart J* 41: 651-655, 1951.
7. Lindgren P: Hemodynamic responses to contrast media. *Invest Radiol* 5: 424-435, 1970.
8. Becker JA, Kinkhabwala M, Zolan S: Urography in renal failure; acid-base balance. *Radiology* 105: 505-507, 1972.