

Gastrosopic polypectomy

Michael V. Sivak, Jr., M.D.*

B. H. Sullivan, Jr., M.D.

Department of Gastroenterology

Tsuneoka and Uchida¹ performed the first successful endoscopic polypectomy of the stomach. Newer techniques and instruments have made fiberoptic endoscopy a therapeutic as well as a diagnostic procedure. In the United States attention is presently centered on the management of colonic polyps by these means, but the techniques are applicable to both the upper and lower gastrointestinal tracts. A solitary gastric polyp removed under direct vision by a snare and electrocautery with the fiberoptic gastroscope is reported here.

Case report

A 74-year-old man was referred to the Cleveland Clinic for treatment of a 10- to 12-cm abdominal aortic aneurysm. The history also included moderate hypertension and symptoms of benign prostatic hypertrophy. Because the patient had complained of a burning sensation in the epigastrium the upper gastrointestinal tract was examined by roentgenography. This showed a smooth rounded lesion in the antrum, thought to be a leiomyoma (*Fig. 1*). Physical findings other than the aneurysm included a blood pressure of 190/108 mm Hg, Grade II prostatic hypertrophy, and a Grade III/VI left subclavian systolic bruit.

*Fellow, Department of Gastroenterology.

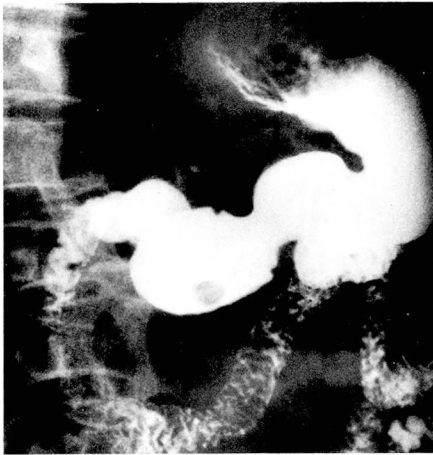

Fig. 1. Roentgenogram of stomach showing antral lesion.

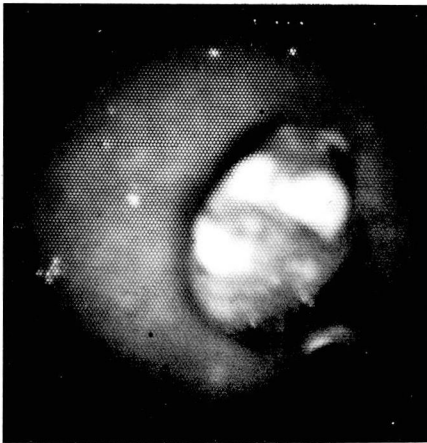


Fig. 2. Gastroscopic view of antral polyp at initial examination.

Gastroscopy was performed prior to aneurysmectomy. The cardia and fundus of the stomach were normal. A polyp approximately 0.6 cm in diameter and 1.2 cm in length was seen on the greater curvature of the midportion of the antrum. It was a deeper red than the surrounding mucous membrane, and there were two or three small areas of superficial ulceration overlying it (*Figs. 2 and 3*). The remainder of the antrum and pylorus were normal.

An abdominal aneurysmectomy was

performed using bilateral iliac Dacron graft replacement. After an uneventful postoperative course he was discharged from the hospital. Because of an increased operative risk, and because the patient was reluctant to undergo further surgery, gastroscopic polypectomy was scheduled for 3 months later.

At this time, 75 mg of mepiridin hydrochloride (Demerol hydrochloride) and 5 mg of diazepam (Valium) were administered intravenously for sedation. The ACMI Model 7089-J Fiberoptic Esophago-gastroduodenoscope was passed into the stomach without difficulty. This flexible fiberoptic instrument is end-viewing as opposed to the side-viewing type. When in use its tip can be flexed in only one plane through almost 360°. It has facilities for air insufflation, suction, and biopsy. The biopsy channel extends the length of the instrument, and many specimens can be removed with a small forceps at the end of a cable.

An experimental snare manufactured by ACMI was used to remove the polyp. The snare can be opened and closed by the operator, and when completely open it forms a loop about 5 inches in diameter. When completely closed it is withdrawn into its catheter, and can be passed through the biopsy channel of the gastro-scope. It can be connected to a device to

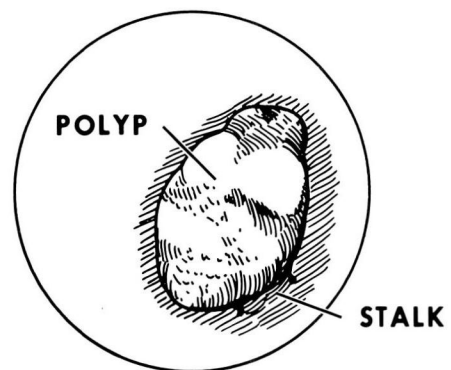


Fig. 3. Line drawing of polyp as seen gastroscopically.

supply electrocoagulating as well as cutting current.

The snare was placed over the polyp and closed. The polyp was drawn away from the wall and was seen to be pedunculated (*Figs. 4 and 5*). With the patient properly grounded by a plate beneath the buttocks, a coagulating current was applied in short bursts. Following this a cutting current was used to sever the stalk. The polyp was removed from the stomach by bringing the gastroscope close to it and applying full suction, and then removing the entire apparatus and the polyp from the stomach. The gastroscope was then re-inserted to view the pedicle, which showed no bleeding or ulceration. The specimen was an adenomatous polyp, having an oval

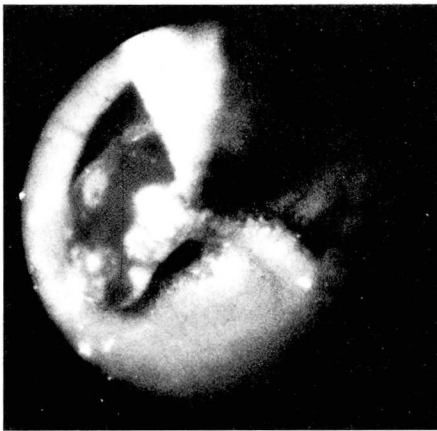


Fig. 4. Gastrosopic photograph of ensnared antral polyp.

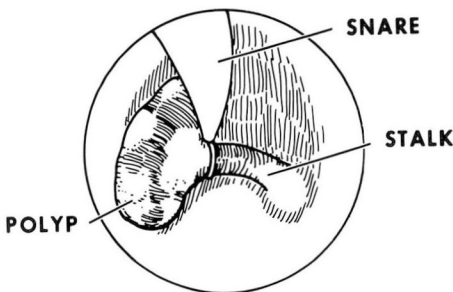


Fig. 5. Line drawing of ensnared polyp as seen gastrosopically.

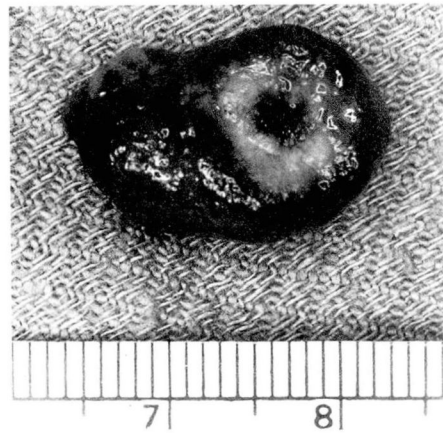


Fig. 6. Photograph of recovered specimen showing site of amputated pedicle.

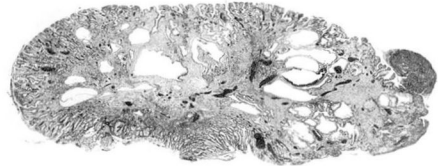


Fig. 7. Microscopic photograph of specimen.

cerebriform appearance, measuring $1.4 \times 1.2 \times 0.7$ cm (*Figs. 6 and 7*).

Comment

The technique of intragastric electrosurgery in the hands of an experienced operator has been shown with animal models to be completely controllable, with reproducible effects on the gastric mucosa.² Some investigators have reported the electrosurgical destruction of intragastric polyps,³ but we prefer to extract the polyp. Our method of extraction using suction is similar to that of Shinya. The use of a flexible forceps inserted through the biopsy channel of the instrument has also been reported.⁴ These forceps are opened and closed around the polyp, and then the gastroscope is withdrawn

There are a number of reports describing gastric polypectomy.^{1, 5, 6} In 1971 Classen and Demling⁵ reported the removal of three polyps. In a personal communication in January 1973 Classen mentioned removal of 60 polyps from the stomach, 2 containing adenocarcinomas; 2 polyps from the duodenum; and one from the jejunum.

The possible complications of the procedure include bleeding and perforation. We believe that the use of short bursts of coagulating current at the base before the use of cutting current helps to prevent bleeding. Ulcerative defects were commonly seen at the site of polypectomy in the Seifert and Elster series.⁶ The size of the defect was not related to the size of the polyp or to the current used, but to the diameter of the base of the polyp. Polyps which are completely sessile leave a larger defect than those which are clearly pedunculated. All the defects in the Seifert and Elster series healed quickly, and had a greater tendency to heal than a gastric ulcer of similar dimensions. Furthermore, the rate of healing was not influenced by treatment with an ulcer regimen including antacid. For broad-based polyps, Classen and Demling⁵ have reported injecting saline solution into the polyp base to elevate it from the gastric wall. We exercise caution in bringing the polyp well into the gut lumen before any current is used, and are less inclined to attempt removal of the more sessile types.

Whether or not gastric polyps can become true adenocarcinoma is controversial. The predominant view is that they are precancerous lesions,^{7, 8} although some investigators have dis-

puted this.⁹ A useful clinicohistopathologic classification discussed by Tomasulo⁸ divides most gastric polyps into the hyperplastic (regenerative) and the adenomatous types. Hyperplastic polyps are viewed in this framework as part of the mucosal reaction to injury, the comparisons between hypertrophic gastritis and polypoid hyperplasia are made; the adenomatous type is thought to be a true neoplasm with malignant potential.^{7, 8}

The hyperplastic type far outnumbered the adenomatous type (Tomasulo, 3 to 1; Ming and Goldman, 8 to 1). Polyps found incidentally at gastrectomy for carcinoma are seen more than twice as often as the adenomatous variety. Tomasulo⁸ also found that the adenomatous polyp is more often in the antrum (82%) as opposed to a more random distribution for hyperplastic polyps. In the several series quoted here, carcinoma in situ was found only in the polyp of the adenomatous type.

Polyps less than 2 cm in diameter have been considered nonmalignant, and this rule is probably not unfounded, although adenocarcinoma has been reported in small polyps.¹⁰ Ming and Goldman⁷ found that in their series, 80% of adenomatous polyps were larger than 2 cm, whereas only 9% of the hyperplastic or regenerative type were larger than 2 cm.

Accurate histologic classification of these polyps is necessary, especially for the polyp larger than 2 cm found in the antrum. Prior to gastroscopic electrosurgery, this was usually not possible without laparotomy. Tissue obtained by endoscopic biopsy of these polyps has been shown by Seifert and

Elster⁶ to be insufficient for accurate histologic diagnosis. In their series of 24 polyps removed from 20 patients, five biopsies of each polyp from its tip to its base were taken prior to the removal of the polyp. The histologic description of the biopsy specimens differed from that of the entire specimen in 18 of the 24 polyps.⁶

Summary

We believe that there are good reasons to consider gastroscopic polypectomy by snare and electrocautery, especially in patients at a higher than usual operative risk. These lesions may cause symptoms. Histologic classification is desirable because of possible prognostic implications of the adenomatous type. This type is more often associated with carcinoma, both in situ and carcinoma elsewhere in the stomach. The presence of such a polyp is sufficient reason for close radiologic and gastroscopic follow-up of the patient. Whether or not the adenomatous polyp can become an adenocarcinoma is still debated, but there is much evidence indicating that this may be so. We know of no accurate, satisfactory method short of removing the polyp to determine if the lesion is benign.

References

1. Tsuneoka K, Uchida T: Fibergastroscopic polypectomy with snare method and its significance developed in our department —polypectomy resection and recovery instruments. *Gastrointest Endosc (Tokyo)* **11**: 174–181, 1969.
2. Blackwood WD, Silvis SE: Gastroscopic electrosurgery. *Gastroenterology* **61**: 305–314, 1971.
3. Blackwood WD, Silvis SE: Electrosurgical destruction of a gastric polyp. *Gastrointest Endosc* **19**: 81–82, 1972.
4. Seifert E: A new flexible forceps for the removal of polyps from the gastrointestinal tract after successful endoscopic polypectomy. *Endoscopy* **4**: 226–227, 1972.
5. Classen M, Demling L: Operative gastroscopic: fiberendoskopische Polypenabtragung im Magen. *Dtsch Med Wochenschr* **96**: 1466–1467, 1971.
6. Seifert E, Elster K: Endoskopische Polypektomie am Magen. Indikation, Technik und Ergebnisse. *Dtsch Med Wochenschr* **97**: 1199–1203, 1972.
7. Ming SC, Goldman H: Gastric polyps; a histogenetic classification and its relation to carcinoma. *Cancer* **18**: 721–726, 1965.
8. Tomasulo J: Gastric polyps, histologic types and their relationship to gastric carcinoma. *Cancer* **27**: 1346–1355, 1971.
9. Monaco A, Roth SI, Castleman B, et al: Adenomatous polyps of the stomach; a clinical and pathological study of 153 cases. *Cancer* **15**: 456–467, 1962.
10. Bowden L: Adenocarcinoma in a small gastric polyp; a case report. *Cancer* **15**: 468–471, 1962.