

NEWER DEVELOPMENTS IN CHOLECYSTOGRAPHY

E. N. COLLINS, M.D., AND JOSEPH C. ROOT, M.D.

Since the introduction of cholecystography by Graham and his coworkers in 1924^{1,2}, its importance in the diagnosis of dysfunction or disease of the gallbladder has become well established, but the technique of this procedure has not yet become standardized. After countless discussions relative to the merits of the intravenous versus the oral method of administering the dye, the oral method has been adopted generally. The newer developments have been regarded with keen interest and the clinician as well as the roentgenologist, in judging the reliability of a cholecystographic examination, now insists on knowing the details of the method used. In attempting to standardize the procedure we believe the following features should be considered:

1. The administration of multiple doses of the dye produces greater density in the visualized gallbladder than does the single dose, and it makes non-visualization of greater significance, without harming the patient.

2. The administration of large amounts of sugar and other carbohydrates preceding and during the examination facilitates the excretion of the dye by the liver, thereby adding greater significance to the cholecystographic findings.

3. One ounce or less of a mixture of egg yolk, lecithin, and glycerine, as recommended by Levyn³, has been found to be as efficacious as the fat meal in emptying the gallbladder, and it has not interfered with the roentgen examination of the stomach and small intestine on the same day that the cholecystograms are made. Figure 1 shows a small opaque calculus in the gallbladder area, which, at this time, cannot be excluded as an opaque calculus. This patient was given 4 drams of the lecithin mixture and the second film was made one-half hour later. Figure 2 shows the gallbladder in a contracted state with the suspicious shadow outside the gallbladder area.

4. The use of pitressin⁴ in the elimination of confusing shadows in that part of the intestinal tract which may lie over the area of the gallbladder has precluded the necessity for reexaminations in such instances. It has also made possible the use of the multiple dose oral method of cholecystography on the same days that the barium meal examinations of the stomach and small intestine, or the barium enema examinations of the colon are made.

Sandström^{5,6} introduced the "multiple" or "fractionated" method of cholecystography. He stated that "phenolphthalein preparations once

introduced into the system circulate for a rather long time in an entero-hepatic cycle. After being eliminated through the liver and its intermediary, the bile, they are reabsorbed through the intestines and so on. By introducing orally during each phase of the cycle additional small

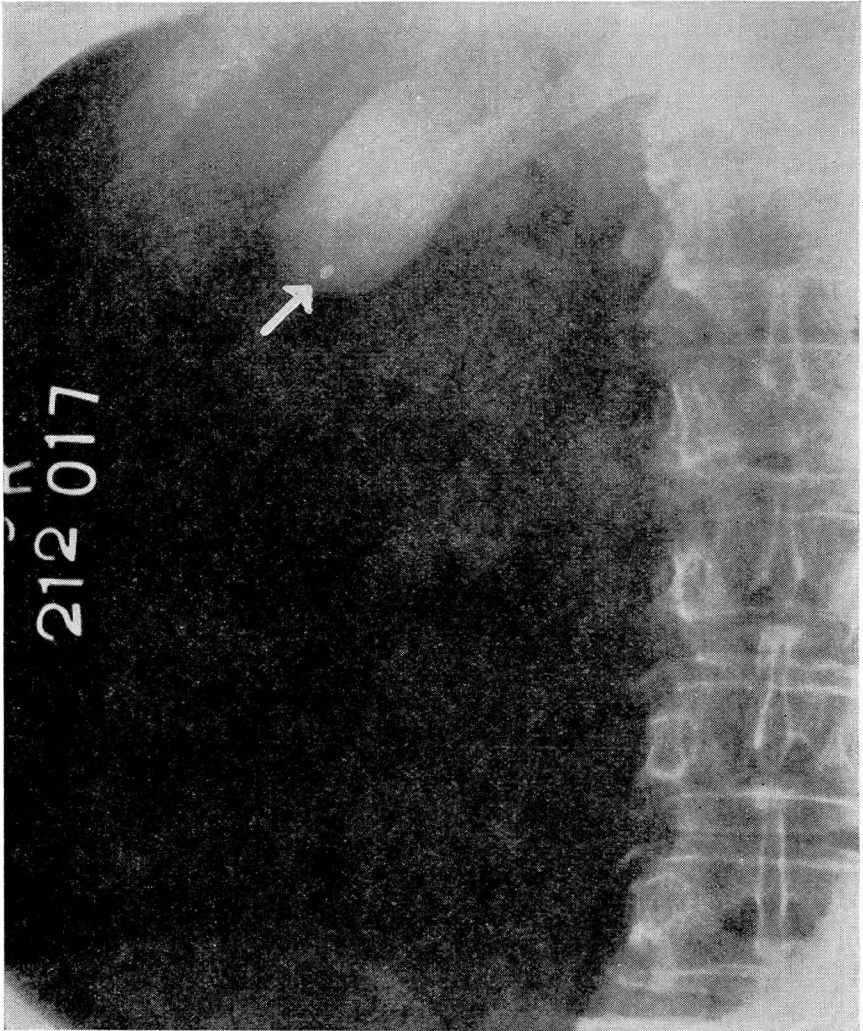


FIGURE 1: Questionable opaque calculus in the gallbladder region.

doses of the salt one may obtain a more complete absorption.” In making a gastro-intestinal series examination following cholecystography, roentgenologists had frequently noticed the re-visualization of the gallbladder 30 or 40 hours after the administration of the dye and were ready to accept this statement. Sandström administered orally 7 to 10 grams of sodium tetraiodophenolphthalein in two or three divided

NEWER DEVELOPMENTS IN CHOLECYSTOGRAPHY

doses, allowing 2 or 3 days for the cholecystographic examination, and he found that greater absorption, resulting in greater density of the visualized gallbladder, was obtained without harm to the patient.

In 68 cases, Blomström and Sandström⁷ supplemented cholecystography with the bromsulphalein test as a means of determining liver

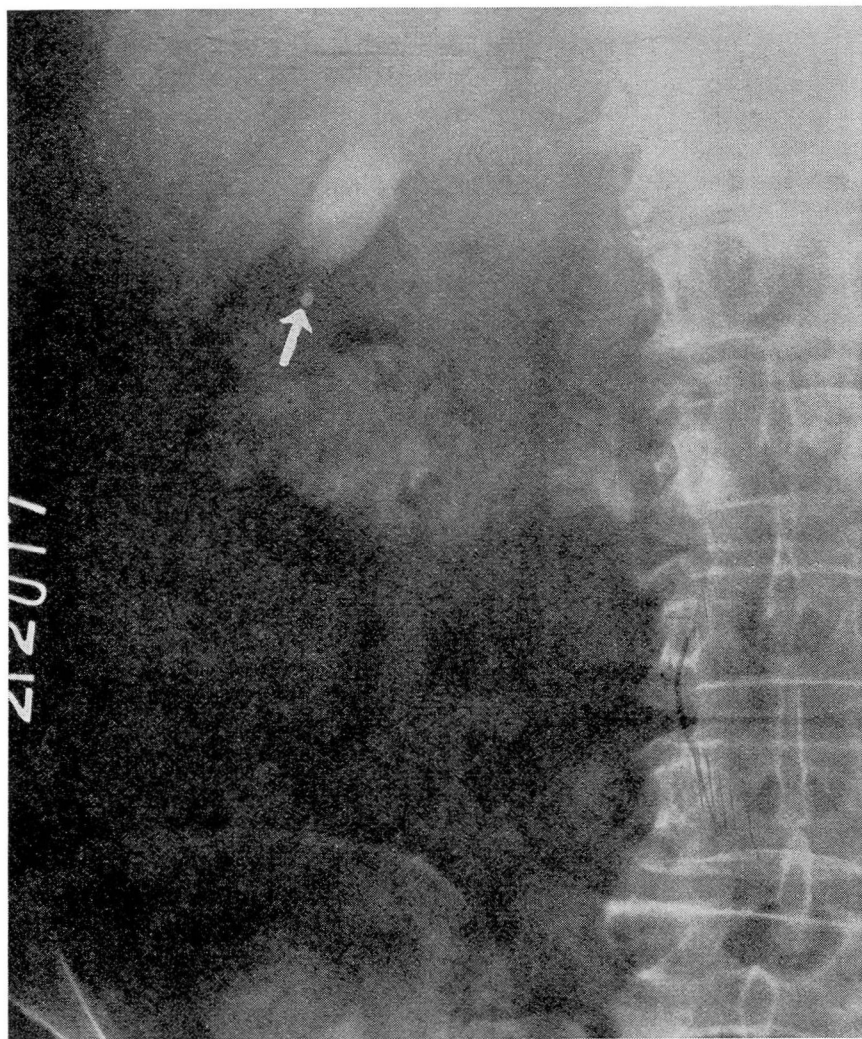

FIGURE 2: The gallbladder contracted after administration of lecithin mixture, throwing opaque shadow out of this region.

function in the event of non-visualization of the gallbladder by cholecystography. A high retention of bromsulphalein, over 40 per cent, excluded the possibility of visualization of the gallbladder because of liver damage, while a low retention, below 25 per cent, indicated that obstruction was located outside the liver parenchyma.

Sandström apparently allowed the patient to eat a mixed diet between the divided doses of the dye and so made no attempt to prevent emptying the gallbladder. Since carbohydrates had been shown to have no effect on the emptying time of the gallbladder in man⁸, Whitaker and Ellsworth⁹ modified the Sandström method by giving only carbohydrates between the two doses used in their "double oral" method. Whitaker¹⁰ has since advocated that another carbohydrate meal be followed by a "third" dose of the dye if the roentgenograms at the end of 20 hours show no visualization of the gallbladder.

In his "rapid" cholecystography, Antonucci¹¹ demonstrated the value of using glucose with the intravenous method. Ten minutes after the intravenous injection of 125 cc. of a 40 per cent solution of glucose, the dye was injected. This, in turn, was followed by the subcutaneous injection of 24 units of insulin. Visualization of the gallbladder was usually obtained within half an hour following the injection of the dye, and the maximum intensity was reached in 2 hours. It was Antonucci's opinion that glucose played an important part in the utilization of the dye and that the absorption of the dye in the liver necessitated the presence of glucose either in the blood stream or as converted from glycogen in the tissues, if the former became exhausted.

Graham, in 1933¹², demonstrated the value of combining intravenous cholecystography with determination of liver function, by use of the dye "iso-iodoikon" (sodium phenoltetraiodophenolphthalein). He found that a knowledge of the amount of this dye which was excreted by the liver was important in estimating the risk of performing operations on the biliary tract. In addition, it was of assistance in the interpretation of cholecystograms. By delaying operations until the proper medical treatment resulted in a reduction of high dye retentions to normal, the accuracy of the interpretation of cholecystographic findings was increased and the mortality rate for operations on the biliary tract was materially reduced.

Stewart and Illick^{13,14} in their "intensified" oral cholecystography combined the fractionated method of administration of the dye with the administration of large amounts of sugar to facilitate the excretion of the dye by the liver, allowing only carbohydrate foods until noon of the third day when a fat meal was given to empty the gallbladder.

THE USE OF PITRESSIN DURING CHOLECYSTOGRAPHY

One of the handicaps to accurate interpretation of cholecystograms is the presence of confusing densities, such as gas shadows, in the intestinal tract. Repeated examinations may be necessary before an accurate diagnosis can be made. In our experience, the use of cathartics and enemas has proved not only inadequate but it has actually resulted in greater

NEWER DEVELOPMENTS IN CHOLECYSTOGRAPHY

difficulties than were present before their administration. We have found the use of pitressin, the pressor fraction of posterior pituitary extract, very effective in solving this problem, and its use is a simpler procedure, requires less time, is less troublesome to the patient, particularly if the patient is not in a hospital, and it has not been attended by unpleasant reactions. However, because of its stimulating effect on the musculature of the gastro-intestinal tract as well as its vasoconstrictor effects, it has not been used when there is danger of perforation or mechanical obstruction in the gastro-intestinal tract or where there is evidence of cardiovascular disease. We do not use pitressin in the presence of advanced hypertension, and since we have noted a drop in blood pressure in 50 per cent of our cases in which it has been used, it is not given to a patient whose systolic blood pressure is below 100 mm. of mercury.

In a series of 1250 cholecystographic examinations, the use of pitressin was considered advisable in 200 cases, or 15 per cent. Effective results, i. e., the elimination of confusing shadows in the intestinal tract, were obtained in 87.5 per cent of these cases. In 76 per cent there were one or more stools within 30 minutes. In a more recent series of cases, in which the new ampoule containing 20 pressor units has been used, effective results have been obtained in 90 per cent of the cases.

The technique is merely the intramuscular (deltoid) injection of one ampoule of pitressin when the cholecystograms show confusing shadows in the intestinal tract. One hour later, additional cholecystograms are made. There has been no interference with roentgen examination of the stomach, small intestine or colon on the same day that pitressin is used. It is now employed routinely whenever there are confusing shadows in the intestinal tract, provided the contraindications mentioned are not present.

Figure 3 illustrates a case in which the second dose of dye was given the night following the routine examination of the stomach. It will be noted here that the entire gallbladder area is obscured by barium in the colon and no information about the function could be obtained by this cholecystogram. This patient was given 1 cc. of pitressin and a second film was made 45 minutes later. The barium was evacuated from the colon and we are now able to see in figure 4 a normally functioning gallbladder.

COMMENT

The diagnosis of cholecytic disease is usually simple when the patient gives a history of repeated attacks of biliary colic, particularly if these are associated with jaundice. In such instances, objective roentgen evidence for confirmation is obtained by cholecystography. In inflammatory diseases of the gallbladder, the physical examination usually

offers no assistance unless the patient is examined during the acute or subacute phase of the process.

In the absence of a history of biliary colic, accurate diagnosis may not be possible without cholecystography as well as the roentgen examination

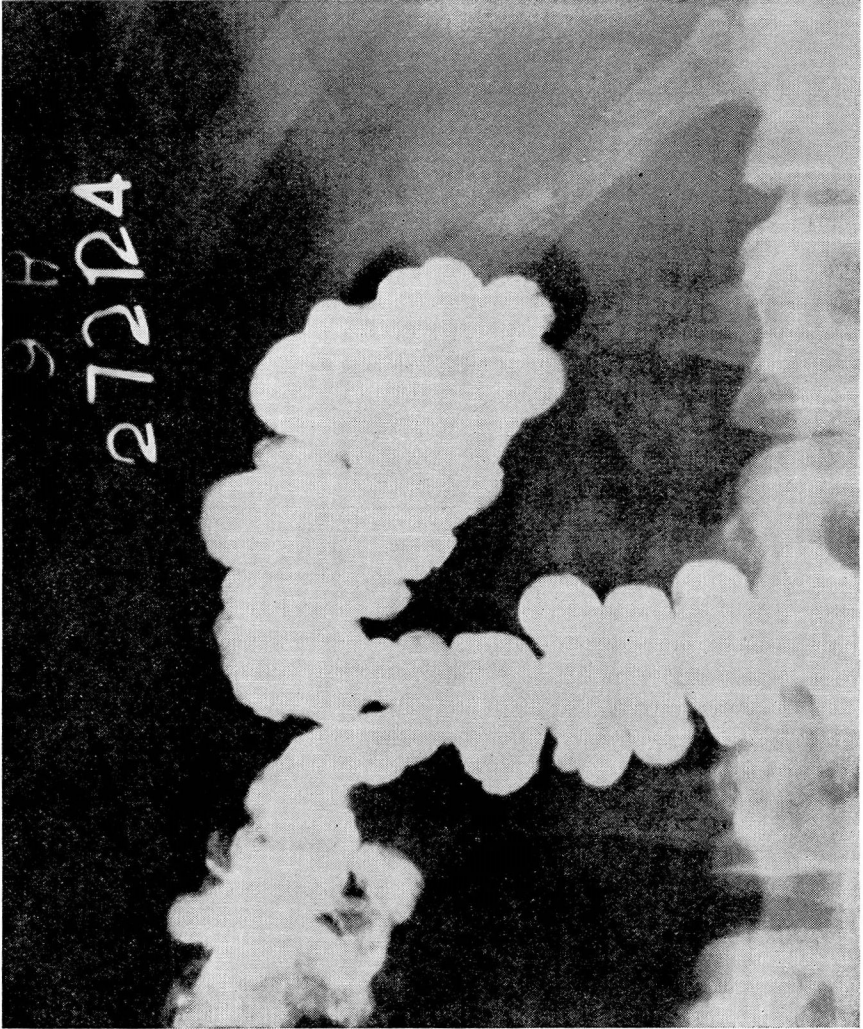


FIGURE 3: Gallbladder region obscured by barium in the colon.

of all organs which may cause symptoms simulating biliary disease. Nichols¹⁵ has repeatedly emphasized the fact that since the sympathetic nervous system, through the superior and inferior mesenteric ganglia, receives fibers not only from the gallbladder, but also from the stomach, duodenum, right kidney, ureter, and colon, pain or distress in the right upper quadrant of the abdomen may be due to abnormality in any one or

NEWER DEVELOPMENTS IN CHOLECYSTOGRAPHY

several of these organs. The interpretation of so-called gallbladder dyspepsia or gaseous dyspepsia, as described in textbooks, when it is not associated with definite attacks of biliary colic, is open to question. Although patients who give a history of biliary colic, often have functional disturbances in the gastro-intestinal tract, Palmer¹⁶ believes that, in the absence of this history, so-called gallbladder dyspepsia is in

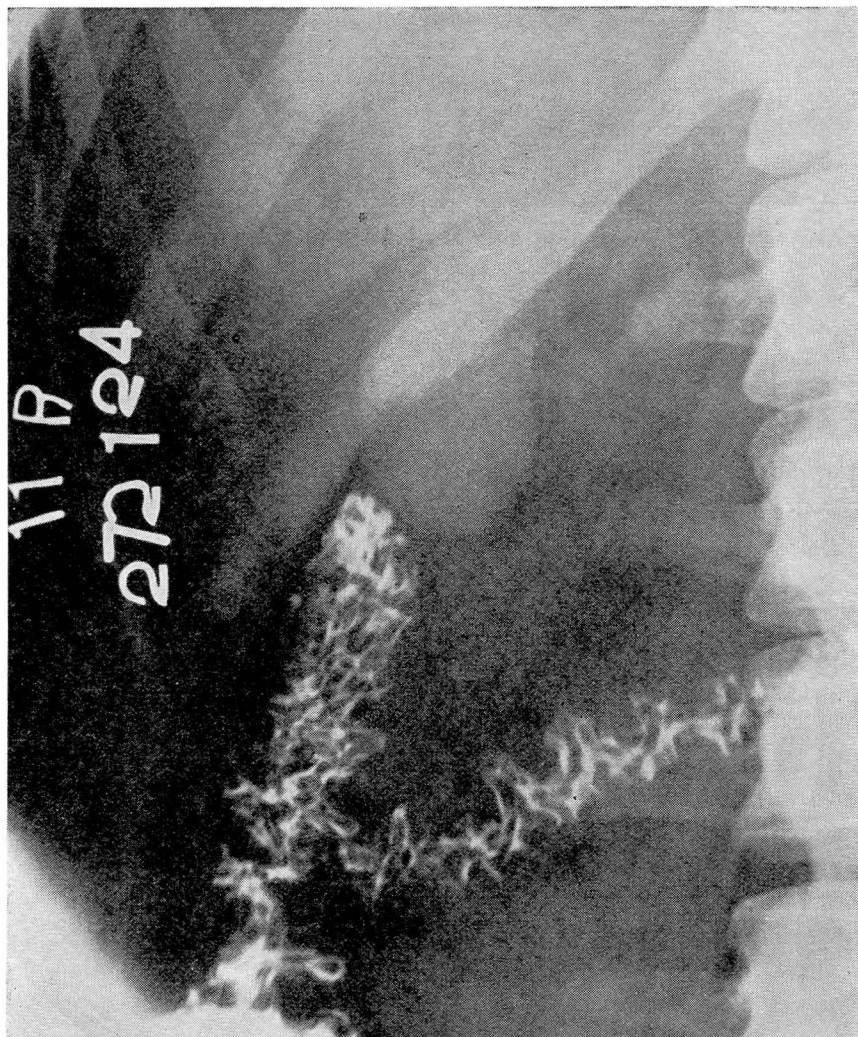


FIGURE 4: The normally functioning gallbladder visualized after administration of pitressin. reality independent of the gallbladder and that it is not unlike the dyspepsia which occurs in patients who are not afflicted with cholecystic or other forms of organic disease. Our experience, also, leads to a similar conclusion. In instances where an indeterminate history is given, we

believe the roentgen examination of adjacent organs is equal to if not of greater importance than cholecystography alone.

The diagnosis of cholecystic disease can be made from the cholecystographic evidence alone, regardless of the symptoms, when it reveals the presence of gall stones, calcific deposits in the wall of the gallbladder, opaque bile in the gallbladder due to the presence of calcium carbonate bile^{17,18}, or of neoplasms¹⁹ in the gallbladder. But, unless there is a suggestive history for these findings, care should be used in attributing the presenting symptoms of the patient to these causes without excluding abnormality in adjacent organs.

Although it is generally agreed that biliary disease is the most common *organic* cause of chronic gastro-intestinal symptoms in a middle-aged person, and since routine autopsies, both in this country and abroad^{20,21}, show that more than half the adults past 30 years of age had abnormal gallbladders and that approximately 20 per cent had gall stones, the relatively low incidence of previous clinical evidence of biliary disease in these cases makes one question the advisability of prescribing surgery on the basis of cholecystographic evidence alone²². It is well known that the best results from surgery of the gallbladder are obtained in those patients who have had definite biliary colic, and operations on the biliary tract are now seldom advised unless there is positive clinical as well as cholecystographic evidence.

METHOD

In patients who give a history highly suggestive of biliary colic, we obtain confirmatory evidence by making a cholecystographic examination by the oral method, and this is combined with a roentgen examination of the stomach and duodenum to exclude the possibility of a penetrating ulcer in the posterior wall of the duodenum which may cause symptoms suggestive of biliary disease. Plain films of the urinary tract are made at the time the preliminary plain films of the gallbladder region are made. If the roentgen findings in the urinary tract are positive or suggestive of abnormality, the patient is referred to the Department of Genito-Urinary Diseases for further examination before cholecystography is completed. Intravenous or retrograde pyelography may be indicated since there may be abnormality in the urinary tract as well as in the gallbladder, or the symptoms actually due to the former may be highly suggestive of the latter. When the plain roentgenograms of the urinary tract show no abnormality, the examination is limited to cholecystography and the roentgen examination of the stomach and duodenum, as mentioned.

NEWER DEVELOPMENTS IN CHOLECYSTOGRAPHY

In the much larger group of patients who give an indefinite history of digestive disturbances, motility studies of the intestine as well as barium enema examinations of the colon are added to the procedures mentioned above. The details of these examinations have been described^{23,24}. This method was adopted by Nichols twelve years ago and the same procedures are used today.

In view of the fact that methods used in cholecystography are still not standardized, we believe the most practical method and the economic status of the patient, at least as it pertains to the time factor, are important considerations. Undoubtedly the fractionated or multiple dose method is the ideal procedure *per se*, but the single dose method, when combined with the roentgen examinations mentioned, has been found adequate in at least 90 per cent of our cases. When the cholecystographic findings result in non-visualization of the gallbladder or questionable findings, we administer a second dose of the dye the second night and this is combined with a continued high carbohydrate intake. If the cholecystograms the next morning show confusing shadows in the intestinal tract, pitressin is used. Barium studies of the stomach and small intestines are made in the meantime and as soon as the cholecystograms following the second dose of dye are satisfactory, a barium enema examination of the colon follows. In the time required to complete the fractionated method of cholecystography alone, we are able to make roentgen examinations of the urinary tract, using the single or double oral method of cholecystography, and at the same time to complete the roentgen examinations of the stomach, small intestine and colon.

RESULTS

The evaluation of cholecystography is of course difficult, because relatively few of the patients in whom these examinations are made have abdominal operations. However, our operative findings during the past five years have coincided with the cholecystographic findings in either a positive or negative way in 95 per cent of the cases. In a series of 100 consecutive patients having abdominal operations, the cholecystographic findings were in error in 7 cases, an accuracy of 93 per cent from both the positive and negative standpoint. These examinations were made before the double dose oral method was used in cases presenting questionable findings, the single dose oral method having been employed in all these cases. The occasional use of a second dose of dye since that time is responsible for the accuracy of diagnosis mentioned previously. The

E. N. COLLINS AND JOSEPH C. ROOT

following table is a summary of the cholecystographic and pathologic findings in parallel groupings:

<i>Cholecystographic Findings</i>	<i>Number of Cases</i>	<i>Pathologic Findings</i>	<i>Number of Cases</i>
Normally functioning gallbladder without stones (negative).....	4	Chronic cholecystitis (mild) without stones.....	3
		stone in cystic duct.....	1
Gall stones in a non-visualized gallbladder	21	Chronic cholecystitis with stones	21
Gall stones in a poorly visualized gallbladder	22	Chronic cholecystitis with stones	21
		without stones	1
Gall stones in a normally functioning gallbladder	22	Chronic cholecystitis with stones	21
		without stones	1
Non-visualization of gallbladder		Chronic cholecystitis	
No opaque stones	27	with stones	21
		without stones	5
		grossly normal	1
Poorly visualized gallbladder without stones	4	Chronic cholecystitis (no stones)	4
Total.....	100	Total.....	100

In a consideration of the errors, there were four cases on the negative side in which normal cholecystographic findings had been obtained and little gross evidence of abnormality of the gallbladder was found at operation, but the microscopic diagnosis was chronic cholecystitis. In three of these, there were no stones. In the fourth case there was a stone in the cystic duct but none in the gallbladder. The clinical significance of a microscopic diagnosis of mild chronic cholecystitis in the absence of definite gross pathologic changes is disputed by many authorities.

On the positive side, a diagnosis of gall stones was made in two instances but operation did not confirm this; however, pathologic gallbladders were found. One of these two patients had a poorly visualized gallbladder which apparently indicated diminished function. The other positive diagnostic error was in a case of non-visualization of the gallbladder where the gallbladder at operation was grossly normal. This patient had a definitely pathologic appendix.

It will be noted that stones which were nonopaque to x-rays were present in 78 per cent of the cases in which the gallbladder was not visualized.

EVALUATION OF CHOLECYSTOGRAPHIC FINDINGS

Statistics relative to the value of cholecystography are usually based on operative findings. In most instances, positive clinical as well as

NEWER DEVELOPMENTS IN CHOLECYSTOGRAPHY

cholecystographic evidence of cholecystic disease exists before operation^{24,25}. Kirklin and Blake²⁶ have recently summarized the cholecystographic evidence in patients who have not had abdominal operations but who have had a final clinical diagnosis of cholecystic disease and they find that the cholecystographic data coincide with the clinical diagnoses in approximately 90 per cent of the cases, a figure which is nearly equal to that found in patients having operations.

A normally visualized gallbladder may be pathologic. It would seem logical to believe that the routine use of the multiple dose method of administering the dye would increase this error which has been estimated to be 10 per cent^{24,25} while the use of the smallest possible adequate dose should decrease this error. It should not be forgotten that pathologic gallbladders which are filled with stones commonly function with the cholecystographic dye. However, we are convinced that if the cholecystographic findings are normal, convincing clinical evidence is required to justify surgical interference.

Non-visualization of the gallbladder by cholecystogram without evidence of opaque calculi usually indicates a nonfunctioning gallbladder containing nonopaque (cholesterin type) stones with blocking of the cystic duct. But consideration must be given to the possibility of other causes of non-visualization, such as diseases of the liver or diseases in adjacent organs which may cause reflex disturbance in the dye-concentrating ability of the gallbladder or dysfunction in the sphincter of Oddi, at least at the time the examination is made. Non-visualization does not necessarily indicate a pathologic gallbladder, and such a diagnosis should not be made unless there is a suggestive history of biliary disease and all other causes for the symptoms have been excluded by a complete roentgen examination. It is in these instances that the multiple dose method of administering the dye, combined with a large intake of sugar, is definitely indicated. Added doses at each phase of the enterohepatic cycle usually are more effective than a re-check single dose examination at a later date, unless there is abnormality outside the biliary tract causing reflex disturbances which are relieved in the meantime.

CONCLUSIONS

1. Our operative findings during the past five years have coincided with the cholecystographic findings in either a positive or negative way in 95 per cent of the cases.
2. The multiple dose method of administering the dye is particularly indicated when the cholecystograms following the single dose method result in non-visualization of the gallbladder or when the findings are

indeterminate. However, in our experience the single dose method has been found adequate in at least 90 per cent of cases.

3. The use of pitressin has been found effective in the elimination of confusing shadows in the intestinal tract. Its use has precluded the necessity for re-examinations and has made possible the use of the multiple dose oral method of cholecystography at the same time that the roentgen examinations of the stomach, small intestine, and colon are made.

REFERENCES

1. GRAHAM, E. A. AND COLE, W. H.: Roentgenologic examination of gallbladder, new method utilizing intravenous injection of tetrabromphenolphthalein, J. A. M. A., 82:613-614, (February 23) 1924.
2. GRAHAM, EVARTS A., COLE, W. H. AND COPHER, GLOVER H.: Visualization of gallbladder by the sodium salt of tetrabromphenolphthalein, J.A.M.A., 82:1777-1778, (May 31) 1924.
3. LEVYN, L.: Effective gallbladder stimulant to supplant fat meal, Am. J. Roentgenol., 26:904, (December) 1931.
4. COLLINS, E. N. AND ROOT, J. C.: Elimination of confusing gas shadows during cholecystography by use of pitressin, J.A.M.A., 107:32, (July 4) 1936.
5. SANDSTRÖM, C.: Eine verbesserte Administrationsweise bei den peroralen Cholezystographie (mittels wiederholter Verabreichung des Kontrastsalzes), Acta radiol., 12:8-22, 1931.
6. SANDSTRÖM, C.: De la cholécystographie par voie buccale et de sa valeur, J. de radiol. et d'électrol., 16:358-359, (August) 1932.
7. BLOMSTRÖM, H. AND SANDSTRÖM, CARL: On cholecystography in cases of impaired liver function, Acta chir. Scandinav., 71:135-149, 1932.
8. SOSMAN, M. C., WHITAKER, L. R., AND EDSON, P. J.: Clinical and experimental cholecystography, Am. J. Roentgenol., 14:495-503, (December) 1925.
9. WHITAKER, L. R. AND ELLSWORTH, S. W.: Improved oral method for cholecystography, New England J. Med., 205:1183-1186, (December 17) 1931.
10. WHITAKER, LESTER R.: "Double-oral" method for cholecystography, Am. J. Roentgenol., 35:200-203, (February) 1936.
11. ANTONUCCI, CESAR: La cholécystographie rapide, Presse méd., 40:983-986, (June 22) 1932.
12. GRAHAM, E. A.: Estimating risk of operations on biliary tract by testing excretory function of liver, Radiology, 21:191-194, (August) 1933.
13. STEWART, W. H. AND ILLICK, H. E.: Intensified oral cholecystography; preliminary report, Am. J. Digest. Dis. & Nutrition, 1:337, (July) 1934.
14. STEWART, W. H. AND ILLICK, H. E.: Advantages of intensified oral cholecystography, Am. J. Roentgenol., 33:624-629, (May) 1935.
15. NICHOLS, BERNARD H.: Differential diagnosis in gallbladder disease, M. Clin. North America, 17:1059-1069, (January) 1934.
16. PALMER, W. L.: Gallbladder disease; remarks on symptoms, diagnosis, and treatment, Internat. Clin., 1:111-123, (March) 1935.
17. KORNBLUM, KARL AND HALL, WENDELL C.: Roentgenologic significance of "milk of calcium" bile, Am. J. Roentgenol., 33:611-623, (May) 1935.
18. ROOT, JOSEPH C.: Calcium carbonate bile, Cleveland Clin. Quart., 4:45-51, (January) 1937.
19. KIRKLIN, B. R.: Cholecystographic diagnosis of neoplasms of gallbladder, Am. J. Roentgenol., 29:8-16, (January) 1933.

NEWER DEVELOPMENTS IN CHOLECYSTOGRAPHY

20. CRUMP, C.: Incidence of gall stones and gallbladder disease, *Surg. Gynec. & Obst.*, 53:447-455, (October) 1931.
21. MENTZER, S. H.: Clinical and pathologic study of cholecystitis and cholelithiasis, *Surg. Gynec. & Obst.*, 42:782-793, (June) 1926.
22. BLACKFORD, J. M., KING, R. L., AND SHERWOOD, K. K.: Cholecystitis; study based on follow-up after from 5 to 15 years of 200 patients not operated on, *J.A.M.A.*, 101:910-913, (September 16) 1933.
23. COLLINS, E. N.: Cholecystography, *Cleveland Clin. Quart.*, 2:16-22, (July) 1935.
24. COLLINS, E. N.: *Oxford Monographs on Diagnosis and Treatment, Diseases of the Liver and Biliary Tract*, New York, Oxford University Press, 8:58-68, 1936.
25. KIRKLIN, B. R.: Persisting errors in technic of oral cholecystography; procedure designed to avoid them, *J.A.M.A.*, 101:2103-2105, (December 30) 1933.
26. KIRKLIN, B. R. AND BLAKE, T. W.: Cholecystic disease; comparison of clinical with cholecystographic data concerning 500 patients not operated on, *J.A.M.A.*, 105:1416-1419, (November 2) 1935.