

## THE CORRECTION OF SCOLIOSIS BY USE OF A MODIFIED TURNBUCKLE JACKET

J. I. KENDRICK, M.D.

The treatment of scoliosis in all its degrees has presented to the orthopaedic surgeon one of his most difficult problems. Treatment in the early and milder cases of lateral deviation of the spine has been more successful than in the severe cases with marked deviation and fixed deformity where less satisfactory results have been obtained. The more severe and the more fixed the deformity, the more drastic must be the treatment. The problem presented by the correction of these more severe cases has interested me and a modification of the turnbuckle jacket has been devised in an effort to secure more satisfactory results.

Much has been accomplished during the last forty years in the treatment of the patient with severe scoliosis and an impetus for the development of more satisfactory methods has come from the better understanding of the pathogenesis of scoliosis as well as the realization that a very good degree of correction can be obtained. Bradford and Brackett<sup>1</sup>, Lovett and Brewster<sup>2</sup>, Abbott<sup>3</sup>, Forbes<sup>4</sup>, and Galeazzi<sup>5</sup> were the earlier workers whose methods of correction gave such encouraging results that other applications of their principles have been developed and still better results are being obtained.

The curving spine has been shown invariably to undergo a change due to torsion and this is spoken of as rotation. It is this torsion change which accounts for so much of the deformity. As the rotation occurs, the ribs are carried backward on the convex side of the curve and forward on the concave side of the curve with resulting asymmetry and deformity. The recognition of this rotation and the application of a derotating force has aided greatly in the correction of severe curves.

Traction on the spine was one of the earliest forces applied for correction. In the fixed curved spine, a traction force sufficient to move the curve was unbearable to the patient, but it has always been recognized that such a force, though moderate, is of value. This force stretches the contracted muscles and ligaments and distracts the articulations and when constant, even though moderate, has a definitely corrective effect. Using the ends of the curve as fixed points and the apex as a fulcrum, a more powerful force can be applied and a force which the patient tolerates well. This force has been utilized in many of the corrective methods but has not been applied as constantly and as accurately as in the case of the turnbuckle jackets described by Risser<sup>6</sup> and Brewster<sup>7</sup>.

Various workers have used the turnbuckle principle with very good results but no consideration has been given to the increased

## THE CORRECTION OF SCOLIOSIS

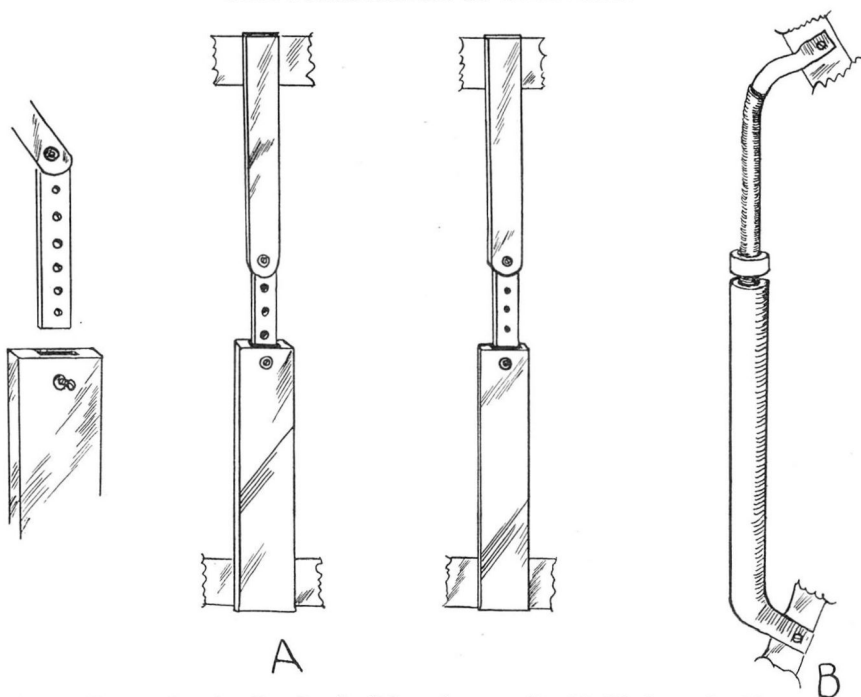


FIGURE 1: A. Detail of sliding hinge. B. Modified turnbuckle.

length of the spine as the curve is straightened. In using a fixed hinge in the jacket, there is a jamming effect upon the bodies and the articulations as this increase in length develops and progress in correction becomes slow or ceases. Garceau<sup>8</sup> pointed out the advantage of the addition of a traction force to the hinge so that, as the spine increases in length as the turnbuckling progresses, the jacket accommodates for it. Following this suggestion, a hinge was designed (Fig. 1) with a sliding collar in order that a degree of distraction can occur as the turnbuckle is advanced. By this means, a degree of traction on the spine is maintained and the jacket is lengthened to accommodate it to the lengthening spine.

The general principles of the jacket (Figs. 2 and 3) are in accordance with those of the Risser jacket but, with the addition of the traction hinge, a few modifications have been found necessary. The jacket may be thought of as comprising two segments—the one controlling the upper end of the curve and the other the lower end. The more accurate the control on these segments, the more effective will be the corrective force applied. To gain this control, the plaster is extended down over the arms for a short distance and it is applied to both thighs with the legs in considerable abduction. With the jacket applied in this fashion, the traction gained as the hinge distracts is transmitted to the spine and is not

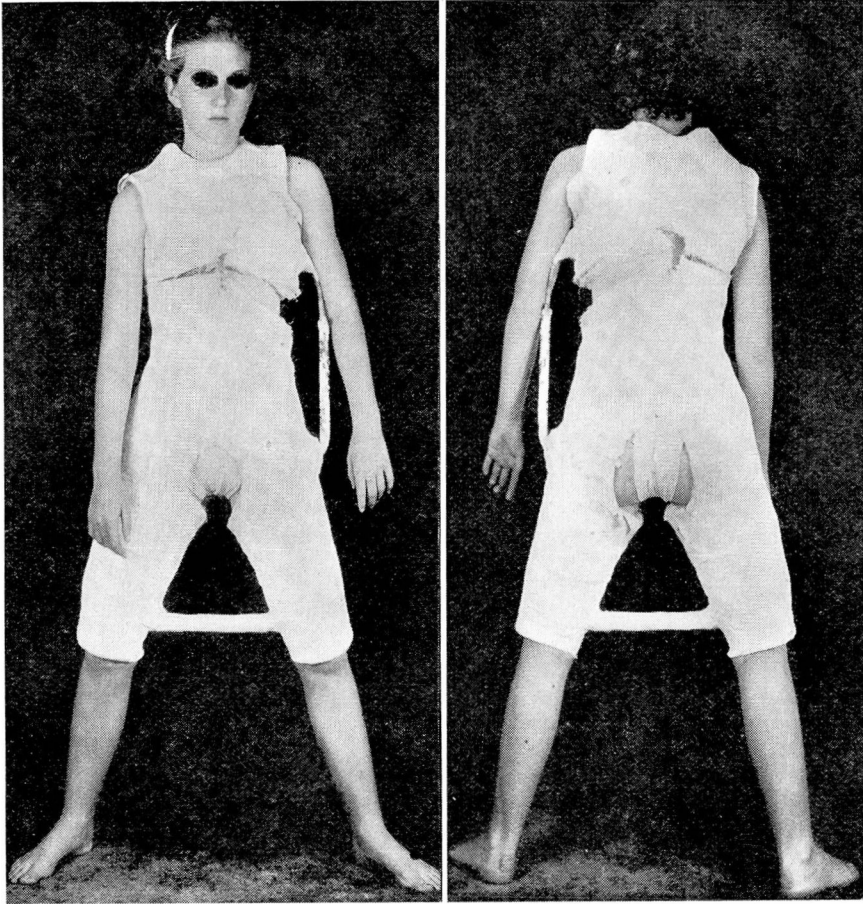


FIGURE 2: The modified turnbuckle jacket.

lost by the plaster merely sliding down the leg. In the low dorsal and in the lumbar curves, the arm cuffs have not been necessary. In the high dorsal curves it has been found necessary to incorporate a collar.

The jacket is applied in one piece with the patient standing and with a moderate degree of head traction. This traction improves the contour of the body and accomplishes that degree of correction which can be gained easily. Great care must be taken to pad the points of pressure thoroughly. The jacket should be made quite sturdy as the period of correction may extend over 6 or 8 weeks. After the first layers of plaster have set, the hinges and turnbuckle are incorporated, using sufficient plaster to anchor them securely because they often loosen due to frequent turning of the patient, and they can never be reapplied as securely as at first. When the



## THE CORRECTION OF SCOLIOSIS

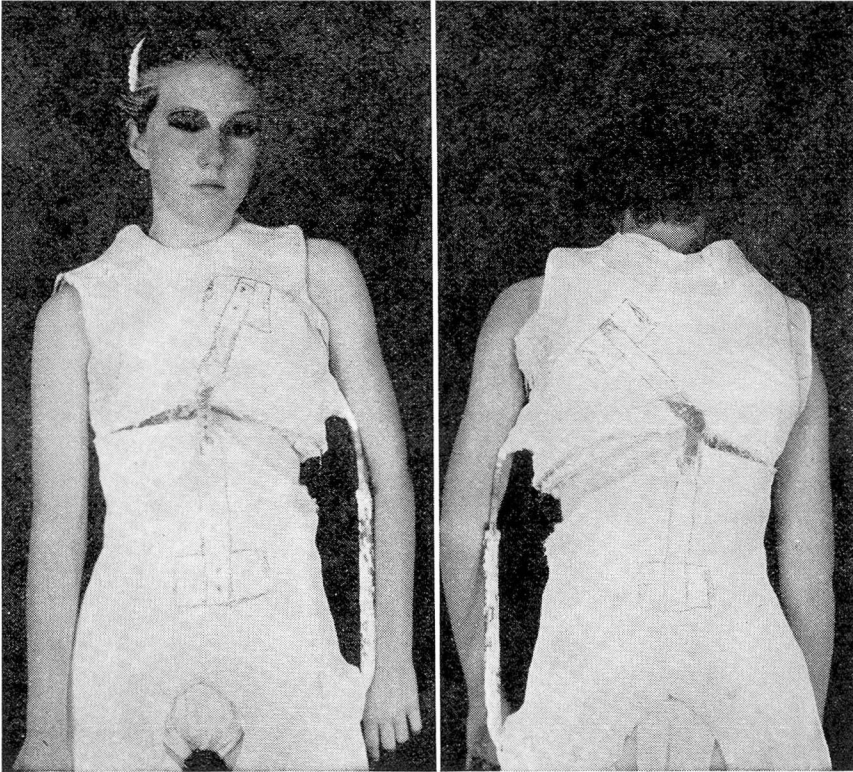


FIGURE 3: The jacket showing detail of the incorporated hinge.

jacket is thoroughly dry, it is cut horizontally at the level of the hinge. This horizontal cut also represents the apex of the curve to be corrected. A keyhole saw makes this cutting easy. The screws are then removed from the sliding collar of the hinge and distraction is effected by advancing the turnbuckle. When a two inch interval has been gained between the segments of the jacket, the screws are reapplied and the collar is locked so that the force of the advancing turnbuckle is transmitted to the hinge, and lateral flexion results. The collar is intermittently locked and unlocked until a considerable degree of correction and lateral flexion has been gained. When this considerable degree of lateral flexion has been approached, it may be necessary to cut away sections of the plaster on the side opposite the turnbuckle so that further lateral flexion can be obtained. Areas of pressure must be watched for and, if discovered early, they can be aborted by releasing the corrective force.

I shall not discuss the maintenance of correction but, in these severe cases, the structural changes in the soft tissues and in the



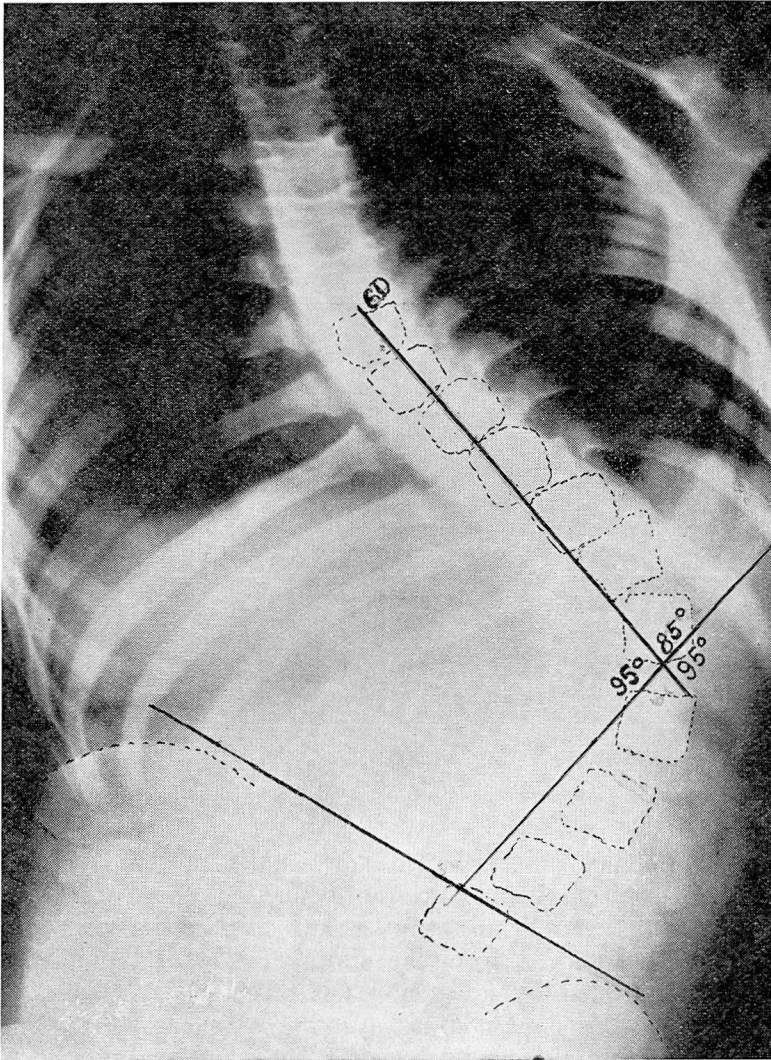


FIGURE 4: Roentgenogram before correction.

bones necessitate quite a rigid and accurately applied support. Long spinal grafts have been found to hold the correction well and in several of these cases fusion has been done through a window cut in the corrective jacket.

The patient whose roentgenograms are shown in figures 4 and 5 was an eleven year old boy whose scoliosis had developed slowly over a period of 7 years after an attack of poliomyelitis. The spine was fairly flexible and this flexibility was further increased by a period of mobilizing exercises. The weight-bearing picture (Fig. 4)



## THE CORRECTION OF SCOLIOSIS

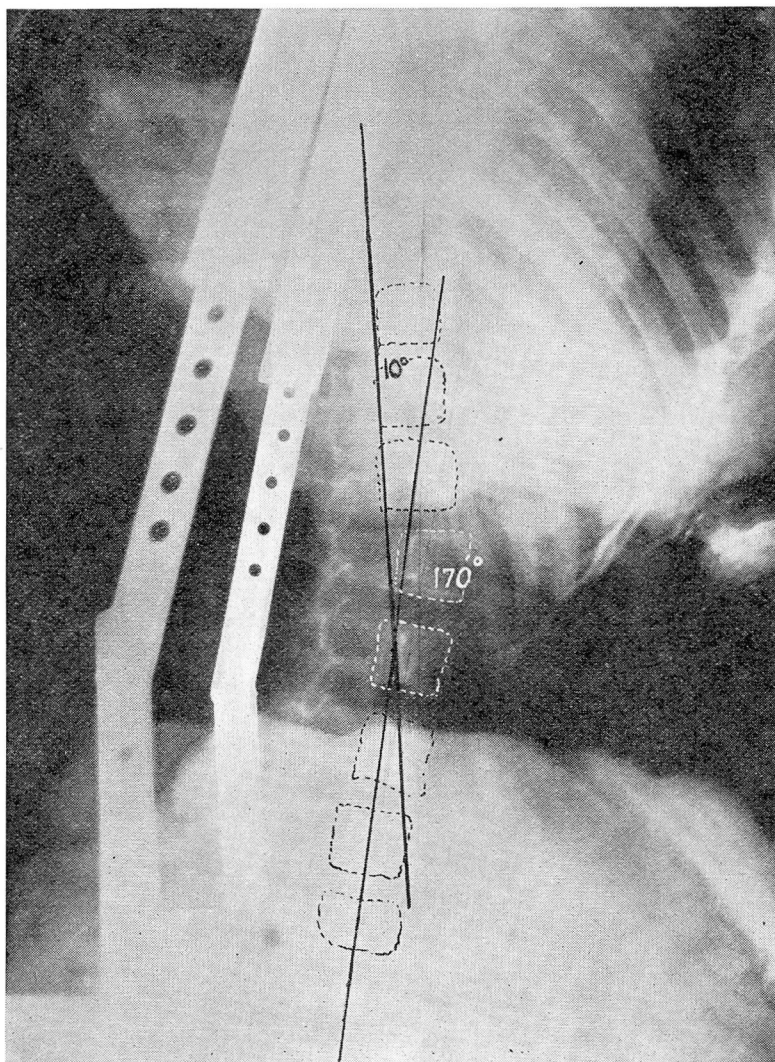


FIGURE 5: Roentgenogram after correction.

shows a dorsolumbar curve of almost 90 degrees with marked pelvic obliquity and the chest margin approximating the iliac crest. The roentgenogram (Fig. 5) showing the correction in the turnbuckle jacket was taken 8 weeks after the jacket had been applied. In this picture it can be seen that the pelvic obliquity has been corrected and the dorsolumbar curve reduced to 10 or 15 degrees.

Time and diligence are essential in correcting severe scoliosis. I have been surprised at the degree of correction that can be obtained, and if the corrective forces are applied slowly, rarely do the patients

complain. It is my belief that the more nearly straight one can make these curved spines before they are fixed, the more serviceable the back will be eventually. It is obvious that if the deforming curve is quite an acute one, the compensatory curves are proportionately acute in order to balance the back, and strain and discomfort will occur ultimately. The improvement in the appearance of the back after correction is always very gratifying. From these two standpoints, it is my feeling that considerable attention should be given to the correction of scoliosis.

#### REFERENCES

1. Bradford, E. H. and Brackett, E. G.: Treatment of lateral curvature by means of pressure correction. *Boston Med. & Surg. J.*, 128:463-468, 1893.
2. Lovett, R. W. and Brewster, A. H.: Correction of structural lateral curvature of the spine: *J.A.M.A.*, 82:1115-1118, (April 5) 1924.
3. Abbott, E. G.: The mechanics of a plaster corset in lateral curvature of the spine, *Am. Jour. Orthop. Surg.*, 12:30-44, 1914-1915.
4. Forbes, A. Mackenzie: The rotation treatment of scoliosis, *Am. Jour. Orthop. Surg.*, 11:75-96, 1913.
5. Galeazzi, R.: The treatment of scoliosis, *J. Bone & Joint Surg.*, 11:81-86, (January) 1929.
6. Hibbs, R. A., Risser, J. C., and Ferguson, A. B.: Scoliosis treated by fusion operation; end result study of 360 cases, *J. Bone & Joint Surg.*, 13:91-104, (January) 1931.
7. Brewster, A. H.: Lateral curvature of the spine, treatment by means of the turnbuckle jacket and turnbuckle shell, *Arch. Surg.*, 18:1427-1445, (April) 1929.
8. Garceau, G. J.: Personal communication.

Photographs of jacket and roentgenograms used through courtesy of the Texas Scottish Rite Hospital for Crippled Children, Dallas, Texas.