Cholestatic jaundice associated with primary amyloidosis

Seid Hossein Mir-Madjlessi, M.D.*
Richard G. Farmer, M.D.
Department of Gastroenterology

William A. Hawk, Jr., M.D.
Department of Pathology

Hepatic involvement in amyloidosis is common[1-3] and the clinical manifestations vary. A normal or enlarged liver and normal liver function tests are compatible with extensive hepatic infiltration by amyloid. The most sensitive tests of this condition[4] are bromsulphalein excretion and serum alkaline phosphatase. Rarely amyloidosis of the liver can present features of portal hypertension with esophageal varices[4, 5] or ascites.[6] However, the usual stigmata of chronic liver disease such as spider nevi, gynecomastia, and palmar erythema are absent.[4] Jaundice is uncommon.[4] Only 4.7% of 490 patients with hepatic amyloidosis were jaundiced; serum bilirubin generally did not exceed 5 mg/100 ml.[7] However, severe obstructive jaundice caused solely by hepatic amyloidosis presents a difficult differential diagnostic problem. Only five cases of obstructive jaundice due to amyloidosis have been reported to date.[7-11] We report an additional case of severe cholestatic jaundice caused by primary amyloidosis and discuss the pertinent diagnostic problems.

* *Fellow, Department of Gastroenterology.*

Downloaded from www.ccjm.org on August 14, 2025. For personal use only. All other uses require permission.

Case report

A 65-year-old man was referred to the Cleveland Clinic in November 1971 for evaluation. Two years before admission he had an episode of abdominal pain diagnosed as "gallbladder colic." He did well for one year, when right-sided Bell's palsy developed. A persistent elevation of serum alkaline phosphatase of twice the normal value was found at this time. Roentgenograms disclosed no evidence of Paget's disease or metastatic neoplasm. An oral cholecystogram did not show the gallbladder. In February 1971 the patient began to feel weak and nauseous and became anorectic. On hospitalization in July 1971 the left lobe of the liver was enlarged and irregular. Biochemical studies were normal except for elevated serum alkaline phosphatase, a slight decrease in serum albumin, and elevated gamma globulin. Liver biopsy was reported to show cholangiolitic hepatitis. Neither extrahepatic biliary tract obstruction nor an abdominal malignancy was found at exploratory laparotomy. Cholecystectomy and biopsies of the liver and an enlarged lymph node were performed. Operative cholangiography was not done. The pathological findings were chronic cholecystitis with cholelithiasis, reactive hyperplasia of lymph nodes, and cholangiolitic hepatitis with cirrhosis. The immediate postoperative course was uneventful. However, the serum alkaline phosphatase level continued to rise and the patient became jaundiced. In August 1971 swelling of the lower extremities, scrotum, and abdomen was noted and he was treated with diuretics. Weakness and anorexia continued and he lost 60 pounds.

On physical examination the blood pressure was 110/70 mm Hg, and pulse rate was irregular, 80 beats per minute. The patient was alert and icteric. Several spider nevi were seen on his neck and shoulders. Early Dupuytren's contracture was noted. Residual palsy of the right 7th facial nerve was present. Glossomegaly, purpura, and lymphadenopathy were not present. The lungs were clear. The heart had a normal sinus rhythm with occasional ectopic beats, an atrial gallop, and a grade 2/6 systolic ejection murmur over the aortic area. The abdomen was distended, with shifting dullness; the left lobe of the liver was enlarged, irregular, and nontender. No splenomegaly or abdominal bruit was detected. There was edema of the abdominal wall, scrotum, and lower extremities.

Laboratory data included: hemoglobin, 11.7 g/100 ml; hematocrit reading, 35%; macrocytosis of the red blood cells with many target and burr cells, normal white blood cell count and differential count; BUN, 29 mg/100 ml; serum creatinine, 1.8 mg/100 ml; creatinine clearance, 56 ml/min; 24-hour urinary protein, 0.57 to 1.56 g; total serum bilirubin, 12 mg/100 ml with a direct-reading fraction of 5.4 mg/100 ml; alkaline phosphatase, 202 King Armstrong units; SGOT, 120 units; serum carotene, 40 μg/100 ml (normal 50–250); and serum folate, 3.4 μg/100 ml (normal 4–18). Serum protein electrophoresis showed albumin 2.5, and gamma globulin 2.7 g/100 ml with a sharp peak in the gamma fraction; IgG, 3,000 mg/100 ml; IgA, 260 mg/100 ml; and IgM 75 mg/100 ml, serum protein immunoelectrophoresis revealed IgG monogammopathy, κ-light chain type. Urine did not contain Bence Jones protein or other homogeneous paraproteins. Serum lipoprotein electrophoresis showed faint staining of β-lipoproteins and low α-lipoproteins.

Results of the following tests were normal or negative: platelet count, bleeding time, prothrombin time, coagulation time, partial thromboplastin time, fibrinogen, cholesterol, VDRL, serum cortisol, smooth muscle antibody, mitochondrial antibody, antinuclear factor, rheumatoid factor, Australia antigen, and alpha-fetoglobulin. Electrocardiogram showed old inferior and anteroseptal infarcts, first degree atrioventricular block and complete right bundle branch block. The results of x-ray examination of the upper and lower gastrointestinal tract were normal. The small

Downloaded from www.ccjm.org on August 14, 2025. For personal use only. All other uses require permission.

bowel showed slight dilatation of the bowel loops.

The liver biopsy from the previous operation was reviewed and changes suggestive of amyloidosis were observed. This diagnosis was confirmed by rectal biopsy. Bone marrow aspirations revealed some increase in plasma cells (18% in one aspirate, 6% mature and 2% atypical plasma cells in another) and some aggregation in clusters. Because of uncertainty regarding the possibility of surgically correctable obstructive jaundice and because operative cholangiography was not performed during the previous operation, a percutaneous transhepatic cholangiogram was attempted December 6, 1971, which failed to visualize the biliary tract. Exploratory laparotomy and operative cholangiography showed once again the patency of the extrahepatic biliary tract and absence of abdominal malignancy. The postoperative course was complicated by increasing renal failure, persistent hypotension resistant to volume expansion and corticosteroids, deepening jaundice, lethargy, coma, and cardiac arrhythmia. Blood pressure had to be maintained with norepinephrine and phentolamine. The patient died December 18, 1971.

At autopsy the liver weighed 2,275 g. It was green and finely nodular. The spleen weighed 1,300 g and the peritoneal cavity contained 3,800 cc of straw-colored fluid.

Microscopic examination of the liver revealed marked alteration of the normal hepatic architecture (*Figs. 1 and 2*). There was cross-linkage of portal areas by broad bands of pink, hyaline material which stained positively for amyloid. Immediately adjoining parenchyma was compressed and encroached upon by extensions of amyloid material into the space of Disse. An overall nodular appearance was imparted by this somewhat unusual pattern of amyloid deposition. Many of the nodules contained central veins. Bile stasis with bile lake formation was noted in various portions of the nodules, both centrally and peripherally. The amyloid deposits

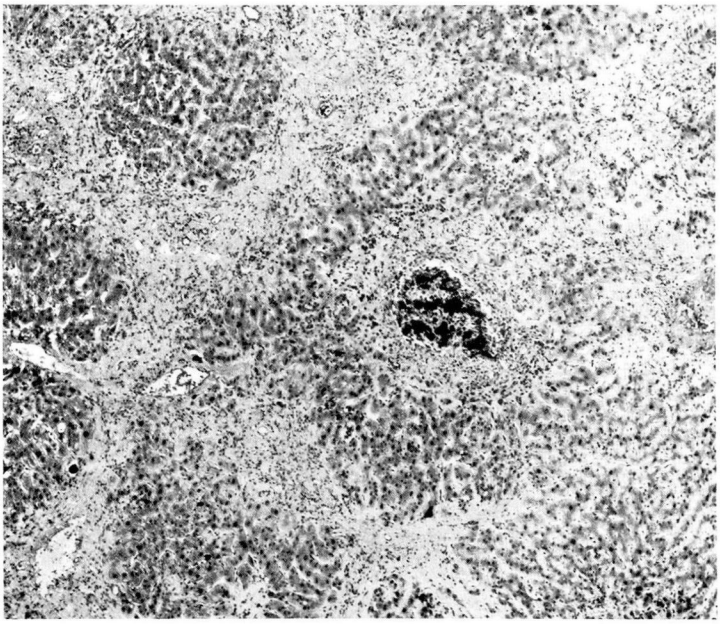

Fig. 1. Photomicrograph of liver shows bands of amyloid material linking portal areas, creating a pseudocirrhotic appearance. A large bile plug is present in one portal area. Amyloid is also present in many spaces of Disse (hematoxylin-eosin, ×40).

Downloaded from www.ccjm.org on August 14, 2025. For personal use only. All other uses require permission.

appeared greatest in the portal areas and periphery of the lobules and to a lesser extent in the space of Disse and central areas. Bile ducts appeared to be increased in number and compressed. The overall morphologic findings suggested biliary cirrhosis. However, the cirrhotic appearance was due to amyloid deposition rather than to the presence of regenerative nodules. Electron microscopy confirmed the presence of amyloid fibrils in the space of Disse, pressure atrophy of the hepatic cells, and evidence of cholestasis. Only few canaliculi showed dilatation and loss of microvilli, the remainder being normal in appearance (*Figs. 3 and 4*). Results of im-

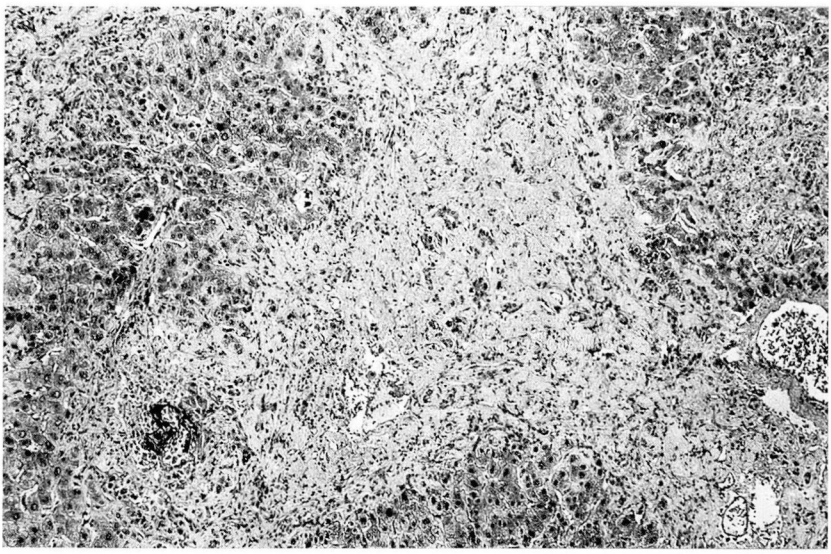

Fig. 2. Photomicrograph of liver shows the presence of bile stasis involving both bile canaliculi and a bile duct in the portal area. A large vascular channel in a portal area is involved by amyloid (hematoxylin-eosin, ×65).

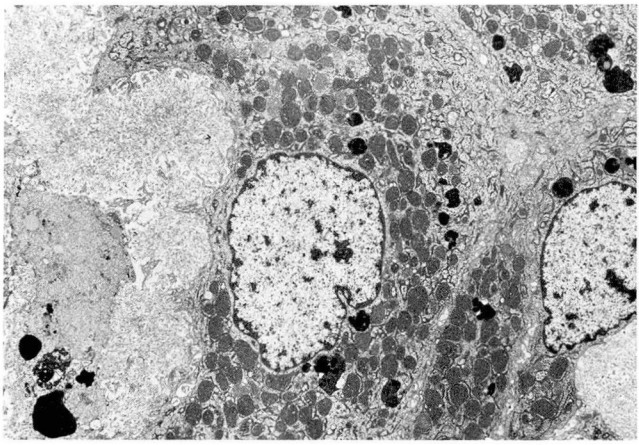

Fig. 3. An electron photomicrograph demonstrates the presence of typical amyloid fibrids in the space of Disse with resultant compression of hepatic cells (×3000).

Downloaded from www.ccjm.org on August 14, 2025. For personal use only. All other uses require permission.

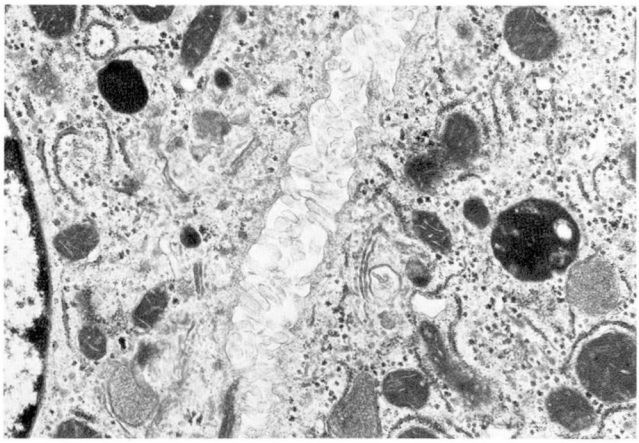

Fig. 4. A bile canaliculus has been cut longitudinally and shows essentially normal features, including preservation of microvilli (×11,800).

munofluorescent study of the liver were negative, while study of the bone marrow revealed scattered cells containing IgG, κ-type. The remainder of the autopsy findings showed widespread primary amyloidosis involving the heart (725 g), spleen, lymph nodes, adrenal glands, gastrointestinal tract, bladder, thyroid gland, and bone marrow.

Discussion

The diagnosis of primary amyloidosis in this patient was substantiated by failure to find any predisposing cause of amyloidosis at autopsy. The clinical course initially was nonspecific, and a persistently elevated serum alkaline phosphatase in the absence of bone disease was the only abnormality suggesting a disorder of the hepatobiliary tract. Whether the initial facial nerve palsy was due to amyloid neuropathy is not certain. With the past history of "gallbladder colic," failure to visualize gallbladder at cholecystography and the finding of "cholangiolitis hepatitis" at the biopsy, a partial common bile duct obstruction was suspected, and he was operated on. It was unfortunate that despite the presence of stones in the gallbladder a cholangiogram was not done during the operation. Persistent elevation of serum alkaline phosphatase and the appearance of jaundice after surgery made us reluctant to accept the amyloidosis as the sole cause of obstructive jaundice. Rectal biopsy confirmed the diagnosis of amyloidosis after we reviewed the initial liver biopsy slides.[12] The jaundice was caused solely by hepatic amyloidosis. The patient did not survive the stress of anesthesia and surgery and died in renal and hepatic failure.

Several aspects of the clinical course of this patient are similar to those of the other five reported cases[7-11] (*Tables 1 and 2*). All were men between 44 and 65 years of age; loss of weight and abdominal pain were common. Pruritus, not a prominent feature in our patient, was present in others. Hepatomegaly and ascites were present in four of five patients. Ascites is unusual in secondary amyloidosis but is found in one fifth of cases of primary amyloidosis.[6] Clinically palpable splenomegaly was rare; however, en-

Downloaded from www.ccjm.org on August 14, 2025. For personal use only. All other uses require permission.

Table 1.—Clinical findings in six cases of cholestatic jaundice caused by primary amyloidosis

	Case					
	1[8]	2[9]	3[10]	4[11]	5[7]	Present case
Age	44	44	46	62	57	65
Sex	M	M	M	M	M	M
Abdominal pain	+	+	+	...	+	−
Weight loss	...	+	+	+	+	+
Pruritus	−	+	+	+	+	−
Gastrointestinal bleeding	−	+	+	−	+	−
Hepatomegaly	+	+	+	+	+	+
Splenomegaly	−	+	−	−	−	−
Ascites	+	+	−	+	+	+
Duration of jaundice	3 wk	7½ mo	2 yr	3 mo	3 mo	5 mo
Laparotomy	Yes	Yes	No	Yes	No	Yes
Survival from the time of diagnosis	*	*	*	7 mo	8 mo	1 mo
Cause of death	Renal, adrenal, and hepatic failure	Not specified	Not specified	Renal failure	Renal failure	Renal and hepatic failure

* Diagnosis made at autopsy.

Downloaded from www.ccjm.org on August 14, 2025. For personal use only. All other uses require permission.

Table 2.—Laboratory data of six cases of cholestatic jaundice caused by primary amyloidosis

	Case					
	1[8]	2[9]	3[10]	4[11]	5[7]	Present case
Bilirubin, mg/100 ml	9.4	16.3	35	15.6	40	12
Alkaline phosphatase, units	—	36.6 BU	220 KA	414 KA	22.4 BL	202 KA
Serum cholesterol, total mg/100 ml	—	512	417	847	480	235
SGOT, units	—	—	—	—	27	120
Gammopathy	—	—	—	None present	IgG	IgG
Liver weight, g	3,178	5,900	5,540	2,200	3,100	2,275
Spleen weight, g	500	1,200	1,000	—	405	1,300

BU = Bodansky units, KA = King Armstrong units, BL = Bessy-Lowry units, — = not performed.

Downloaded from www.cjm.org on August 14, 2025. For personal use only. All other uses require permission.

larged spleen was present at autopsy in all cases.

Heart and kidneys were involved in all. In our patient a pattern of complete right bundle branch block and first degree atrioventricular block developed within a few months. He also showed a pattern of inferior wall and anteroseptal myocardial infarction, although he had no past history of angina pectoris and myocardial infarction. Various arrhythmias and electrocardiographic manifestations of myocardial infarction are frequently encountered in amyloid heart disease.[4, 13] In our patient renal function was relatively well preserved initially and failed suddenly only after operation. Despite some proteinuria, typical nephrotic syndrome was absent and no Bence Jones protein was found.

Gastrointestinal bleeding, absent in our patient, may be present. Low serum carotene and folate levels and red cell macrocytosis would indicate a certain degree of malabsorption, sometimes seen in amyloidosis.[13, 14] Serum alkaline phosphatase, bilirubin, and cholesterol were elevated in all. In our patient, however, serum cholesterol remained within normal limits, and SGOT was only slightly elevated.

Monoclonal gammopathy and plasma cell hyperplasia are frequently found in primary amyloidosis.[4, 11] Barth et al[11] described anomalous urinary or serum immunoglobulins in 9 of 15 patients with primary amyloidosis. Five had gammopathies of IgG, IgA, or IgM variety. One patient with hepatomegaly had IgA gammopathy. However, their patient with cholestatic jaundice did not show any abnormal immunoglobulin. Levy et al[7] described a case of obstructive jaundice caused by primary amyloidosis with paraprotein of the IgG type. In our patient, the abnormal immunoglobulin was of IgG type with κ-light chain. It is pertinent to note that while immunofluorescence of the liver was negative, that of bone marrow revealed cells, presumably plasma cells, containing IgG with κ-light chain. This finding would suggest once again a lack of relationship between amyloid and immunoglobulins, as stressed by other authors.[4, 11] However, recent observations suggest that the immunoglobulins may be involved in the formation of amyloid.[15] It should be pointed out that monoclonal gammopathy and plasma cell hyperplasia have been seen in association with chronic hepatobiliary disease.[16, 17] The role of chronic cholecystitis in our patient is not clear. Finally, this abnormal protein did not possess antibody-like activity similar to those commonly associated with chronic liver disease. Wager et al[18] reported anti-smooth muscle and anti-thyroglobulin-like activity in certain abnormal immunoglobulins. In our patient tests for antinuclear factor, smooth muscle antibody, mitochondrial antibody, rheumatoid factor as well as alpha-fetoglobulin were negative.

The prognosis of cholestatic jaundice associated with primary amyloidosis remains grave. All patients have died within a year of diagnosis.

Summary

We report a case of primary amyloidosis causing cholestatic jaundice. This appears to be the sixth case reported. The clinical and biochemical manifestations of this entity are reviewed. Two patients, including this case, had IgG monoclonal gammopathy. The poor prognosis and rapidly

Downloaded from www.ccjm.org on August 14, 2025. For personal use only. All other uses require permission.

progressive clinical course are demonstrated by this case.

References

1. Levine RA: Amyloid disease of the liver. Correlation of clinical, functional, and morphologic features in forty seven patients. Am J Med **33:** 349–357, 1962.
2. Kleckner MS Jr, Magidson J: Amyloidosis of the liver. Correlation of clinical and pathologic features. Gastroenterology **29:** 56–63, 1955.
3. Rukavina JC, Block WD, Jackson CE, et al: Primary systemic amyloidosis: review and an experimental, genetic and clinical study of 29 cases with particular emphasis on the familial form. Medicine **35:** 239–334, 1956.
4. Cohen AS: Amyloidosis (concluded). N Engl J Med **277:** 628–638, 1967.
5. Kapp JP: Hepatic amyloidosis with portal hypertension. JAMA **191:** 497–499, 1965.
6. Gregg JA, Herskovic T, Bartholomew LG: Ascites in systemic amyloidosis. Arch Intern Med **116:** 605–610, 1965.
7. Levy M, Fryd CH, Eliakim M: Intrahepatic obstructive jaundice due to amyloidosis of the liver. Gastroenterology **61:** 234–238, 1971.
8. Bannick EG, Berkman JM, Beaver DC: Diffuse amyloidosis; three unusual cases: a clinical and pathologic study. Arch Intern Med **51:** 978–990, 1933.
9. Orloff J, Felder L: Primary systemic amyloidosis; jaundice as a rare accompaniment. Am J Med Sci **212:** 275–279, 1946.
10. Atkinson AJ: Clinical pathological conference. Gastroenterology **7:** 477–482, 1946.
11. Barth WF, Willerson JT, Waldman TA, et al: Primary amyloidosis. Clinical, immunochemical and immunoglobulin metabolism studies in fifteen patients. Am J Med **47:** 259–273, 1969.
12. Blum A, Sohar E: Diagnosis of amyloidosis. Ancillary procedures. Lancet **1:** 721–723, 1962.
13. Brandt K, Cathcart ES, Cohen AS: A clinical analysis of the course and prognosis of forty two patients with amyloidosis. Am J Med **44:** 955–969, 1968.
14. Herskovic T, Bartholomew LG, Green PA: Amyloidosis and malabsorption syndrome. Arch Intern Med **114:** 629–633, 1964.
15. Glenner GG, Ein D, Terry WD: The immunoglobulin origin of amyloid. Am J Med **52:** 141–147, 1972.
16. Zawadzki ZA, Edwards GA: Dysimmunoglobulinemia associated with hepatobiliary disorders. Am J Med **48:** 196–202, 1970.
17. Osserman EF, Fahey JL: Plasma cell dyscrasia; current clinical and biochemical concepts. Am J Med **44:** 256–269, 1968.
18. Wager O, Räsänen JA, Haltia K, et al: M components with antibody activity. Anti-smooth muscle, anti-thyroglobulin and anti-streptolysin-O activity in five M component sera. Ann Clin Res **3:** 86–97, 1971.

Downloaded from www.ccjm.org on August 14, 2025. For personal use only. All other uses require permission.