

Ventricular fibrillation and coronary atherosclerosis with normal maximal exercise test

Report of a case

Lon W. Castle, M.D.

Wayne Siegel, M.D.

William L. Proudfit, M.D.

Department of Clinical Cardiology

Frederick A. Heupler, M.D.

Department of Cardiovascular Disease and Cardiac Laboratory

Ventricular arrhythmias may cause sudden death in patients with coronary artery disease. A method of recognizing patients in whom this complication is likely to develop during periods of stress is desirable. Graded maximal exercise tolerance testing has been used for this purpose. Victims of this catastrophe rarely survive for diagnostic evaluation and therapeutic correction of the responsible cardiac lesions.¹⁻³

We have recently studied the case of a patient in whom the initial manifestation of coronary artery disease was ventricular fibrillation during a strenuous tennis match. This patient did not experience symptoms of cardiac disease before cardiac arrhythmia, and he had a normal graded maximal exercise tolerance test during his diagnostic evaluation. Selective cine coronary arteriography was necessary for definitive diagnosis.

Case report

On July 9, 1971, a 50-year-old man collapsed while playing tennis. His tennis partner, a physician, began cardiopulmonary resuscitation and was assisted by a nurse who was nearby. On admission to the emergency room at a local hospital, an electrocardiogram showed ventricular fibrillation. Normal sinus rhythm was established by external electrical cardioversion. He re-

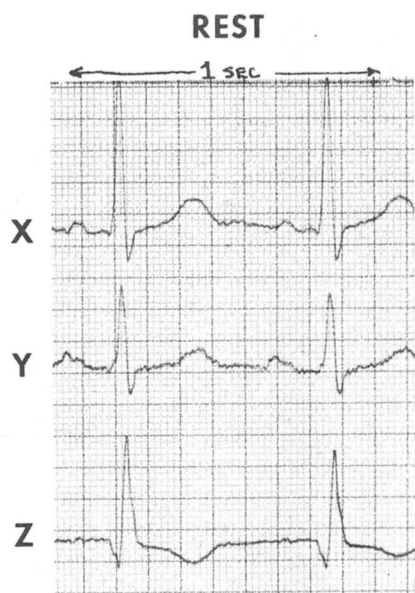


Fig. 1. Normal resting electrocardiogram.

maintained in the hospital until July 20, 1971. Serial electrocardiograms showed no evidence of acute myocardial infarction. Non-specific S-T and T wave changes had reverted to normal at the time of discharge. Serum glutamic oxaloacetic transaminase (SGOT) and lactic dehydrogenase (LDH) values were elevated to 95 units/ml and 2,000 milliunits/ml (IU) respectively. The day after admission the patient complained of mild chest pain, which was attributed to external cardiac massage and electrical cardioversion.

He was referred to the Cleveland Clinic for cardiac evaluation on August 7, 1971. It was noted in his history that a dropperful of 1% phenylephrine hydrochloride nasal drops was inserted in each nostril for nasal obstruction just before the tennis match. Approximately one year before while playing tennis, he had to stop because of fatigue and vague anterior chest discomfort. He had experienced high sub-sternal chest discomfort during periods of emotional stress, when carrying heavy objects, and shovelling snow.

The past medical history was unremark-

able. No history of heart murmurs, diabetes, or hypertension was obtained. The only medication was an occasional antihistamine tablet. He had no known drug allergies. He smoked one-half pack of cigarettes per day for over 25 years but stopped 1½ years previously.

Physical examination showed no significant abnormalities except for a fourth heart sound at the apex, with the patient in the left lateral decubital position during isometric hand exercise. The blood pressure was 150/90 mm Hg. Routine laboratory studies, serum cholesterol, serum triglycerides, resting electrocardiogram, and roentgenograms of the chest were normal.

On August 16, 1971, he underwent a graded maximal exercise test in the Cardiac Function Laboratory, using a bicycle ergometer for stress induction. He was monitored using the Frank lead electrocardiogram. The resting electrocardiogram was normal with a pulse rate of 95 beats per minute (*Fig. 1*), and blood pressure was 150/100 mm Hg. After a 1-minute warmup period, he performed 5 minutes of 400 kpm work with a pulse rate of 145 beats per minute. After 3 minutes of rest he performed an additional 5 minutes of 1,000 kpm work with a pulse response of 192 beats per minute, and a blood pressure of 200/100 mm Hg. He stopped because of leg fatigue. He denied having chest pain. No abnormalities were encountered on the electrocardiograms (*Fig. 2*).

On August 18, 1971, selective cine coronary arteriography was performed (Sones technique). The angiograms demonstrated an 80% obstruction in the proximal anterior descending coronary artery distal to the first diagonal branch and proximal to the first septal perforator (*Fig. 3*). The dominant right coronary artery and left circumflex were normal. The size, contour, and contractions of the left ventricle were normal. The end diastolic pressure was 7 mm Hg.

On August 20, 1971, a saphenous vein

graft bypass from the aorta to the left anterior descending artery was performed. The postoperative course was uneventful. As of January 1972 the patient was asymptomatic.

Discussion

In 1968 Bruce et al⁴ reported the case of a 42-year-old man with ventricular tachycardia after exercise, normal maximal exercise test, and angiographic evidence of coronary atherosclerosis. The patient had experienced an acute myocardial infarction. Coronary arteriograms performed 6 months post-infarction showed a 90% obstruction in the proximal segment of the left circumflex.

Arrhythmia deaths often occur when facilities for emergency assistance are not available. Exercise testing is a widely used technique for identifying patients with latent cardiac disease, including arrhythmias from a variety of causes. Unfortunately, there is a high incidence of false negative results using the "double Masters" technique.⁵ Maximal exercise stress tests with special electrocardiographic lead systems reduce false negative responses, but are not completely reliable.⁶ Our patient experienced a "positive" response to heavy muscular exercise during a tennis match, which could not be duplicated during maximal stress testing. The implications for screening individuals who participate in strenuous sports activity are apparent. It would seem that selective coronary arteriography is the only definitive diagnostic method for recognizing the presence of coronary artery disease.

The sensitivity and reliability of maximal exercise tests to induce cardiac arrhythmias has not been carefully studied. Failure to precipitate

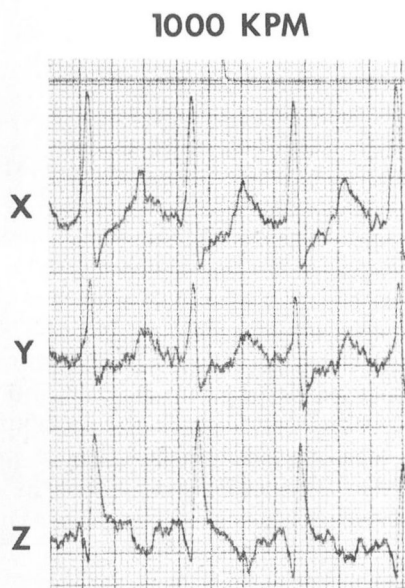


Fig. 2. Exercise electrocardiogram 1,000 kpm shows normal S-T-T vectors in the Frank leads.

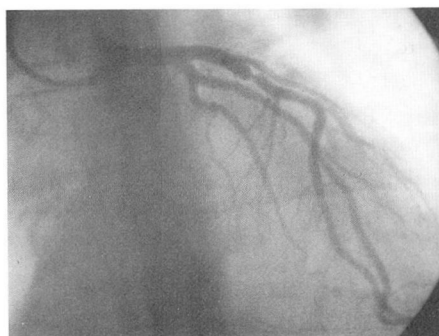


Fig. 3. Coronary arteriogram shows an 80% stenotic lesion in the anterior descending branch of the left coronary artery.

life-threatening arrhythmias in this patient suggests that such an analysis has less than optimal sensitivity and reliability for detection of exercise-induced arrhythmia.

The use of alpha adrenergic stimulants by nasal instillation for chronic nasal obstruction is a relatively com-

mon practice. Patients with cardiovascular disease should avoid using vasopressor drugs especially before strenuous physical activity.

Summary

An unusual case of a patient with a history of ventricular fibrillation during strenuous physical activity and after the use of a vasopressor drug is reported. A graded maximal exercise test was normal. The patient had significant obstructive coronary disease. The absence of symptoms and abnormal electrocardiographic responses during maximal exercise do not preclude significant cardiac disease in individuals who participate in strenuous sports.

References

1. Paul O: Myocardial infarction and sudden death. *Hosp Pract* 6: 91-103, 1971.
2. Lown B, Wolf M: Approaches to sudden death from coronary heart disease. *Circulation* 44: 130-142, 1971.
3. Robb GP, Marks HH: Latent coronary artery disease: determination of its presence and severity by the exercise electrocardiogram. *Am J Cardiol* 13: 603-618, 1964.
4. Bruce RA, Hornsten TR, Blackmon JR: Myocardial infarction after normal responses to maximal exercise. *Circulation* 38: 552-558, 1968.
5. Fitzgibbon GM, Burggraf GW, Groves TD, et al: A double Master's two-step test: clinical, angiographic and hemodynamic correlations. *Ann Intern Med* 74: 509-517, 1971.
6. McDonough JR, Bruce RA: Maximal exercise testing in assessing cardiovascular function. *J S Carolina Med Assoc* 65: Suppl. I: 25-33, 1969.