

Traumatic disruption of the aortic valve

FLOYD D. LOOP, M.D.

GERHARD HOFMEIER, M.D.*

LAURENCE K. GROVES, M.D.

Department of Thoracic and Cardiovascular Surgery

AORTIC insufficiency is a rare but well-defined consequence of non-penetrating chest trauma. The injury may occur as an isolated incident, and occasionally is induced through straining or relatively minor degrees of concussion. Unlike disruption of the thoracic aorta, which is associated with a high, early mortality, the torn aortic valve frequently permits a longer period of survival. Effective treatment during this time interval was not forthcoming, however, until the advent of cardiopulmonary bypass and the development of valvular prostheses.

During the past decade, traumatic aortic valve incompetence has received attention repeatedly, particularly after vehicular accidents. Our experience with a case of aortic leaflet injury is presented and compared with recent reports in the world literature.

Report of a case

A 19-year-old white male factory worker was driving at high speed when his car struck a utility pole. The steering wheel struck the midportion of his sternum. He was taken to a nearby hospital and found to have a compound comminuted fracture of the right patella and an avulsion fracture of the inferior pole of the left patella. No cardiac murmur was detected during this initial examination. During the second day of hospitalization, he had shortness of breath and chest pain. Auscultation then revealed a high-pitched, loud, diastolic murmur at the cardiac base. Dyspnea increased that day and became associated with a cough that produced yellowish-pink sputum. A diuretic and digitalis were administered and he was transferred to the Cleveland Clinic Hospital.

Physical examination. The patient was sitting upright and obviously uncomfortable from dyspnea and coughing. The blood pressure was 120/50 mm Hg, the pulse 120 and regular, and the temperature was 99F. Neck veins were not distended but rales and rhonchi were audible over both lower lung fields. A high-pitched grade IV/VI diastolic murmur was heard over the entire precordium and a third heart sound was detected at the apex. The arterial pulsations were water-hammer in type. Except for the previously described orthopedic injuries, no other pertinent findings were noted. The electrocardiogram showed sinus tachycardia. Chest roentgenography outlined a fine alveolar infiltrate throughout both lung fields which suggested pulmonary edema (*Fig. 1*). Aortography and left heart catheterization were immediately performed. Free aortic regurgitation was demonstrated through the region of the left coronary cusp (*Fig. 2*). The left ventricle was mildly dilated but contracted well. The thoracic aorta appeared normal throughout its course. While the cine studies were in progress, preparations were made for emergency open-heart surgery.

Operation. The heart and aorta showed no evidence of trauma. Using normothermic, cardiopulmonary perfusion, the valve was inspected through the aortic root. A "bucket-

*Present address: 665 Homburg-Saar, Eichheckstrasse 26, West Germany.

handle" tear separated the left coronary (posterior) cusp from the aortic wall. The free margin of the cusp was intact, but the leaflet prolapsed downward into the sinus where it was held by filmy granulation tissue (*Fig. 3*). An attempt to reconstruct the fragile tissue failed, and the valve was replaced by an A-5 Smeloff-Cutter ball valve prosthesis.

Postoperative course. A smooth convalescence ensued after surgery and oral administration of anticoagulants was begun on the third postoperative day. Fifteen days later, anticoagulant therapy was interrupted when the fractured right patella was wired. Twenty-three days after admission, the patient was discharged from the hospital. A roentgenogram of the chest, two months postoperatively, revealed a normal heart size and clear lung fields (*Fig. 4*). The follow-up period has extended more than 18 months since the emergency valve replacement, and the young man is now active, feels well, and is working full time in a department store.

Comment. Although the patient sustained multiple injuries as a result of the automobile accident, his previously normal cardiovascular status tolerated the valve insult long enough for confirmatory diagnostic studies to be made. From the small size of the valve prosthesis, it was evident that we were dealing with a small aortic annulus. In this situation, the fragile, diminutive cusp is extremely difficult to reattach without producing some asymmetry in the line of closure. Gross and microscopic examination of the excised tissue did not demonstrate any congenital or acquired abnormality, and we believe the insufficiency was caused strictly by the blow to the sternum.

Discussion

Since Plenderleath's¹ description of traumatic aortic valve rupture in 1830, more than 130 cases have been reported. Almost a century later, Howard²

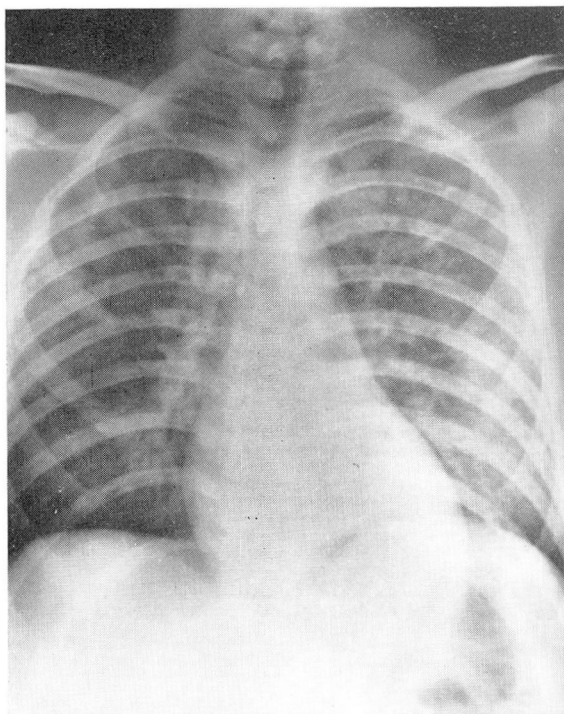


Fig. 1. Admission roentgenogram of the chest showing acute pulmonary congestion secondary to massive aortic regurgitation.

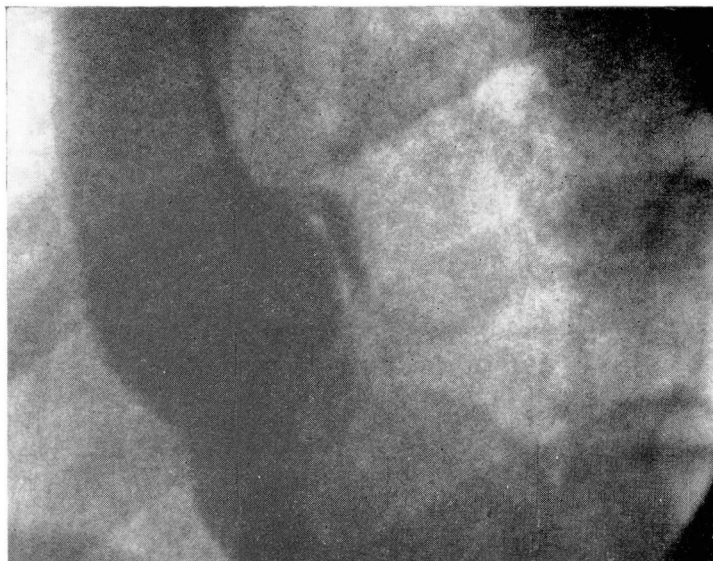


Fig. 2. Frame from cine aortogram confirms evidence of insufficiency through area of left coronary cusp.

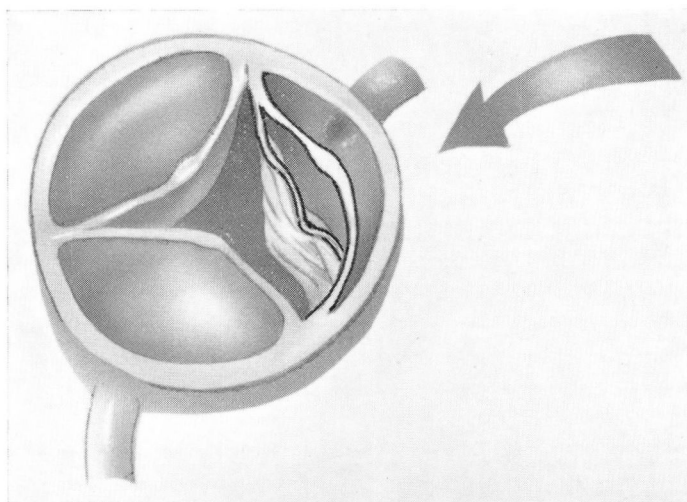


Fig. 3. Drawing of the opened aortic root. The torn left coronary cusp is prolapsed inferiorly.

wrote the classic, comprehensive review of 113 cases. He acknowledged that the common etiologies were both muscular effort and chest compression. In the case reports corroborated by autopsy, only a small minority of patients were found to have had preexisting valvular heart disease.

During the next 25 years, few papers³⁻⁶ were published, probably because

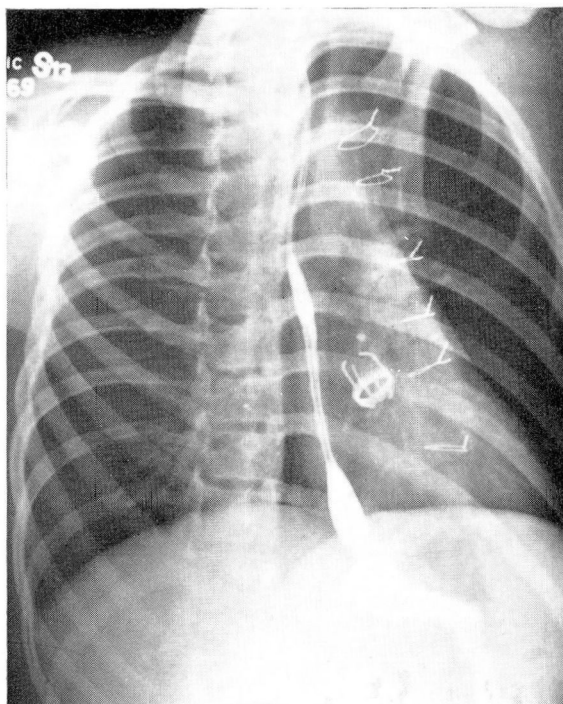


Fig. 4. Right anterior oblique roentgenogram demonstrating valve prosthesis and normal cardiac configuration, eight weeks after surgery.

no substantial treatment could be offered. In their extensive series on non-penetrating cardiac injury, Parmley, Manion, and Mattingly,⁷ stated that the atrioventricular valves were actually most often damaged, but this form of valve injury also is frequently associated with myocardial rupture; thus leaving the aortic valve lesion more commonly seen clinically.

In 1955, Leonard, Harvey, and Hufnagel⁸ first reported the surgical treatment when Hufnagel inserted a plastic valve into the descending aorta. Aortic regurgitation was compensated by this maneuver, and 14 months later the patient was reported to be in good health. Beginning with this surgical achievement, 15 more cases of traumatic aortic incompetence have been documented to 1970 (*Table I**). Most of these patients were injured in automobile accidents and sustained forceful but nonpenetrating chest injuries. Exceptions were the first patient of Najafi and associates⁹ and Spurny and Hara's¹⁰ patient, in each of whom the valve leak developed after straining. Of the 13 patients in whom the site of insufficiency was determined, the left coronary or noncoronary leaflet was most commonly

**All categories related to nonpenetrating aortic valve rupture were rechecked through MEDLARS (Medical Literature Analysis and Retrieval System). No other reports were available.*

Table 1.—Case reports of traumatic aortic insufficiency published since 1955

Author	Patient		Etiology	Year reported	Site of rupture*	Method of treatment	Outcome
	Age	Sex					
Leonard et al. ⁸	19	M	Kicked by horse	1955	Not determined	Hufnagel valve in descending aorta	14 mo. follow-up; working full time
Proudfit and McCormack ¹⁷	56	M	Automobile accident	1956	Left coronary cusp torn at left point of attachment, 4-mm fenestration in right (anterior) cusp	Medical management	Died 3 yr, 3 mo after accident
Dimond et al. ¹¹	32	M	Several episodes of blunt trauma over 4-yr period	1957	Transverse tear in aorta 3 cm above valve with fenestrations in left and noncoronary cusps	Hufnagel valve in descending aorta	Valve thrombosed leading to progressive failure and death 4 mo. later
Ramage and Morgan ¹⁹	34	M	Heavy iron gutter fell on chest	1957	Anterior (right) cusp torn. Numerous calcific vegetations	Medical management	Died of congestive failure 7-yr. after accident
Spurny and Hara ¹⁰	62	M	Lifting block of ice	1959	6-mm rent in left coronary cusp, 1.5 mm from annulus	Tear sutured	Died in operating room
Dauphin and Dauphin ²⁰	62	M	Automobile accident	1962	Tear in noncoronary cusp	Medical management	Died 4 yr. after accident
Levine et al. ¹²	35	M	500-lb box fell on chest	1962	Left coronary cusp avulsed from commissure	Leaflet reattached	Died in operating room
Duborg et al. ¹³	56	M	Jumped from bridge	1963	Noncoronary cusp detached	Leaflet reattached	Alive and in good health 9 yr later
Beall and Shirkey ¹⁵	39	F	Automobile accident	1964	Prolapse of left and noncoronary cusps caused by detached commissure	Commissure sutured in 1961	Murmur soon returned followed by progressive decompensation over next 20 mo.
Gregersen and Nielsen ²¹	48	M	Bicycle hit by car	1965	Fenestration left coronary cusp	Replaced by No. 11 Starr-Edwards valve in 1964	4 mo. postoperative, asymptomatic and heart size smaller
Mitt et al. ²²	65	M	Automobile accident	1966	Left coronary cusp detached	Medical management	Died in 18 hr.
Muller and Muller ²³	40	M	Automobile accident	1967	Aortic insufficiency confirmed by cardiac catheterization but specific site not verified	Medical management	Died in 1 mo.
Najafi et al. ⁹	62	M	Automobile accident	1967	Perforation of right cusp and detachment of two posterior commissures	Replaced by No. 12 Starr-Edwards ball valve prosthesis	No follow-up
Najafi et al. ⁹	53	M	Shoveling snow	1967	50% detachment of right coronary cusp from annulus and perforation of other two cusps	Replaced by No. 12 Starr-Edwards ball valve prosthesis	1 yr. follow-up; heart size normal
Loop et al.	19	M	Automobile accident	1971	Left coronary cusp torn	Replaced by No. 3 Smeiloff-Cutter ball valve prosthesis	9 mo. postoperative; asymptomatic; heart size, upper normal limits

* Terminology relating to the involved leaflet is not standardized. We call the anterior cusp the right coronary cusp, the left posterior the left coronary cusp, and the right posterior the noncoronary cusp.

perforated or detached. Only one patient had known cardiovascular disease, which possibly weakened the valve consistency.¹¹

Of these 15 patients six were treated medically and five died. Before open-heart surgery, two patients received Hufnagel valves placed in the descending aorta. Thrombosis in the valve eventually caused the death of one patient.¹¹

The first two attempts to reconstruct a torn cusp ended unsuccessfully in the operating room because of technical problems rather than persistent aortic insufficiency.^{10, 12} The fact that no satisfactory prosthesis was yet available compelled Dubourg and associates¹³ to suture a lacerated noncoronary cusp in 1961. The patient is reported to be alive and symptom-free nine years later.¹⁴ When the ball valve finally became a practical replacement, Beall and Shirkey¹⁵ first inserted the prosthesis in the subcoronary position. They had repaired a torn aortic commissure in the same woman three years earlier, but the insufficiency returned necessitating valve substitution.

Management of associated injuries may divert attention from the damaged valve and the physician will not realize that a cardiac problem exists until the onset of congestive heart failure. Occasionally, acute aortic insufficiency produces a tearing sensation or a buzzing noise in the chest, but the detection of a loud aortic diastolic murmur in a heart previously known to be normal establishes the diagnosis. The high musical pitch¹⁶ of this murmur has intrigued cardiologists for decades, probably because it has a pure quality rather than a mixture of tones or a noise.¹⁷ After a varying period of time, depending on the size of the leak, the diastolic pressure falls and peripheral signs of aortic insufficiency appear;¹⁸ i.e., Corrigan's pulse, Duroziez' murmur, pistol-shot sounds over the brachial and femoral vessels, and a visible capillary pulse.

The suspected diagnosis can be easily confirmed by aortography. The extent of damage will range from small single fenestrations to commissural detachments affecting two leaflets. The amount of regurgitation and the underlying cardiac status no doubt determine the length of survival. Many of these patients with traumatic aortic valve injury live only a few hours or a few days, and the lethality of the disruption must be respected.

At the time of operation, the surgeon may be tempted to reconstitute the insufficient valve, particularly if the problem is a detached commissure. However, the small size and gossamer quality of the aortic leaflets make any reconstructive effort a formidable undertaking and, to date, only one long-term survival is known. Fortunately, a number of valvular prostheses are dependable in the aortic position. First-hand experience and lessons learned from published reports on traumatic aortic valve regurgitation indicate that valve replacement is the safest course of management.

Summary

A healthy 19-year-old male sustained traumatic aortic insufficiency from a steering wheel injury. The characteristic high pitched murmur was au-

dible and cine aortography revealed a torn left coronary leaflet. The damaged aortic valve was replaced by an A-5 Smeloff-Cutter ball valve prosthesis. The patient is active and well 18 months later.

All reports of surgical treatment are reviewed. Repair of the involved leaflet or leaflets is a formidable undertaking and only one patient has survived reconstructive attempts. Reliability of the currently available prostheses for the valve indicates that valve replacement is the safest course of management.

References

1. Plenderleath, D.: Case of death from rupture of one of the semilunar valves of aorta. *London M. Gaz.* **109**: 110, 1830.
2. Howard, C. P.: Aortic insufficiency due to rupture by strain of a normal aortic valve. *Can. Med. Assoc. J.* **19**: 12-24, 1928.
3. Kissane, R. W.; Koons, R. A., and Fidler, R. S.: Traumatic rupture of normal aortic valve. *Am. Heart J.* **12**: 231-234, 1936.
4. Kissane, R. W.; Koons, R. A., and Clark, T. E.: Traumatic rupture of aortic valve. *Am. J. Med.* **4**: 606-611, 1948.
5. Bushong, B. B.: Traumatic rupture of aortic valve: report of two cases, one proved and other probable example of the condition. *Ann. Intern. Med.* **26**: 125-126, 1947.
6. Beneke, R.: Ein Fall spontaner Aortenklappenruptur mit Hämatom im Gebiet des Septum fibrosum ventr. als Begleiterscheinung einer vorzeitigen Geburt. *Ztschr. Geburtshilfe Gynäkol.* **124**: 1-28, 1942.
7. Parmley, L. F.; Manion, W. C., and Mattingly, T. W.: Nonpenetrating traumatic injury of the heart. *Circulation* **18**: 371-396, 1958.
8. Leonard, J. J.; Harvey, W. P., and Hufnagel, C. A.: Rupture of the aortic valve; therapeutic approach. *N. Engl. J. Med.* **252**: 208-212, 1955.
9. Najafi, H.; Dye, W. S.; Javid, H.; Hunter, J. A., and Julian, O. C.: Rupture of an otherwise normal aortic valve. Report of two cases and review of the literature. *J. Thorac. Cardiovasc. Surg.* **56**: 57-62, 1968.
10. Spurny, O. M., and Hara, M.: Rupture of the aortic valve due to strain. *Am. J. Cardiol.* **8**: 125-129, 1961.
11. Dimond, E. G.; Larsen, W. E.; Johnson, W. B., and Kittle, C. F.: Post-traumatic aortic insufficiency occurring in Marfan's syndrome, with attempted repair with a plastic valve. *N. Engl. J. Med.* **256**: 8-11, 1957.
12. Levine, R. J.; Roberts, W. C., and Morrow, A. G.: Traumatic aortic regurgitation. *Am. J. Cardiol.* **10**: 752-763, 1962.
13. Dubourg, G.; Fontan, F.; Trarieux, M.; Galy, J. C.; Plouquin, F.; Dallochio, M.; Bricaud, H., and Broustet, P.: Insuffisance aortique traumatique. Correction chirurgicale sous hypothermie profonde. *Arch. Mal. Coeur.* **56**: 782-790, 1963.
14. Fontan, F.: Personal communication, Nov. 1970.
15. Beall, A. C., and Shirkey, A. L.: Successful surgical correction of traumatic aortic valve regurgitation. *J.A.M.A.* **187**: 507-510, 1964.
16. Gelfand, D., and Bellet, S.: The musical murmur of aortic insufficiency: clinical manifestation; based on a study of 18 cases. *Am. J. Med. Sci.* **221**: 644-654, 1951.
17. Proudfit, W. L., and McCormack, L. J.: Rupture of the aortic valve. *Circulation* **13**: 750-753, 1956.
18. Bean, W. B., and Schmidt, M. C.: Rupture of the aortic valve: disappearing diastolic pressure as a diagnostic sign. *J.A.M.A.* **153**: 214-215, 1953.

19. Ramage, J. H., and Morgan, J. B.: Traumatic aortic incompetence. *Scot. Med. J.* **2**: 299-300, 1957.
20. Dauphin, G., and Dauphin, M.: Insuffisance aortique traumatique. *Arch. Mal. Coeur.* **58**: 525-552, 1965.
21. Gregersen, H., and Nielsen, K.: Traumatic rupture of the aortic valve. *Acta chir. Scandinav.* **129**: 669-674, 1965.
22. Miti, L.; Totti, S., and Massei, V.: A proposito di un caso di insufficienza aortica traumatica. *G. Clin. Med.* **47**: 953-963, 1966.
23. Muller, M., and Muller, P.: Ruptures traumatiques des vavules mitrale et aortique. *Ann. Méd. lég.* **47**: 183-185, 1967.